

RESEARCH ARTICLE

Vestibulo-ocular reflex in patients with amnesic mild cognitive impairment and normal controls: a comparative study

Sarah Yargholi¹, Mansoureh Adel Ghahraman^{1*}, Reza Hoseinabadi¹, Vajiheh Aghamollaii², Shohreh Jalaie³

¹ - Department of Audiology, School of Rehabilitation, Tehran University of Medical Sciences, Tehran, Iran

² - Department of Neurology, Roozbeh Hospital, Tehran University of Medical Sciences, Tehran, Iran

³ - Biostatistics, School of Rehabilitation, Tehran University of Medical Sciences, Tehran, Iran

Received: 25 Dec 2017, Revised: 25 Jan 2018, Accepted: 29 Jan 2018, Published: 15 Jul 2018

Abstract

Background and Aim: Several studies have shown the anatomical associations between the vestibular system and cognitive processes, especially spatial memory. One of the first problems that occur in Alzheimer's disease (AD) is spatial memory deficits. The preclinical stage of AD is mild cognitive impairment (MCI). Amnesic type of MCI (aMCI) is more likely to progress to AD. Previous studies have demonstrated high incidence of vestibular disorders in AD patients; however, the balance system of aMCI patients has not been investigated. Therefore, the present study aimed to investigate vestibulo-ocular reflex (VOR) impairments in aMCI patients compared with control group.

Methods: In this cross-sectional study VOR gain and catch-up saccades in six semicircular canals were measured in 12 aMCI patients and 12 normal controls using video head impulse test.

Results: Vestibulo-ocular reflex gains in direction of all vertical semicircular canals were lower in aMCI- compared with normal-group (right anterior canal 0.74 ± 0.17 vs 0.87 ± 0.12 ; right

posterior canal 0.77 ± 0.10 vs 0.90 ± 0.10 ; left anterior canal 0.87 ± 0.10 vs 0.97 ± 0.11 ; left posterior 0.72 ± 0.18 vs 0.87 ± 0.90). Catch-up saccades were found in direction of all canals in aMCI patients while there were no saccades in normal groups.

Conclusion: In aMCI patients there was more vestibular dysfunction, which might be associated with cognitive deficits especially spatial type. In brief, vestibular investigation is suggested in aMCI patients.

Keywords: Vestibular system; mild cognitive impairment; cognition; vestibulo-ocular reflex

Citation: Yargholi S, Adel Ghahraman M, Hoseinabadi R, Aghamollaii V, Jalaie S. Vestibulo-ocular reflex in patients with amnesic mild cognitive impairment and normal controls: a comparative study. Aud Vest Res. 2018;27(2):93-100.

Introduction

The vestibular system is the phylogenetically oldest of all of the sensory systems and the earliest to mature during development. It is composed of two major types of end-organs: the otolith organs and semicircular canals. The two otolith organs—the utricle and saccule—respond to linear acceleration in the three cardinal axes and are known as the graviceptors. By contrast, the semicircular canals respond to angular motions in pitch, roll and yaw and are primarily

* **Corresponding author:** Department of Audiology, School of Rehabilitation, Tehran University of Medical Sciences, Piche-Shemiran, Enghelab Ave., Tehran, 1148965141, Iran. Tel: 009821-77535132, E-mail: madel@tums.ac.ir

designed to signal head movements and generating the vestibular-ocular reflex (VOR) [1].

Previous studies have demonstrated the role of the vestibular system in cognitive functions such as perception of self-motion, consciousness of own body, spatial navigation, learning and memory, and object recognition memory [2].

Cognitive function can be more precisely analyzed by breaking it down into a number of cognitive domains including visuospatial ability, memory, executive function, attention and emotion [3,4].

A number of studies in both experimental animals and humans have demonstrated that peripheral vestibular lesions cause deficits in cognitive functions. Deficits include spatial memory impairment that is long-lasting and may even be permanent [4], elimination of head direction cells in the anterior thalamic nucleus [5], reduction of spatial coherence and information content in the place fields of hippocampal neurons [5], neurochemical deficits in various regions of the hippocampus [6], and hippocampal atrophy to approximately 17% [7] which have demonstrated hippocampal and parahippocampal important role in topographical memory. Several other studies have shown deficits in all the other cognitive domains [3].

Among the first symptoms appeared in patients with Alzheimer's disease (AD) is topographical memory deficits accompanied by specific degeneration of the hippocampal and parahippocampal regions [1,8]. There are many hypotheses for the etiology of the AD such as build-up of beta-amyloid protein and general health risk factors, that all have failures or limitations. A recent theory has focused on vestibular system [1]. This theory originates from the connections between the vestibular system and cognitive areas. Moreover, several studies have reported vestibular abnormalities in AD patients [9,10].

The preclinical stage of AD is mild cognitive impairment (MCI). MCI is a transient phase between normal cognitive function and AD. MCI patients have memory defects beyond what is expected for their age; however, they have not

yet meet criteria for dementia. In MCI, the patient's daily function is largely preserved [10]. MCI includes two clinical subtypes: amnesic MCI (aMCI) and non-amnesic MCI (nMCI). These two clinical subtypes differ in etiology and outcome. Amnesic MCI is assumed to have a high likelihood of progress to AD dementia [11].

Most studies have investigated the relationship between vestibular system and cognition in AD patients and limited ones have focused on MCI patients. To the extent of our knowledge, no study has investigated the peripheral vestibular disorders in patients with aMCI. The purpose of this study was to expand the available evidence for peripheral vestibular system deficits in aMCI patients. Since there is an important and specific vestibular projection to the medial-temporal cortex, including the hippocampus and parahippocampal gyrus, that primarily originates from the semicircular canals and disruption of the peripheral vestibular information may deteriorate cognition, we have measured VOR gain and catch-up saccades in direction of all semicircular canals in patients with aMCI and normal peers using video head impulse test (vHIT) to determine VOR abnormalities in aMCI patient in comparison to their normal counterparts.

Methods

Twelve patients diagnosed with aMCI and 12 normal controls were included in this cross-sectional study. All patients gave written informed consent. The study was approved by the Human Research Ethics Committee of Tehran University of Medical Sciences, Code No. IR.TUMS.FNM.REC.1396.4516.

Inclusion criteria for patients were Mini Mental State Examination (MMSE) score lower than 21 [12], no history of any MCI causing diseases such as diabetes, uncontrolled hypothyroidism, traumatic brain injury, Down syndrome, cerebrovascular diseases, neurodegenerative diseases, anxiety, depression, and Lewy bodies, deficiency of vitamins especially B12; no intake of anticholinergic medicines; and no alcohol or drug abuse.

Table 1. Characteristics of the study population

	Number	Mean age±SD	Sex	History of vertigo
aMCI	12	57.66±9.35	10 Female (83.4%) 2 Male (16.6%)	25%
Controls	12	56.16±5.89	9 Female (75%) 3 Male (25%)	0%

aMCI; amnesic cognitive impairment

The control group was matched to MCI patients in terms of age. Their MMSE scores were higher than 21 and had no history of MCI. MMSE was evaluated by our neurologist.

For VOR evaluation, a video system (vHIT GN Otometrics, Denmark) was used. The chair height was adjusted while the patient was seated so that the target point on the wall would be in front of the patient’s face. The distance between the chair and target point had to be at least one meter. The patients were asked to clean their eyes from any kind of eye makeup. The light weighted vHIT goggle was worn by the patient. This goggle is equipped with a camera to record the eye movements, a mirror to reflect the eye movements to the camera and a sensor to measure the head movements [13].

In order to obtain better records and avoid incidence of any artifacts resulting from goggle slip the patients were instructed to keep their eyes as open as possible and the goggle had to be fastened sufficiently tight. Before initiation of the test, the eye position was calibrated. In order to calibrate the device the patients were asked to stare at and track a moving point on the wall while keeping their head still. Video HIT started with assessment of horizontal canals. The experimenter kept patient’s head in his/her hand while standing behind her/him. The patient’s head was moved a small amplitude and high velocity toward the right and left side. The direction of head movement had to be unpredictable to the patients. Twenty responses were usually recorded for each canal. To assess the left anterior and right posterior canals

(LARP) the patient’s head was moved 35 to 45 degree to the right side while the patients were asked to stare at the target point [14,15]. The patient’s head was moved a small amplitude and high velocity up and down. To assess right anterior and left posterior canals (RALP) the patient’s head was moved 35 to 45 degree to the left side. When 20 responses were recorded for each direction, VOR gain and overt and covert saccades were displayed by the software. A VOR deficit was defined as a vHIT gain of <0.8 for lateral canals and <0.7 for vertical canals [16,17] or presence of catch-up saccade [18-22]. All statistical analyses were performed using SPSS 24 (IBM Corp., US). Normal distribution of data was confirmed by Kolmogorov-Smirnov test. We used independent sample t-test to compare mean VOR gains between groups and chi-square test to compare occurrence of catch-up saccades between groups. The significant level was set at 0.05.

Results

The demographic characteristics of the study population is presented in Table 1. We assessed 12 aMCI patients (10 female, 2 male; age range 42 to 70 years), and 12 controls (9 female, 3 male; age range 50 to 69 years). There was no significant difference between the aMCI and normal groups in terms of age or gender.

Fig. 1, right panel represents the vHIT graphs obtained from a normal participant which shows VOR gains were within normal limits and no catch-up saccades could be observed in the examination of all semicircular canals. In comparison, vHIT graphs obtained from an

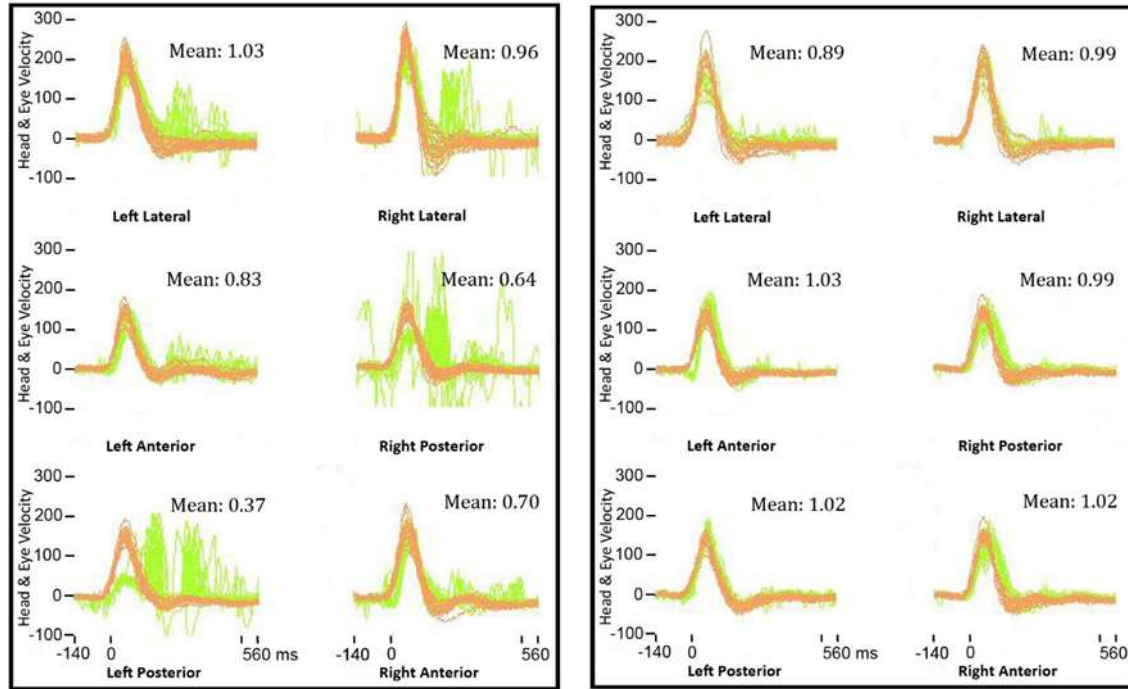


Fig. 1. Representation of video head impulse test (vHIT) results in a normal (right panel) and an amnestic cognitive impairment (left panel) participant. All gain values are presented in the box over the right corner of each test. vHIT was performed in the direction of all semicircular canals. Light green lines represent the eye movement velocity.

aMCI patient is represented in left panel. In this case catch up saccades could be observed in lateral and posterior canals.

Mean VOR gain for all semicircular canals in both groups is shown in Table 2. There were significant differences in VOR gains in direction of all vertical semicircular canals between aMCI and normal groups ($p < 0.05$). VOR gains in direction of all vertical semicircular canals were lower in aMCI compared with normal groups.

Catch-up saccades were found in direction of all canals in aMCI patients while there were no saccades in normal groups. The difference between groups was significant in direction of all canals (Fig. 2).

In general, 83.34% of patients had abnormal findings, either low gain or catch up saccades (Table 3). 18.8% had unilateral and 56.3% showed bilateral abnormalities.

Discussion

Video head impulse is a vestibular test that allows quantitative assessment of semicircular canal function and provides specific information about angular VOR. We evaluated the VOR responses in aMCI patients and normal controls. In our results, significant gain abnormalities and saccades were found in VOR evaluation of aMCI patients compared to the normal group. Although more than 80% of patients with aMCI showed VOR abnormalities, only 25% of them have had a history of vertigo. These data are consistent with previous studies establishing a link between vestibular and cognitive function. The peripheral vestibular system makes widespread projections to cortical centers involved in cognitive functions like topographical memory and spatial orientation, notably the hippocampus. There is an important and specific vestibular projection to the medial-temporal cortex,

Table 2. Mean (standard deviation) vestibular-ocular reflex gain in amnesic cognitive impairment and normal groups

Semicircular canal	Mean±SD (Min-Max) VOR Gain		
	Normal group	aMCI group	p
Right			
Lateral	1.01±0.08 (0.89-1.15)	0.94±0.13 (0.64-1.15)	0.123
Anterior	0.87±0.12 (0.71-1.06)	0.74±0.17 (0.52-1.03)	0.047
Posterior	0.90±0.10 (0.70-1.03)	0.77±0.10 (0.59-0.98)	0.004
Left			
Lateral	0.93±0.07 (0.83-1.05)	0.87±0.11 (0.65-1.03)	0.094
Anterior	0.97±0.11 (0.78-1.10)	0.87±0.10 (0.64-1.10)	0.024
Posterior	0.87±0.90 (0.75-1.02)	0.72±0.18 (0.37-1.00)	0.009

VOR; vestibular-ocular reflex, aMCI; amnesic cognitive impairment

including the hippocampus and parahippocampal gyrus, although there are large vestibular projection zone in the other regions of cortex. Anatomical studies have shown that the parietal-temporal, posterior-cingulate, and medial-temporal regions are the most important areas of the topographical and memory systems [5,23], this projection to medial-temporal cortex, is believed to emanate primarily from the horizontal semicircular canals. These projections may represent the neural basis for the association between vestibular and cognitive function [1]. Based on these anatomical connections between peripheral vestibular system and cognitive regions (specifically memory areas), the peripheral vestibular lesions may disrupt the essential information for cognitive processing and therefore lead to cognitive disorders.

A number of studies in both experimental animals and humans have demonstrated that peripheral vestibular lesions cause deficits in cognitive functions [6]. These deficits include spatial memory impairment that may last for a long time and may even be permanent [4], disruption of hippocampal place cell discharge and as a result reduction of spatial coherence and information content, and elimination of head direction cells in the anterior thalamic nucleus [5],

neurochemical deficits in different regions of the hippocampus and consequently neural changes in many linked parts like neocortex and limbic system [6], disruption of hippocampal theta rhythm (which is thought to encode spatial information) [24], hippocampal atrophy up to approximately 17% [7]. Hippocampal atrophy is a pathologic hallmark of Alzheimer's disease and the well-established vestibular-hippocampal connections may underlie the association between vestibular loss and dementia [8]. Previous studies have revealed some vestibular dysfunction in AD patients. Nakamagoe et al. evaluated vestibular function using a stepping test, caloric nystagmus, and a visual suppression in 12 patients with AD, 12 dementia-free elderly adults, and 12 younger adults. The stepping test was abnormal in 9 of the 12 patients and significant visual suppression abnormalities were present in the AD group [9]. In another study, Leandri et al. investigated the relationship between balance and cognitive level in a group of 70 women with no definite AD or mild cognitive impairment diagnosis and no impairment of daily activity. Static stabilometry and the Montreal Cognitive Assessment (MoCA) test were performed. It was concluded that the antero-posterior sway component was demonstrated to be the best

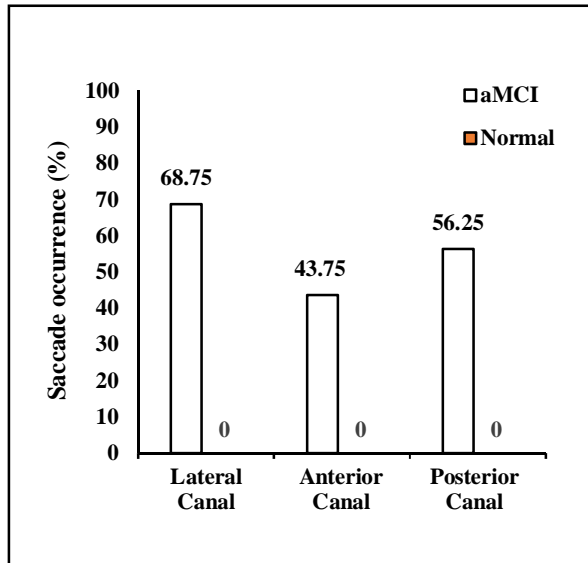


Fig. 2. Percentage of catch-up saccades in amnesic cognitive impairment patients and normal groups.

predictor of the MoCA overall score. The vestibular system was to be considered as a main link between balance and cognitive impairment, since visual and proprioceptive components of balance was excluded in their assessment [25]. Moreover, moderate physical exercise of at least 20-30 minutes two or three times per week has been shown to improve cognitive function in the elderly and to reduce substantially the risk of AD [1]. This effect was observed even when other risk factors like vascular disorders were excluded. The greater the increased blood flow to the vestibular nucleus and higher vestibular processing centers, the more beneficial effects of exercise in delaying or preventing AD. But this beneficial effect is not associated to the blood flow changes in cochlear nucleus or any other hearing centers. Physical exercise has also been shown to improve various vestibulospinal and vestibulo-ocular reflexes. It is noteworthy that physical exercise specifically increases the volume of the anterior hippocampus that receives vestibular input and is most affected in AD but does not alter caudate nucleus or thalamic volumes [1].

A limited number of studies are available on

evaluation of vestibular system in MCI patients. Birdane et al. evaluated 20 patients with AD and 10 patients with mild cognitive impairment. Control group was 30 healthy volunteers with no neurological or otological diseases. Abnormal vestibular evoked myogenic potential (VEMP) responses were found in most of the patients at different stages of AD and it was concluded that VEMP test may be used for early diagnosis of AD [26]. Harun et al. have measured cervical and ocular VEMPs and VOR gain in the horizontal canals in MCI and AD patients. Although some abnormalities in VEMP parameters were reported in AD patients, there was no significant difference in VOR gain between the groups in this study and catch up saccades were not evaluated [10]. These discrepancies between their findings and ours may be in part due to our focus on aMCI patients. In our study, VOR gains in direction of all vertical semicircular canals were lower in aMCI compared with normal group. Vestibular information from end organs of vertical semicircular canals and otoliths ascend to higher parts of processing via inferior vestibular nerve. On the other hand stimulation of saccule leads to widespread cortical activation, including the posterior insular cortex, the inferior parietal cortex, the intraparietal sulcus, and temporoparietal junction which are cognitive domains. Since previous studies have shown VEMP abnormalities in these patients, it is possible that the results of our study be associated to disruption of information sent by inferior vestibular nerve.

Table 3. Total video head impulse test abnormalities in amnesic cognitive impairment and normal groups

vHIT findings	aMCI group	Normal group
Normal gains without saccades	16.66%	100%
Normal gains and saccades	41.66%	0%
Low gain with/without saccades	41.66%	0%
Saccades with/without low gains	83.33%	0%

vHIT; video head impulse test, aMCI; amnesic cognitive impairment

Conclusion

In amnesic MCI patients, there is more vestibular dysfunction, which may be associated with cognitive deficits especially spatial type. It is highly recommended to consider vestibular examinations in these patients and conduct therapeutic and rehabilitative interventions in vestibular impaired patients.

Acknowledgments

The present paper is emerged from S. Yargholi's MSc dissertation and supported by grant No. 37008 from Tehran University of Medical Sciences.

Conflict of Interest

The authors declare that they have no conflict of interest.

REFERENCES

- Previc FH. Vestibular loss as a contributor to Alzheimer's disease. *Med Hypotheses*. 2013;80(4):360-7. doi: [10.1016/j.mehy.2012.12.023](https://doi.org/10.1016/j.mehy.2012.12.023)
- Hitier M, Besnard S, Smith PF. Vestibular pathways involved in cognition. *Front Integr Neurosci*. 2014;8:59. doi: [10.3389/fnint.2014.00059](https://doi.org/10.3389/fnint.2014.00059)
- Bigelow RT, Agrawal Y. Vestibular involvement in cognition: Visuospatial ability, attention, executive function, and memory. *J Vestib Res*. 2015;25(2):73-89. doi: [10.3233/VES-150544](https://doi.org/10.3233/VES-150544)
- Smith PF, Zheng Y. From ear to uncertainty: vestibular contributions to cognitive function. *Front Integr Neurosci*. 2013;7:84. doi: [10.3389/fnint.2013.00084](https://doi.org/10.3389/fnint.2013.00084)
- Smith PF. Vestibular-hippocampal interactions. *Hippocampus*. 1997;7(5):465-71. doi: [10.1002/\(SICI\)1098-1063\(1997\)7:5<465::AID-HIPO3>3.0.CO;2-G](https://doi.org/10.1002/(SICI)1098-1063(1997)7:5<465::AID-HIPO3>3.0.CO;2-G)
- Smith PF, Darlington CL, Zheng Y. Move it or lose it--is stimulation of the vestibular system necessary for normal spatial memory? *Hippocampus*. 2010;20(1):36-43. doi: [10.1002/hipo.20588](https://doi.org/10.1002/hipo.20588)
- Brandt T, Schautzer F, Hamilton DA, Brüning R, Markowitsch HJ, Kalla R, et al. Vestibular loss causes hippocampal atrophy and impaired spatial memory in humans. *Brain*. 2005;128(Pt 11):2732-41. doi: [10.1093/brain/awh617](https://doi.org/10.1093/brain/awh617)
- Jack CR Jr, Shiung MM, Weigand SD, O'Brien PC, Gunter JL, Boeve BF, et al. Brain atrophy rates predict subsequent clinical conversion in normal elderly and amnesic MCI. *Neurology*. 2005;65(8):1227-31. doi: [10.1212/01.wnl.0000180958.22678.91](https://doi.org/10.1212/01.wnl.0000180958.22678.91)
- Nakamagoe K, Fujimiyama S, Koganezawa T, Kadono K, Shimizu K, Fujizuka N, et al. Vestibular function impairment in Alzheimer's disease. *J Alzheimers Dis*. 2015;47(1):185-96. doi: [10.3233/JAD-142646](https://doi.org/10.3233/JAD-142646)
- Harun A, Oh ES, Bigelow RT, Studenski S, Agrawal Y. Vestibular impairment in dementia. *Otol Neurotol*. 2016;37(8):1137-42. doi: [10.1097/MAO.0000000000001157](https://doi.org/10.1097/MAO.0000000000001157)
- Busse A, Hensel A, Gühne U, Angermeyer MC, Riedel-Heller SG. Mild cognitive impairment: long-term course of four clinical subtypes. *Neurology*. 2006;67(12):2176-85. doi: [10.1212/01.wnl.0000249117.23318.e1](https://doi.org/10.1212/01.wnl.0000249117.23318.e1)
- Foroughan M, Jafari Z, Shirin Bayan P, Ghaem Magham Farahani Z, Rahgozar M. Validation of mini-mental state examination (mmse) in the elderly population of Tehran. *Advances in Cognitive Science*. 2008;10(2):29-37.
- Curthoys IS, MacDougall HG, McGarvie LA, Weber KP, Szmulewicz D, Manzari L, et al. The video head impulse test (vHIT). In: Jacobson GP, Shephard NT, editors. *Balance function assessment and management*. San Diego, CA: Plural Publishing; 2014. p. 391-430.
- Halmagyi GM, Chen L, MacDougall HG, Weber KP, McGarvie LA, Curthoys IS. The video head impulse test. *Front Neurol*. 2017;8:258. doi: [10.3389/fneur.2017.00258](https://doi.org/10.3389/fneur.2017.00258)
- Guerra Jiménez G, Pérez Fernández N. Reduction in posterior semicircular canal gain by age in video head impulse testing. observational study. *Acta Otorrinolaringol Esp*. 2016;67(1):15-22. doi: [10.1016/j.otorri.2014.12.002](https://doi.org/10.1016/j.otorri.2014.12.002)
- Fallahnezhad T, Adel Ghahraman M, Farahani S, Hoseinabadi R, Jalaie S. Vestibulo-ocular reflex abnormalities in posterior semicircular canal benign paroxysmal positional vertigo: a pilot study. *Iran J Otorhinolaryngol*. 2017;29(5):269-74. doi: [10.22038/IJORL.2017.22120.1761](https://doi.org/10.22038/IJORL.2017.22120.1761)
- Pérez-Garrigues H, Sivera R, Vílchez JJ, Espinós C, Palau F, Sevilla T. Vestibular impairment in Charcot-Marie-Tooth disease type 4C. *J Neurol Neurosurg Psychiatry*. 2014;85(7):824-7. doi: [10.1136/jnnp-2013-307421](https://doi.org/10.1136/jnnp-2013-307421)
- Curthoys IS. The interpretation of clinical tests of peripheral vestibular function. *Laryngoscope*. 2012;122(6):1342-52. doi: [10.1002/lary.23258](https://doi.org/10.1002/lary.23258)
- Eza-Nuñez P, Fariñas-Alvarez C, Perez-Fernandez N. The caloric test and the video head-impulse test in patients with vertigo. *Int Adv Otol* 2014;10(2): 144-9. doi: [10.5152/iao.2014.64](https://doi.org/10.5152/iao.2014.64)
- Korsager LEH, Schmidt JH, Faber C, Wanscher JH. Reliability and comparison of gain values with occurrence of saccades in the EyeSeeCam video head impulse test (vHIT). *Eur Arch Otorhinolaryngol*. 2016;273(12):4273-4279. doi: [10.1007/s00405-016-4183-2](https://doi.org/10.1007/s00405-016-4183-2)
- Perez-Fernandez N, Eza-Nuñez P. Normal gain of vor with refixation saccades in patients with unilateral vestibulopathy. *J Int Adv Otol*. 2015 Aug;11(2):133-7. doi: [10.5152/iao.2015.1087](https://doi.org/10.5152/iao.2015.1087)
- Abrahamsen ER, Christensen AE, Hougaard DD. Intra- and interexaminer variability of two separate video head impulse test systems assessing all six semicircular canals. *Otology and Neurology*. 2018;39(2):e113-e22. doi: [10.1097/MAO.0000000000001665](https://doi.org/10.1097/MAO.0000000000001665)
- Shinder ME, Taube JS. Differentiating ascending vestibular pathways to the cortex involved in spatial cognition. *J Vestib Res*. 2010;20(1):3-23. doi: [10.3233/VES-2010-0344](https://doi.org/10.3233/VES-2010-0344)
- Russell NA, Horii A, Smith PF, Darlington CL, Bilkey DK. Lesions of the vestibular system disrupt hippocampal theta rhythm in the rat. *J Neurophysiol*. 2006;96(1):4-14. doi: [10.1152/jn.00953.2005](https://doi.org/10.1152/jn.00953.2005)

25. Leandri M, Campbell J, Molfetta L, Barbera C, Tabaton M. Relationship between balance and cognitive performance in older people. *J Alzheimers Dis.* 2015;45(3):705-7. doi: [10.3233/JAD-142883](https://doi.org/10.3233/JAD-142883)
26. Birdane L, Incesulu A, Gurbuz MK, Ozbabalik D. Sacculocolic reflex in patients with dementia: is it possible to use it for early diagnosis? *Neurol Sci.* 2012;33(1):17-21. doi: [10.1007/s10072-011-0595-3](https://doi.org/10.1007/s10072-011-0595-3)