

Report of trichobezoar causing peritonitis in a captive African lion (*Panthera leo*)

Baharak Akhtardanesh^{1*}, Reza Kheirandish², Nadia Nadimi³, Alireza Nakhaei⁴
and Rasoul Shademan⁵

¹ Professor, Department of Clinical Sciences, Faculty of Veterinary Medicine, Shahid Bahonar University of Kerman, Kerman, Iran

² Professor, Department of Pathobiology, Faculty of Veterinary Medicine, Shahid Bahonar University of Kerman, Kerman, Iran

³ DVM Graduated, Faculty of Veterinary Medicine, Shahid Bahonar University of Kerman, Kerman Iran

⁴DVM Graduated, Zoo Clinician, Abshar Zoo Park, Kerman, Iran

⁵ MSc of Animal Science Abshar Zoo Park, Kerman, Iran

Received: 05.10.2019

Accepted: 15.06.2020

Abstract

This report describes a huge gastric trichobezoar in a 12-year old male captive African lion (*Panthera leo*) leading to gastric perforation, fatal peritonitis and death. At necropsy, the stomach seemed firm, highly distended and filled with a giant mass weighted 3800 grams. A big perforation was identified in the antrum which caused severe pyoperitoneum, septic shock and death. Restricted physical activity at nights, whole carcasses feeding, lack of fiber supplement or laxatives and repetitious diet were the major risk factors for trichobezoar formation in this case. Trichobezoar should be considered as a common gastrointestinal disease in captive wild cats, so nutritional and medical preventive regimen is highly recommended for lions in zoos. Determining the common causes of morbidity and mortality of wild felines housed in zoological collections will provide insights that contribute to their improved care, health, and medical management in captivity and ultimately affect the sustainability of these species in the wild.

Key words: *Panthera leo*, Zoo, Gastric Trichobezoar, Peritonitis

Introduction

The word "bezoar" corresponds to accumulation of indigestible foreign substances along the digestive tract, which commonly found in the stomach and proximal portions of the small bowel (Bocknek 2002). Trichobezoar includes hair; phytobezoar (vegetable matter such as skin, seeds, and fiber) and lithobezoar (mud and stones) which is a common gastrointestinal problem in cats, calves and goats (Czerwinska et al. 2014, Dann et al. 2004).

Hair swallowing (trichophagia) has been described in humans, dogs, cats, rabbits, mice, guinea pigs, sheep and nonhuman primates which has been classified as a neuropathological behavior that seems quite similar to trichotillomania in humans (Dutta et al. 2016). This phenomenon is also responsible for trichobezoars formation in animals. Trichobezoars are an affliction of domesticated cats due to their grooming habits and barbed tongue structure (Ginman 2008, Reed et al. 2004). Normally this hair

* **Corresponding Author:** Baharak Akhtardanesh, Professor, Department of Clinical Sciences, Faculty of Veterinary Medicine, Shahid Bahonar University of Kerman, Kerman, Iran, E-mail: Bakhtardanesh@yahoo.com



© 2020 by the authors. Licensee SCU, Ahvaz, Iran. This article is an open access article distributed under the terms and conditions of the Creative Commons Attribution-NonCommercial 4.0 International (CC BY-NC 4.0 license) (<http://creativecommons.org/licenses/by-nc/4.0/>).

is passed through the gastrointestinal tract and expelled in the feces. Occasionally the aggregated ball of hair can accumulate and potentially serious obstruction can occur. In the case of huge mass formation, cats cannot get rid of them by vomiting (Isberner et al. 2010, Kottwitz and Munsterman 2014). Some risk factors have been associated with hair ball and felines may be predisposed to trichobezoar due to long hair coats, fastidious grooming habits, and lack of strong peristaltic contractions called migrating motor complexes (MMC) (Kottwitz and Munsterman 2014, Mejido et al. 2009).

Over-grooming because of allergies, skin parasites, stress or anxiety, dermatophytosis or other skin disease maybe other underlying disease however there is still limited information on the underlying cause and overall incidence of feline trichobezoars and very few reports is available about exotic feline (Woerde et al. 2019, Isberner et al. 2010).

Severe cases may lead to complications such as gastric mucosal erosion, ulceration, and perforation of the stomach or the small intestine, gastric outlet obstruction, intussusception, obstructive jaundice, protein-losing enteropathy, pancreatitis and death (Dutta et al. 2016, Mejido et al. 2009). This report describes a huge gastric trichobezoar in a 12-year old male captive African lion (*Panthera leo*) leading to gastric perforation, fatal peritonitis and death.

Case history

A 12-year old male African lion was noticed with gradual weight loss (180 kg to 150 kg) (Fig. 1) during one year after he missed another male lion which kept with him in the same cage. The keeper claimed that the gradual weight loss is attributed to decrease of physical activity because the brothers spent a lot of time, playing with each other. The lions feeding program were whole donkey carcasses which has a certain amount of skin and hair and portion of beef carcasses without skin every other day. His

appetite and feeding behavior were acceptable until the lion showed signs of acute anorexia; however during daily cleaning of the enclosure and close observation, keepers found no other evidence. At the evening the animal showed vomiting of semi-digested food, abdominal pain with restlessness and suddenly turned to the recumbent position at the 10 pm. When the clinical sign was reported to the clinician, the lion was in the hypovolemic shock. Immediately, the animal was taken into squeeze cage, the IV catheter was fixed, blood sampling was done and hypertonic fluids therapy was started.



Fig1. Poor body condition score was noted on the trichobezoar affected lion

Method of diagnosis

The case was highly suspected to gastric dilation and volvulus but during clinical examination, abdominal distention was not detected. The clinician tried to perform the diagnostic imaging and set an appointment with surgery team but unfortunately the animal was died. Necropsy was immediately done at the enclosure. The stomach seemed firm, highly distended and filled with a huge trichobezoar mass weighted 3800 grams (Fig. 2 & Fig. 3). A big (4×5 cm) perforation was identified in the antrum which caused severe pyoperitoneum. Intussusception or infarction was not seen in small and large intestines but hyperemia was noted. The small amount of the concentrated straw-colored exudate was seen in the peritoneal space which was sampled for cytological examination. High total protein concentration (6 g/dl), high specific gravity

(1.058), and increased cellularity dominated by degenerated neutrophils and macrophages, and many coccobacillus bacteria were seen in the Geimsa staining. The complete blood count showed elevated hematocrit (68%), sever leukocytosis (49000/ μ l), neutrophilia, shift to left and toxic change. Biochemical evolution showed elevated globulin (6 mg/dl), BUN (134 mg/dl) and creatinine (5.2 mg/dl) level. Samples were obtained from esophagus, stomach, liver, spleen, small and large intestine and sent for histopathological examination. Necrosis and sloughing of the gastric mucosa (Fig. 4) and presence of fibrinopurulent exudate in the gastric serosa (Fig. 5) was reported. The gastric outlet obstruction and perforation, focal peritonitis and endotoxic shock was diagnosed as the main death factors based to the leukemoid reaction in hematological evaluation, cytological and histopathological findings. However surprisingly, except gradual weight loss; the animal did not show any obvious clinical sign of severe gastric impaction before death which could facilitate the fast diagnosis.

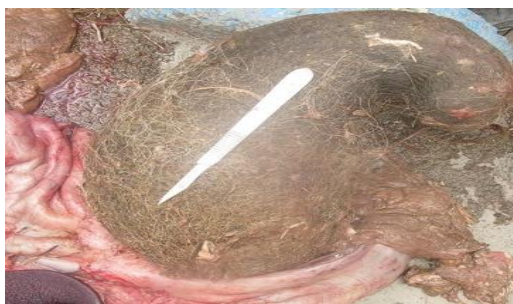

Fig 2. The stomach was completely filled with huge trichobezoar mass weighted 3800 grams.



Fig 3. Giant bezoar after necropsy

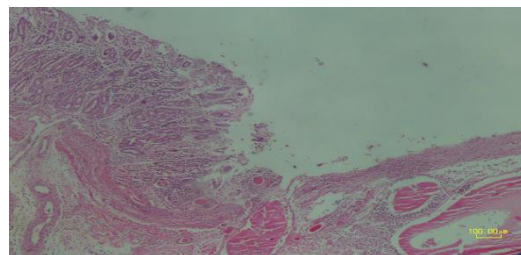


Fig 4. Necrosis and sloughing of the gastric mucosa, H&E, Bar=100 μ m

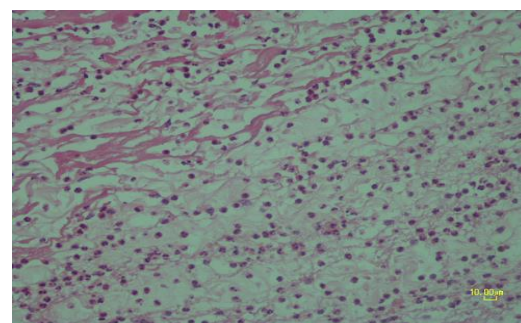


Fig 5. Presence of fibrinopurulent exudate in the gastric serosa, H&E, Bar=10 μ m

Discussion

Very limited reports about trichobezoar formation in wild cats are available in the literature reviews. Trichobezoar is reported in a 10-year old tiger (*Panthera Tigris*) with the history of constipation, unproductive retching and loss of appetite. The case was treated with enema (Napier et al., 2018). Pyloric trichobezoar was reported in a Canadian Lynx (*Lynx Canadensis*) because of flea infestation and excessive trichophagia but this case was treated by gastrostomy (Kottwize et al., 2014). In the reported case, ectoparasite prevention was routinely done by monthly washing and spraying of whole enclosure by cypermethrin (Golsam, Iran) and no infestation was diagnosed in clinical examination.

The two most common causes of death or euthanasia in senior and geriatric big cats were reported chronic renal disease and neoplasia; but foreign body ingestion and trichobezoar were the common reason for exploratory surgery in big felines. Literature reviews showed that if wild cats passed their neonatal period in the captivity, they often live into their late teens when

they face to the geriatric problems (Napier et al. 2018).

Unfortunately, clinical symptoms related to the presence of a trichobezoar within the gastrointestinal tract are characterized by late onset and lack of specificity, causing late diagnosis. Diagnostic procedures are commonly initiated owing to acute abdominal symptoms (Ventura et al. 2005). On the other hand; exotic felines present a diagnostic dilemma, due to the inability to perform a thorough physical examination without anesthesia which creates more complication in the diagnostic procedures. Lack of knowledge and skills in zoo keepers and ignorance in reporting of specific clinical signs are other issues that can cause unintended deaths in these animals (Ginman, 2008).

Although many of exotic feline with hair ball were cured after laparotomy, 60% of baboons with trichobezoar, showed no clinical signs before death and high case fatality rate because of intestinal obstruction, intussusception and peritonitis was reported in this primate as like as the present report (Mejido et al. 2009).

The average longevity of African lion in the wild is about 14 years but in captivity and in a good condition it increased to maximum 30 years. The shape and size of the enclosure is an important factor which must provide enough moving space and physical activity. Lions are nocturnal animals so it is highly important to maintain their natural behavior and keep them active at night. Keeping at a resting cage at night, small moving area and restricted physical activity, decreases the gastrointestinal

peristaltic movements and could be risk factors for hair ball formation which all were detected in the reported case (Bockneck 2002).

In captivity, lions spent less energy than in the wild and will require less meat consumption. Besides, they must have a varied diet, as they have access to a variety of animals in the wild. Fixed feeding regimens may induce anorexia which has been happened in this case (Ginman, 2008). On the other hand, periodic administration of petrolatum-based lubricants such as liquid paraffin through bait which helps in prevention of trichobezoar formation in exotic feline was not performed for the dead lion (Podhade et al. 2014). All of the mentioned risk factors and neglecting about the importance of the chronic weight loss, create the fatal hair ball peritonitis and death in this case.

Based to this clinical report and literature reviews, trichobezoar should be considered as a common gastrointestinal disease in captive wild cats, so nutritional and medical preventive regime is highly recommended for lions in zoos.

Proper professional training of zoo staff and zoo veterinarians greatly reduces the breakdowns in the diagnostic process which is highly recommended.

Determining the common causes of morbidity and mortality of wild felines housed in zoological collections will provide insights that contribute to their improved care, health, and medical management in captivity and ultimately affect the sustainability of these species in the wild.

Acknowledgement

We would like to thank Dr. Mohammad Zamani for his kind laboratory supports.

Conflict of interest

Authors have declared that no competing interests exist.

Funding

The authors are grateful to Research Council of Shahid Bahonar University for financial support.

References

- Bocknek, J. (2002). *The Untamed world: Lions*, Weigl Educational Publishers Limited, 2th.ed .Austin, P: 108-116.
- Czerwiska, K.; Bekiesińska-Figatowska, M.; Brzewski, M.; Michał Gogolewski, M. and Wolsk, M. (2015). Trichobezoar, Rapunzel syndrome, Tricho-plaster bezoar—a report of three cases. *Polski Przegląd Radiologii i medycyny nuklearnej*, 80(1): 241-246.
- Dann, J.R.; Adler, M.A.; Duffy, K.L. and Giffard, C.J. (2004). A potential nutritional prophylactic for the reduction of feline hairball symptoms. *The Journal of Nutrition*, 134(8): 2124-2125.
- Dutta, P.; Choudhur, Y.P.R. and Thakkar, V. (2016). Trichobezoar: a Case Report. *International Journal of Medical Science and Public Health*, 5(1): 149-151.
- Ginman, L. (2008). Management of Big Cats in Australian Zoos. *Australasian Society of Zoo Keeping*.Thylacinus, Australia, P: 56.
- Isberner, R.K.; Couto, C.A. and Scolaro, B.L. (2010). Giant Gastric Trichobezoar: a Case Report and Literature Review. *Radiologia Brasileira*, 43(1):63-65.
- Kottwitz, J. and Munsterman, A.S. (2014). Pyloric trichobezoar in a Canadian lynx (*Lynx canadensis*). *Journal of Zoo and Wildlife Medicine*, 44: 1111-1114.
- Mejido, D.C.; Dick, J.R.; Williams, P.C.; Sharp, R.M.; Andrade, M.C.; DiCarlo, C.D. and Hubbard, G.B. (2009). Trichobezoars in baboons. *Journal of Medical Primatology*, 38(5): 302-309.
- Napier, J.E.; Lund, M.S; Armstrong, D.L. and McAloose, D. (2018). A Retrospective study of morbidity and mortality in the North American Amur Leopard (*Panthera Pardus Orientalis*) population in zoologic institutions from 1992 to 2014. *Journal of Zoo and Wildlife Medicine*, 49(1):70-78.
- Podhade, D.N.; Harne, R. and Jagtap, H.V. (2014). Therapeutic Management of Trichobezoar in Tiger (*Panthera Tigris*). *Veterinary Practice*, 15(1): 128.
- Reed, E.A.; Belvea, R.L.; Newcomb, M.D. and Shields, Jr.R. (2004). Feline Trichobezoars: Composition and Degradation. *Journal of Animal and Veterinary Advances*, 3(12): 833-841.
- Ventura, D.E.; Herbella, F.A.; Schettini, S.T. and Delmonte, C. (2005). Rapunzel syndrome with a fatal outcome in a neglected child. *Journal of Pediatric Surgery*, 40: 1665-1667.
- Woerde, D.J.; Hoffmann, K.L.; Kicinski, A.1. and Brown, N.L. (2019). Oesophageal Obstruction Due to Trichobezoars in two Cats. *Journal of Feline Medicine and Surgery*. *Open Reports*, 5(1): 2055.