



Wound Healing and Toxicity Evaluation of *Aloe vera* Cream on Outpatients with Second Degree Burns

Abdolhossein Moghbel^{a,*}, Abdolazim Ghalambor^b, Shahram Allipanah^a

^aDepartment of Pharmaceutics, Faculty of Pharmacy, ^bTaleghani Hospital, Ahvaz Jundishapour University of Medical Sciences, Ahvaz, Iran

Abstract

Aloe vera is a tropical plant belonging to the Liliaceae family. It has beneficial effects in variety of diseases. The aim of this study was to formulate a topical cream from *A. vera* with wound burn healing effect and to perform its clinical trial. A total of 30 patients (20 males and 10 females in the age range of 20-50 years) with second degree burn wounds on their both hands were selected for the study. The subjects used *A. vera* topical formulation or silver sulfadiazine 1% cream on each hand as the test and control, symmetrically. The rate of healing was measured and compared on 0 to 18 days after treatment. Results indicated that average percent of healing with *A. vera* on day 10 was 90.6% compared with silver sulfadiazine which was only 29.8% ($p < 0.001$). Toxicity monitoring of the burn surfaces during healing course according to patient responses showed neither rashes, swelling, inflammation, redness, irritation, itching nor any other toxicity symptoms. Significant effect of *A. vera* on burn wounds without any adverse dermal toxic effects is very promising and it may be employed in management of burn wound, routinely.

Keywords: *Aloe vera*; Burn; Cream; Silver sulfadiazine; Wound healing.

Received: March 28, 2007; **Accepted:** May 22, 2007

1. Introduction

The second degree burns are probably one of the most frequent occurrence in homes or countries that needs improvement of treatment. *Aloe vera* is a tropical plant which belongs to the Liliaceae family [1]. This plant has been introduced for healing of burns and wounds in traditional medicine and is noticed in new herbal medicine [2]. The rough and tall leaves of *A. vera* (Figure 1) contain a thick and pale

white gel with 99% water and some mono- or polysaccharide active ingredients such as mannose-6-phosphate and accemanan, respectively. Recently, a glycoprotein named "alprogen" with antiallergic properties, and a new antiinflammatory compound such as *c*-glucosyl choromon, have been extracted from the gel [3-6]. An *in vitro* study on animal skin and pathological fibroblasts in contact with *A. vera* gel had previously been carried out by the authors [7]. The purpose of this study was to assess the healing effect of a new formulation of *A. vera* gel on human skin and monitoring of its dermal toxicity.

*Corresponding author: Abdolhossein Moghbel, Department of Pharmaceutics, Faculty of Pharmacy, Ahvaz Jundishapour University of Medical Sciences, Ahvaz, Iran.
Tel (+98)611-3338830, Fax (98)611-3338830
E-mail: drmoghbel@yahoo.com



Figure 1. *Aloe vera* living plant.

2. Materials and methods

2.1. Materials

A. vera leaves were collected from the Botanic garden of Faculty of Pharmacy, Jundishapur Ahvaz University of Medical Sciences, in spring and identified by Department of Horticulture, Faculty of Agriculture. A voucher specimen (No.93) was deposited at the herbarium in the Department of Pharmacognosy, Faculty of Pharmacy. After cutting off the fresh leaves of *A. vera* the natural gel of leaves was extracted by squeezing the paranshim cells. The gel was concentrated using mild heat of 40-50 °C under a laminar air flow (Fse2120p, Farpajou, Iran). The extract was obtained with 93% yield using the Soxhlet procedure and a rotatory evaporator.

2.2. Formulation preparation

The best prepared formulation with a suitable emulsified base was adjusted and incorporated at 70-75 °C on a water bath (Memmert, IB, England). The oily phase contained materials such as: Stearyl alcohol, liquid paraffin, petrolatom, wool fat and

eucerine. The water phase composition was prepared using sodium lauryl sulfate, methyl paraben, propyl paraben, and propylene glycol, respectively. All chemical ingredients were purchased from Merk Co., Germany. The emulsified final based contained about 15% of the natural gel. The last formulation was tested physically and chemically to select the most stable and desirable product thermodynamically or physiologically. Samples were sterilized by Gamma radiation.

2.3. Clinical study

A total of 30 patients (20 males and 10 females in the age range of 20-50 years) with second degree burn wounds on their both hands were selected for the study. The subjects used *A. vera* topical formulation and silver sulfadiazine 1% cream on each hand as the test and control (routine) treatments, symmetrically. Burn wounds were treated twice daily under a nursing care device. In order to quantify the rate of burn wound healing, every 24 h each person was held in the standard position and outline of the burn wound was traced on a sterilized transparent plastic sheet using a fine tipped pen. The area of the burn wounds on the first day were considered as 100% (0% healing) and the wound areas on subsequent days were compared with the wound on the initial day [8]. Also, the pathological changes, e.g., granulation tissue formation and reepithelization in wounds and their comparison with the normal tissue part were inspected medically by the specialist doctor [9]. All the ethical issues were considered throughout the experiment. The patient followed the approval of ethics committee of the university and Taleghani hospital. The advantages and probable disadvantages of the treatments were completely explained to participants before they gave informed consent. In addition, participants completed an individual information sheet and informed consent. The trial was carried out as a double blind study

at an especial hospital for burn accidents. Furthermore, to omit the genetic, nutrition, physiologic, environment and drug diet parameters, the application of sample and control were compared on the different hands of same persons.

2.4. Statistical analysis

Statistical analysis was carried out by t-test, using the SPSS statistical package and *p* values of less than 0.001 were considered as significant.

3. Results

The physical and chemical tests of the last formulation in a 3 month period showed that the most stable product could be formulated at pH 5.3. Also, this product showed zero growth of micro-organisms when was exposed to about 3 Krays of gamma cell ray for 119 min. (0.4206 GY/sec).

The mean±SEM period of healing in group treated with 1% silver sulfadiazine (positive control) and *A. vera* cream from 3 to 18 days of a 42-day study are shown in Table 1. Also, the significant differences ($p < 0.001$) between routine treatment by a chemical product positive control and the new herbal drug for 3, 7, 10 and 18 days of application are compared in Figure 2. Healing in subjects treated with *A. vera* and silver sulfadiazine were completed within 18 and 28 days, respectively. Any toxicity evidence or dermal abnormal sign indicating rashes, post positive swelling or inflammation, redness, irritation and itching were not seen.

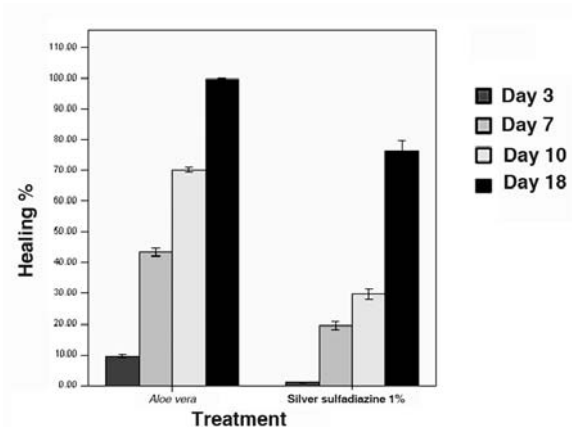


Figure 2. Comparison of healing (%) on particular days in patients with second degree burn.

4. Discussion

A. vera has an ancient history in medicine, a plant called "burn tree" or "first aid plant" [1]. It is natively from Africa, but widely used in Iran (Bousher province and Khark Island), Egypt, Greece, Rome and India [10, 11]. Interpretation of results indicated that average percentage of healing with *A. vera* after 3 days of treatment is about 14 times faster than routine treatment of 1% silver sulfadiazine ($p < 0.001$). This result for the few first days of burn is very surprising. In *A. vera* subjects, 20 patients after 10 days and 9 after 18 days were completely treated and only one person was infected; whereas with silver sulfadiazine, the final treatment took more time (28 and 42 days for 20 and 3 patients, respectively) with 7 infected patients who needed dermal graft. Therefore, the period of healing with *A. vera* is about one-half shorter than routine treatment with silver sulfadiazine. We can not propose the exact mechanism of *A. vera* natural gel in burn

Table 1. The mean±SEM of healing (%) on different days in patients with second degree burn.

Treatment days	<i>Aloe vera</i>		Silver sulfadiazine (1%)	
	Mean	SE	Mean	SE
3	16.66	0.98	1.17	0.20
5	50.76	2.74	4.87	0.34
7	73.45	3.89	19.61	1.27
10	90.59	2.60	29.83	1.80
14	88.89	1.09	48.26	2.47
18	99.67	0.24	76.39	3.20

wound healing. However, significant differences of *A. vera* treated groups especially at the primary days, suggests that mannose-6-phosphate which contain glucose and mannose chains may be effective in healing rate. This conclusion also was reported by Davis *et al.* [12] introducing mannose-6-phosphate as the active part of *A. vera* responsible in wound healing. Also, recently polysaccharide of accemannan was reported to be more effective in healing [13]. Comparison between these results and the findings of the same researchers showed that the concentration of pure *A. vera* gel had been the most effective factor. According to the results of the present study, we may suggest that this herbal medicine be used instead of silver sulfadiazine at least for the first few days of burns at homes or hospitals.

References

- [1] *Iranian herbal pharmacopeia*. Vol. 1. Tehran: Ministry of Health and Medical Education, 2002; pp. 528-30.
- [2] Newall CA, Anderson LA, Phillipson JD. *The herbal medicines*. London: The Pharmaceutical Press, 1996; pp. 25-7.
- [3] Wendell LC. *Aloe vera*. Bloomfield: Jobson Publication, 2005; p. 1.
- [4] Klein A, Penneys N. *Aloe vera*. *J Am Acad Dermatol* 1988; 18: 714-20.
- [5] Sabeh F, Wright T, Norton SJ. Purification and characterization of glutathione peroxidase from *Aloe vera* plant. *Enzyme Protein* 1993; 47: 92-8.
- [6] Sabeh F, Wright T, Norton SJ. Isozymes of superoxide dismutase from *Aloe vera*. *Enzyme protein* 1996; 49: 212-21.
- [7] Moghbel A, Agheli H., Hemati A, Rasidi I. *Burn congress abstract book*. Tehran, 2002; p. 124, 130.
- [8] Moghbel A, Hemati A, Agheli H, Rashidi I, Amraee K. The effect of tragacanth mucilage on the healing of full-thickness wound in rabbit. *Arch Iranian Med* 2005; 8: 257-62.
- [9] Troyer M. *Principle and techniques of histochemistry*. Masachoset: Little Brown Company, 1980.
- [10] Zawahary ME, Hejazy MR, Helal M. Use of *Aloe vera* in treating leg ulcers and dermatoses. *Int J Dermatol* 1973; 12: 68-73.
- [11] You IC, Hi Y, Ag AW. A lot of unfavorable out come of burn patients with neuropsy chiatric disorders. *Tohoka J Med* 2005; 205: 241-5.
- [12] Davis RH, Donato JJ, Harthman GM, Haas RC. Antiinflammatory and wound healing activity of growth substance in *Aloe vera*. *J Am Podiatr Med Assoc* 1994; 84: 77-81.
- [13] Thomas DR, Goode PS, LaMaster K, Tennyson T. Acemannan hydrogel dressing versus saline dressing for pressure ulcers. A randomized, controlled trial. *Adv Wound Care* 1998; 11: 273-6.