



Development and Study of Wound Healing Activity of an Ayurvedic Formulation

Akansha Jain^{a,*}, Shubham Jain^a, Aakash S. Panwar^b, Ankit Jain^b, Praveen Sharma^b,
G. N. Darwhekar^b

^aSAFE Institute of Pharmacy, Indore, M.P., India

^bCollege of Pharmacy, IPS Academy, Indore, M.P., India

Abstract

The effect of prepared Ayurvedic formulation was evaluated on excision and incision wound models in rats. The wound-healing activity was assessed by the rate of period of epithelialization and skin-breaking strength. Histological study of the granulation tissue was carried out to know the extent of collagen formation in the wound tissue. The Ayurvedic formulation prepared was then promoted for wound-healing activity in two wound models. The treated animals showed a significant reduction in the wound area and faster rate of epithelialisation. In an incision wound model, formulation treated animals demonstrated a significant skin-breaking strength. Histological studies of the tissue obtained from the formulation treated group revealed that the activity was more significant in this group. Our present study reveals that the Ayurvedic formulation possesses a potent wound healing activity, which could be a good choice of remedy for wound healing but less potent than standard nitrofurazone.

Keywords: Ayurvedic medicinal plants; Excision wound; Incision wound model.

Received: January 15, 2011; *Accepted:* March 18, 2011

1. Introduction

The therapeutic efficacies of many indigenous plants for various diseases have been described by traditional herbal medicine practitioners [1]. Natural products are a source of synthetic and traditional herbal medicine [2]. The Indian traditional system of medicine described several drugs of plant, mineral, and animal origin are in the Ayurveda for their wound healing properties, Scientists who are

trying to develop newer drugs from natural resources are looking toward the Ayurveda [3]. The presence of various life sustaining constituents in plants has urged scientists to examine these plants with a view to determine potential wound healing properties. Researchers who have explored the complex dynamics of tissue repair have identified several nutritional cofactors involved in tissue regeneration, including vitamins A, C, and E, zinc, arginine, glutamine, and glucosamine [4].

Tissue injury initiates a response that first clears the wound of devitalized tissue and foreign material, setting the stage for

*Correspondence Address: Akansha Jain, SAFE Institute of Pharmacy, Indore, M.P., India
Tel. (+91)-9827597375
Fax. (+91)-07315046566
E-mail: aakash_ips@yahoo.com.sg

subsequent tissue healing and regeneration. The second phase of wound healing, the inflammatory phase, presents itself as erythema, swelling, and warmth, and is often associated with pain [5]. In the late inflammatory phase, monocytes converted in the tissue to macrophages, which digest and kill bacterial pathogens, scavenge tissue debris and destroy remaining neutrophils. The subsequent proliferative phase is dominated by the formation of granulation tissue and epithelialization. Its duration is dependent on the size of the wound. Collagen levels rise continually for approximately three weeks. The amount of collagen secreted during this period determines the tensile strength of the wound. The final phase of wound healing is wound remodeling, including a reorganization of new collagen fibers, to form more organized lattice structure that progressively continues to increase wound tensile strength [6].

The objective in wound management is to heal the wound in the shortest time possible, with minimal pain, discomfort, and scarring to the patient. At the site of wound closure a

flexible and fine scar with high tensile strength is desired. Understanding the healing process and nutritional influences on wound outcome is critical to successful management of wound patients. Therefore, the present research is towards exploring scar and wound healing properties of an ayurvedic formulation.

2. Materials and methods

2.1. Ayurvedic formula

The Ayurvedic ointment formulation used contains Jasat Bhasma (20.00%), Gandhak (7.00%), Tankankhar (2.00%), Ras Kapoor (0.10%), Base (q.s.).

2.2. Animals

Healthy Albino rats weighing 150-200 g were used for the study. They were individually housed and maintained on normal food and water ad libitum. Animals were periodically weighed before and after the experiment. The Ethics Committee for animal experimentation approved the study.

2.2 Preparation of wound site by excision




Figure 1. Comparison of wound site by excision wound model in control, Standard and Test group

wound model

The wound site was prepared following the excision wound model [7]. Three groups of five animals each were taken. The rats were anaesthetized prior to and during infliction of the experimental wounds. The surgical interventions were carried out under sterile conditions using diethyl ether. A wound was made on dorsal thoracic region (500 sq. mm). Animals were closely observed for any infection and those which showed signs of infection were separated and excluded from the study and replaced. The animal were observed for wound closure and for period of epithelialisation at the interval of 5, 10 and 15 days.

2.3. Incision wound model

Albino rats (150-200 g) were selected for studies and grouped to three, each containing five animals. The rats were anaesthetized prior to and during creation of the wounds, with diethyl ether. The dorsal fur of the animals was shaved with an electric clipper. A longitudinal paravertebral incision of 6 cm long was made through the skin and cutaneous tissue on the back [8]. After the incision, the parted skin was sutured 1 cm apart using a surgical thread and curved needle. The wounds were left undressed [9]. Formulation was topically applied to the wound once a day. The sutures were removed on the 8th day post wound and continued the application of the formulation. The skin-breaking strength was measured by the method of Lee [10] on the 10th day evening after the last application.

2.4. Statistical analysis

Results, expressed as mean \pm SE were evaluated using the t-test. Values of $p < 0.001$ were considered statistically significant

2.5 Histopathological study

The healing tissues obtained on the 10th day from all three groups of animals of the

incision wound model were processed for histological study. The amount of collagen was quantified using Vangeison stain.

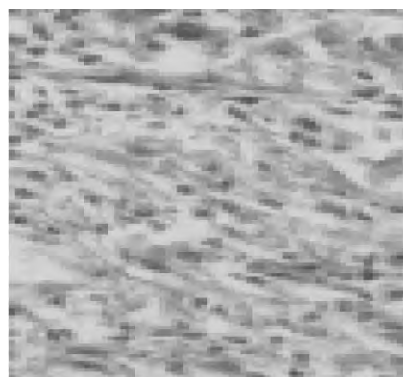


Figure 2.1. Granulation tissue of group 1 animal (control) showing with less collagen and more macrophages (Vangeison stain).




Figure 2.2. Granulation tissue of group 2 (standard) animal showing moderate deposition collagen (Vangeison stain).




Figure 2.3. Granulation tissue of group 3 animal showing more collagen and less macrophages (Vangeison stain).

Table 1. Effect of ayurvedic formulation on healing of excision wound model.

Group	Wound area (mm ²) Post wounding days				Period of epithelialisation
	0	5	10	15	
Control	502.6±5.37 (0.0)	412.83±15.05 (17.86)	304.66±10.82 (39.38)	191.83±9.803 (61.83)	26.26±0.40*
Standard	506.5±5.51 (0.0)	294.5±17.30 (41.85)	304.66±10.82 (39.38)	1.003±0.82 (99.80)	20.03±0.39*
Ayurvedic formulation	513.3±4.6* (0.0)	399.66±6.86* (21.68)	194.33±7.75* (61.92)	49.66±4.41* (90.269)	23.17±0.54*

Values are expressed as mean±SEM; n =animals in each group- 5; no in parenthesis indicates percentage of wound contraction;* $p \leq 0.001$ when compared to control group.

3. Results

In both of the models studied, significantly improved wound-healing activity was observed with the prepared ayurvedic ointment, compared to that of the reference standard and control group of animals. In the excision wound model, marketed formulation treated animals showed a significant reduction in the wound area ($p < 0.001$), faster rate of epithelialisation (Table 1), increased dry weight of the tissue ($p < 0.001$) and increased hydroxyproline content ($p < 0.001$) when compared with the control group. Table 2 depicts the wound healing effect of marketed formulation in the incision wound model.

The treated animal's demonstrated significant skin-breaking strength when compared to control animals. A significant increase in the weight of the granulation tissue ($p < 0.001$) and hydroxyproline ($p < 0.001$) content were observed in animals treated with the ayurvedic formulation when compared to the control group. Histological studies of the tissue obtained from the treated (Figure 2.3) group showed a significant increase in collagen deposition, few macrophages, tissue edema and more fibroblasts. It was more or less equal to the animals treated with (0.2% w/w nitro-furazone (Figure 2.2). The wound healing was more significant in treated group of animals.

4. Discussion

Wound healing is a process by which a damaged tissue is restored as closely as possible to its normal state and wound

contraction is the process of shrinkage of area of the wound. It mainly depends on the repairing ability of the tissue, type and the extent of damage and general state of the health of the tissue. The granulation tissue of the wound is primarily composed of fibroblast, collagen, edema, and small new blood vessels. The undifferentiated mesenchymal cells of the wound margin modulate themselves into fibroblast, which start migrating into the wound gap along with the fibrin strands. The collagen composed of amino acid (hydroxyproline) is the major component of extra cellular tissue, which gives strength and support. Breakdown of collagen liberates free hydroxyproline and its peptides; measurement of the hydroxyproline could be used as an index for collagen turnover.

5. Conclusion

The formulation promotes wound-healing activity. It showed remarkable wound healing activity and it may be suggested for treating various types of wounds in human beings. Further studies with purified constituents are needed to understand the complete mechanism of wound healing activity.

Table 2. Effect of ayurvedic formulation on tensile strength of resutured incision wound on the 10th day post wounding.

Group	Tensile strength (gm)
Control	277.86±03.19
Standard	497.13±06.06***
Ayurvedic formulation	420.33±5.92***

Values are expressed as mean±SEM; n =animals in each group-5; *** $p \leq 0.001$ when compared to control group.

References

- [1] Natarajan V, Venugopal PV, Menon T. Effect of azadirachta (neem) on the growth pattern of dermatophytes. *Indian J Med Microbiol* 2003; 21: 98-101.
- [2] Singh A, Singh DK. Molluscicidal activity of *Lawsonia inermis* and its binary and tertiary combinations with other plant derived molluscicides. *Indian J Exp Biol* 2001; 39: 263-8.
- [3] Tuhin KB. Plant medicines of Indian origin for wound healing activity: a review. *Int J Lower Extrem Wounds* 2003; 2: 25-39.
- [4] Douglas M, Alan L, Miller ND. Nutritional support for wound healing. *Alt Med Rev* 2003; 8: 359-77.
- [5] Stadelmann WK, Digenis AG, Tobin GR. Impediments to wound healing. *Am J Surg* 1998; 176: 39S-47S.
- [6] Stadelmann WK, Digenis AG, Tobin GR. Physiology and healing dynamics of chronic cutaneous wounds. *Am J Surg* 1998; 176: 26S-38S.
- [7] Opara IC. A preliminary investigation into the antiemetic properties of the leaf extract of *Ocimum gratissimum* D.V.M. Project submitted to the Faculty of Veterinary Medicine, University of Nigeria, Nsukka, 1999.
- [8] Ehrlich HP, Hunt TK. Effect of cortisone and vitamin A on wound healing. *Ann Surg* 1968; 167: 324-8.
- [9] Hukkeri VI, Nagathan CV, Karadi RV, Patil BS. Antipyretic and wound healing activities of *moringa oleifera* lam. in rats. *Indian J Pharm Sci* 2006; 68: 124-6.
- [10] Lee KH. Studies on mechanism of action of salicylates II. retardation of wound healing by aspirin. *J Pharm Sci* 1968; 57: 1042-3.

