



The Effect of *Elaeagnus angustifolia* L. Cream on Radiation-Induced Skin Reactions in Women with Breast Cancer; A Preliminary Clinical Trial

Jamshid Salamzadeh^a, Mohammad Kamalinejad^b, Bahram Mofid^c, Seyed Alireza Mortazavi^d, Alireza Sheikhlari^b, Mohammad Babaeian^{b*}

^a Department of Pharmacotherapy, School of Pharmacy, Shahid Beheshti University of Medical Sciences, Tehran, Iran.

^b School of Pharmacy, Shahid Beheshti University of Medical Sciences, Tehran, Iran.

^c Department of Radiotherapy, Shohada-e-Tajrish Hospital, Shahid Beheshti University of Medical Sciences, Tehran, Iran.

^d Department of Pharmaceutics, School of Pharmacy, Shahid Beheshti University of Medical Sciences, Tehran, Iran.

Abstract

Radiotherapy, a highly effective way to destroy breast cancer, causes skin adverse effects. A considerable amount of studies have been conducted to find a way to alleviate or relieve dermal adverse effects of radiation. The aim of this study was to observe the clinical effect of *Elaeagnus angustifolia* L. cream to treat radiotherapy-induced skin destruction in breast cancer patients. Thirty two patients suffering from different stages of radiotherapy-induced skin reactions were evaluated in a double-blind randomized study; 16 patients in the treatment group received *Elaeagnus angustifolia* cream, while the other 16 patients, served as control group. Two weeks after the treatment, patients in *Elaeagnus angustifolia* group showed significantly lower skin reaction grade compared with placebo group. The attitude of the patients of *Elaeagnus angustifolia* group about dryness, itching, pain, burning, blisters and sores was significantly improved after two weeks of treatment. *Elaeagnus angustifolia* cream may effectively reduce the radiotherapy-induced dermal injury.

Keywords: *Elaeagnus angustifolia*, Breast cancer, Radiotherapy, Skin reaction, Russian olive, Radiation

1. Introduction

The number of people living with, and dying of, breast cancer across the world is quite shocking. It is the most commonly

diagnosed cancer and also a major health problem among women in both developing and developed countries. In Iran, it seems to be more serious, because it affects women at

Corresponding Author: Mohammad Babaeian, School of Pharmacy, Shahid Beheshti University of Medical Sciences, Tehran, Iran.

Tel: +98-218-887-3704

E-Mail: babaeianm@gmail.com

Cite this article as: Salamzadeh J, Kamalinejad M, Mofid B, Mortazavi A, Sheikhlari A, Babaeian M, The Effect of *Elaeagnus angustifolia* L. Cream on Radiation-Induced Skin Reactions in Women with Breast Cancer; A Preliminary Clinical Trial. Iranian Journal of Pharmaceutical Sciences, 2017, 13 (2): 25-36.

least one decade younger compared with their counterparts in developed countries [1, 2].

Radiotherapy, a highly effective way to destroy breast cancer, causes skin morbidity including erythema, dry desquamation, itching, and skin breakdown (or moist desquamation) in the treatment area. Several standard skin care recommendations are currently being made for patients suffering from radiotherapy-induced skin toxicity, such as washing the treated area with tepid water and a unscented soap, using slip-on and light cotton clothes, limiting friction, scratching or rubbing the area, keeping it dry and avoiding from sun exposure, extreme heat, cold, vigorous cleansers, creams, or any other irritant agent [3-7]. A considerable amount of studies have been conducted to find a way to alleviate dermal adverse effects of radiation, and nowadays hydrocolloid dressings, gentian violet, salt water bathing, hydrogen peroxide [6, 8, 9], *Aloe vera* [4, 7, 10, 11], trolamine [3], hyaluronic acid [12], sucralfate [13], calendula [5], topical corticosteroids [14-16] and antibiotics [17, 18] are recognized as relatively effective solutions.

Although many different treatments have been suggested, any consensus on the

preferred treatments for radiation-induced skin toxicity has not been reached [19]. Furthermore, in view of the increasing application of radiotherapy [20] and the burgeoning cost of managing patients, effective drugs for treatment of radiation-induced skin reactions (RISR) are still in great demand.

In folk medicine, *Elaeagnus angustifolia* L. (EA) has had many medical indications such as: dysentery, nausea, vomiting, jaundice, asthma and flatulence [21] and it is known for its analgesic and anti-inflammatory properties [22]. EA fruits have long been using in Iran as an analgesic agent for the alleviation of pain in osteoarthritis [22, 23]. Decoction and infusion of its fruits are considered as useful for fever, jaundice, asthma, tetanus and osteoarthritis [22, 24-27]. A clinical study showed remarkable efficacy of EA to relieve pain and inflammation in osteoarthritis [28]. The ripe fruits of EA have been used to treat amoebic dysentery [29]. Moreover in Turkish traditional medicine, a mixture of EA fruits and olive oil is administered to gastric disorders [30].

Available literature shows that the fruits of EA have anti-pyretic, anti-ulcerogenic, anti-nociceptive, anti-inflammatory and antibacterial effect [22, 27, 30-32]. Several studies have demonstrated that EA fruit extract accelerates wound healing in rats [33]. Bucur et al. have shown that a dermatological preparation of EA flowers soft extract had a superior activity than a control on rabbit scarred skin [34].

In the light of the above, we felt a great need for a preliminary randomized double-blinded placebo-controlled clinical trial to evaluate the possible relieving effects of *Elaeagnus angustifolia* fruit on radiotherapy-induced skin reactions. The current study has been designed and carried out in women with breast cancer who received radiotherapy and suffered from skin toxicity.

2. Material and Method

2.1. Plant Materials

The fruits were collected from Qazvin province, Iran at the end of May 2011 and identified by a specialist (M. Kamalinejad) in the medicinal plants laboratory of Shahid Beheshti pharmacy school.

The fruits were washed and dried in shade, at room temperature. 1000 grams of the ground fruits were sunk in 5000 ml of boiling water and boiled for 20 min according to a previous studie [22]. The mixture was filtered. The aqueous solution was concentrated and dried on an 85° C water bath.

2.2. Preparation of the Cream

Hydrophilic part (including EA extract, glycerin, water and tween) and lipophilic part (including isopropyl myristate, Vaseline and stearyl alcohol) were separately heated to 75° C and then were mixed. The mixture was stirred and allowed to reach room temperature.

2.3. Trial Organization

The trial was designed according to a double blind, case control study which was

performed in Shohadaye Tajrish Educational Hospital (Tehran, Iran) during February 2012 to August 2012. The patients were informed about the main rationale of the study, and patient provided a written informed consent for the participation. The research protocol was carried out in accordance with the Declaration of Helsinki and subsequent revisions, and approved by the ethics committee of Shahid Beheshti University of Medical Sciences. The trial was registered in Iranian Registry of Clinical Trials under code: IRCT2013092414760N1.

2.4. Study Protocol

Before enrolment, all patients underwent an initial screening assessment including medical history, physical examination and measurements of vital signs. 32 female patients (aged 42.1 ± 3.1 years) with breast cancer, who received radiotherapy, participated in the study. The patients were randomly divided into two groups (placebo and EA) using a balanced randomization method. Age of all patients was above 18 years and their life expectancy was at least 12 weeks. Exclusion criteria included pregnancy, lactation, infection in the affected area, connective tissue problems and sensitivity to EA or any other component of the creams. Radiotherapy-induced skin reactions in these patients were monitored during intervention. To avoid potential interferences with radiotherapy process, application of the EA and placebo creams were started after the end of radiotherapy. Intervention was started after

radiotherapy courses for two weeks. Patients applied the cream twice a day (morning and evening) on the affected area. The patients were informed to use slip-on clothing and not to use other creams and topical preparations on the affected area (Figure 1).

2.5. Outcomes

To assess the efficacy and tolerance, patients were given a detailed dictionary of standard terms diaries and asked to note incidence and severity of symptom and stayed in contact with the hospital and nursery staff. General condition of the patients, menopausal status, age, location of tumor (medial, central or lateral), location of tumor (left or right), stage of disease (TNM stages) [35], number of chemotherapy sessions before radiotherapy, total radiation dose, radiation doses when skin reactions started, concurrent medications, clinical examination and skin reactions grade were determined as main parameters of the study. An independent physician assessed the

radiation-induced skin toxicity grade in accordance with the Canadian Cancer Society Research Institute criteria. The scores were in the range of 0 to 4 (0 for normal skin, 1 for faint erythema, dry desquamation and dry skin, 2 for moderate to brisk erythema, patchy moist desquamation mostly confined to skin folds and creases and moderate edema, 3 for confluent, moist desquamation other than skin folds and pitting edema and 4 for ulceration, hemorrhage, necrosis, infection, cellulitis and exudation) [6]. In addition, patients were asked to answer 4-point rating scale questions about dry skin, itching, pain, burning, sores and blisters ranging from 0-3 (0: absent, 1: mild, 2: moderate and 3: severe). At the end of the study, the attitude of the patients was assessed using a question which rated from -3 to 2 (-3: completely decreased, -2: markedly decreased, -1: relatively decreased, 0: no change, 1: relatively increased and 2: markedly increased).

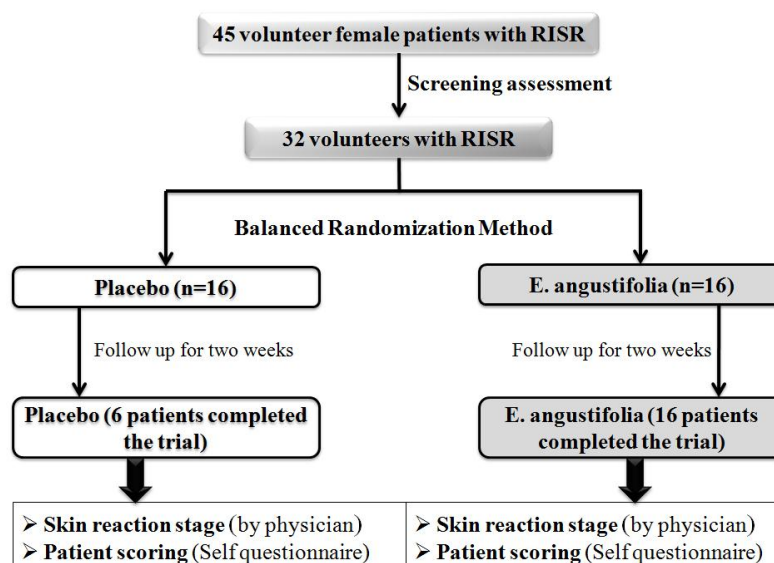


Figure 1. Trial profile.

Table 1. Distribution of baseline characteristics.

	Age	Tumor location		Tumor location			Mastectomy		Chemotherapy sessions
		L	R	C	L	M	+	-	
Placebo	41.8 ± 9.9	66.7	33.3	33.4	66.7	0	100	0	7.7 ± 0.33
E. angustifolia	5.13 ± 5.13	50	50	37.5	62.5	0	75	25	7.0 ± 0.61

Table 2. TNM staging; Primary Tumor (T); TX: Primary tumor cannot be evaluated, T0: No evidence of primary tumor, Tis: Carcinoma in situ, T1, T2, T3, T4: Size and/or extent of the primary tumor Regional Lymph Nodes (N); NX: Regional lymph nodes cannot be evaluated, N0: No regional lymph node involvement, N1, N2, N3: Degree of regional lymph node involvement (number and location of lymph nodes) Distant Metastasis (M); MX: Distant metastasis cannot be evaluated, M0: No distant metastasis, M1: Distant metastasis is present.

	T Stage (%)							N Stage (%)					Distant metastasis (%)		
	TX	T0	Tis	T1	T2	T3	T4	NX	N0	N1	N2	N3	MX	M0	M1
Placebo	0	0	0	33.33 ±0.33	33.33 ±0.33	33.33 ±0.33	0	0	66.66 ±0.33	0	33.33 ±0.33	0	0	16.66 ±0.22	83.33 ±0.5
E. angustifolia	0	0	0	50 ±0	25 ±0	25 ±0	0	0	75 ±0	0	25 ±0	0	0	12.5 ±0.5	87.5 ±0.5

2.6. Statistical Analysis

Values of age and number of chemotherapy sessions were expressed as mean ± SEM, and data between groups were compared using Mann-Whitney U test after testing to assess the distribution normality. To compare skin reaction parameters (dryness, itching, pain, burning, blister and sores) and stage of disease between two groups, chi square test was used. A value of P < 0.05 was considered as statistically significant. Due to the patient's complications, non-compliant cases in the placebo group and ethical issues, it was not possible to study a larger number of patients.

3. Results and Discussion

3.1. Baseline Characteristics

Twenty two participants completed the study. The patients who finished the study did

not modify their diets, drug regimens and life styles along the study. Any significant differences were not observed in the baseline of age, menopausal status, tumor location (Table 1), TNM stages and having mastectomy between two groups (P > 0.05). Number of chemotherapy sessions was significantly lower in EA group (P < 0.05; Table 2).

3.2. Skin Reaction Grade

Skin reaction grade -assessed by the independent physician- before treatment was not significantly different between two groups (P > 0.05). Two weeks after the treatment, patients in EA group showed significantly lower skin reaction grade compared with placebo group (P < 0.05).

3.3. Dryness and Itching

The skin of all patients in the placebo group was dry and itchy before receiving placebo. By applying the placebo, dryness and itching were decreased markedly in 33.33%, increased relatively in 16.6%, increased markedly in 33.33% and did not change in 16.6%.

At the beginning of the study, 87.5 % of patients in EA group suffered from dry and itchy skin. After using the EA cream for two weeks, the symptoms were completely disappeared in 78.5 %, decreased markedly in 7.14 % and reduced relatively in 14.2 % of the patients (Figure 2).

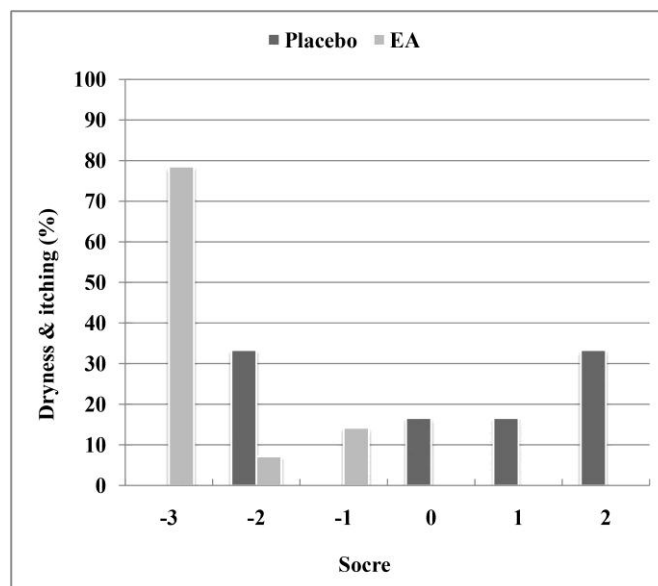


Figure 2. Attitude of the patients after treatment about dryness & itching (%).

3.4. Pain and Burning

All patients had pain and burning (100 %). After using EA cream, the pain and burning were decreased completely in 62.5 %, decreased markedly in 18.7 %, increased relatively in 6.3% and in 12.5% markedly

increased. While, pain and burning were decreased markedly in 16.6% and increased markedly in 83.3% of patients in placebo group (Figure 3).

3.5. Blister and Sore

In EA group, 62.5 % of the patients were suffering from blisters and sores. After using the cream, sores and blisters decreased completely in 30 %, decreased markedly in 40 % and decreased relatively in (10 %). In 1 person, the severity of the blisters and sores increased relatively and in 1 other patient blisters and sores increased markedly. 66.6 % of the patients in the placebo group, suffered

from blisters and sores, and after using the placebo cream, blisters and sores in 50% increased relatively and increased markedly in the other 50 % (Figure 4). One patient in placebo group who had no sores or blisters,

developed sores and blisters that increased gradually during the treatment.

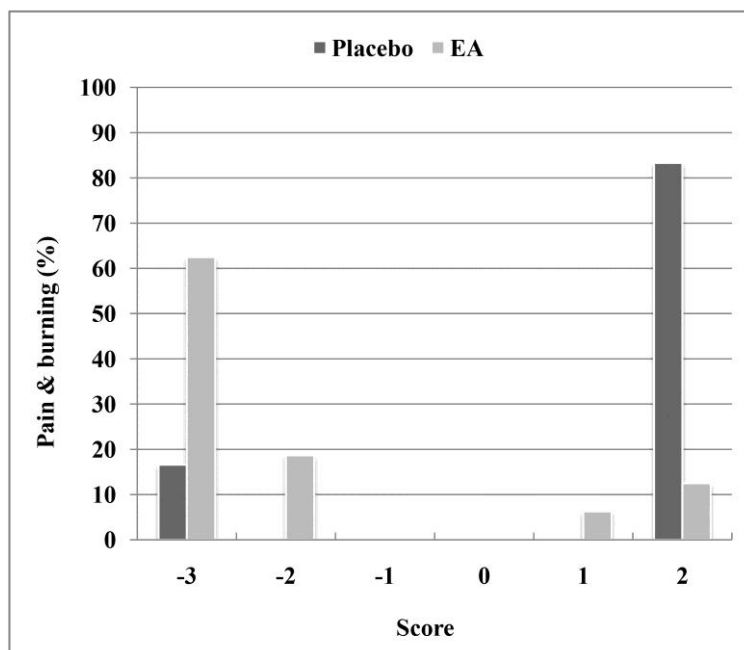


Figure 3. Attitude of the patients after treatment about pain & burning (%).

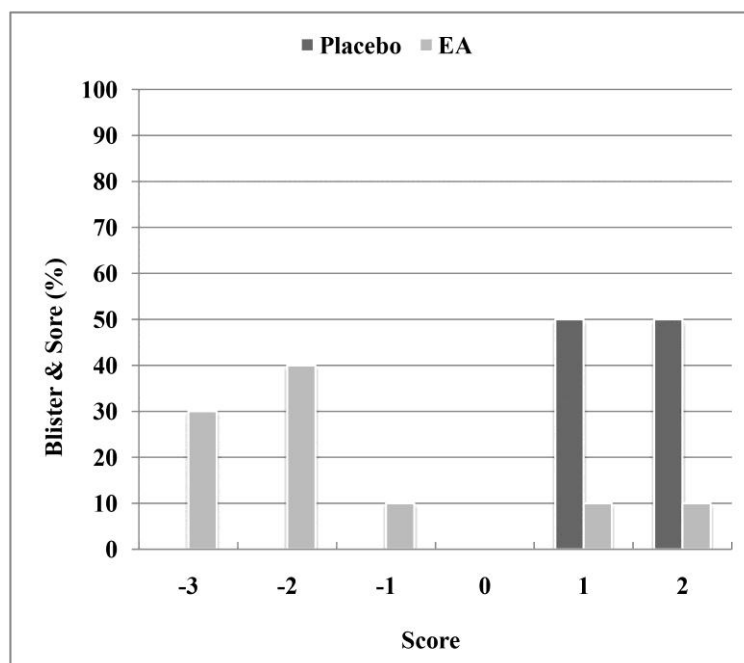


Figure 4. Attitude of the patients after treatment about blisters & sores (%).

3. 6. Discussion

In the present randomized double-blinded placebo-controlled preliminary clinical trial, we have shown that *Elaeagnus angustifolia* cream may be able to repair skin reactions induced by radiotherapy. All the signs of skin toxicity including pain, burning, itching, dryness, sores and blisters were significantly decreased in the EA group compared with placebo group. Furthermore, according to the entries of the patient diaries and their responses to the questions, patients in EA group were satisfied with the treatment. In the meantime, our findings clearly show that this formulation did not cause any adverse effects.

According to previous studies, aqueous extract of EA has a potent anti-inflammatory effect [22]. It has been recently shown that EA extract can attenuate pain and inflammation caused by formalin in mice. Effectiveness of extract was comparable with the ability of indomethacin and dexamethasone [36]. Ahmadiani et al. have reported that 1000 mg/kg (i.p.) of EA fruit extract had the same efficacy as 300 mg/kg (i.p.) of Sodium salicylate in reducing chronic pain and inflammation [22]. Earlier phytochemical experiments have shown that EA fruits extract consist of several flavonoids, such as kaempferol, and terpenoids [22]. It has been well established that flavonoids and most of terpenoids have anti-inflammatory effects [37, 38]. Among possible candidates, flavonoids and terpenoids can also be responsible for analgesic effects of EA [22, 39]. Past studies have indicated that aglycone and glycoside

forms of flavonoids would penetrate considerably into the inflamed tissues, so that they can penetrate into the deep layers of the skin very well [40, 41].

Moreover, several series of evidences have indicated that aqueous extract of EA accelerates cutaneous wound healing [33]. Moezzi et al. have reported 500 mg/day of EA extract is equivalent to 500 mg/day of silver sulfadiazine (1 %) cream in repairing wound [42].

Antibacterial properties of EA extract can be another reason for its beneficial effects on radiotherapy-induced skin reactions [32].

4. Conclusion

In conclusion, the data presented here imply that applying *Elaeagnus angustifolia* cream on the affected area can significantly cure skin toxicity related to radiotherapy. More investigations to explore the possible prophylactic efficacy of this formulation and involving mechanisms are necessary.

Acknowledgments

We would like to acknowledge Dr. Houman Alimoradi, Dr. Sameh Mortaz Hejri and Dr. Abdolhamid Parsa for their help and valuable suggestions.

References

- [1] S.A. Bidgoli, R. Ahmadi, M.D. Zavarhei, Role of hormonal and environmental factors on early incidence of breast cancer in Iran, *Sci Total Environ* 408(19) (2010) 4056-4061.
- [2] P. Yavari, M. Mosavizadeh, B. Sadrol-Hefazi, Y. Mehrabi, Reproductive characteristics and the risk of

- breast cancer - A case-control study in Iran, *Asian Pacific Journal of Cancer Prevention* 6(3) (2005) 370-375.
- [3] J. Fisher, C. Scott, R. Stevens, B. Marconi, L. Champion, G.M. Freedman, F. Asrari, M. Pilepich, J.D. Gagnon, G. Wong, Randomized phase III study comparing Best Supportive Care to Biafine as a prophylactic agent for radiation-induced skin toxicity for women undergoing breast irradiation: Radiation Therapy Oncology Group (RTOG) 97-13, *International Journal of Radiation Oncology* Biology* Physics* 48(5) (2000) 1307-1310.
- [4] S. Heggie, G.P. Bryant, L. Tripcony, J. Keller, P. Rose, M. Glendenning, J. Heath, A Phase III study on the efficacy of topical aloe vera gel on irradiated breast tissue, *Cancer Nurs* 25(6) (2002) 442-451.
- [5] F. Pommier P Fau - Gomez, M.P. Gomez F Fau - Sunyach, A. Sunyach Mp Fau - D'Hombres, C. D'Hombres A Fau - Carrie, X. Carrie C Fau - Montbarbon, M. X, Phase III randomized trial of *Calendula officinalis* compared with trolamine for the prevention of acute dermatitis during irradiation for breast cancer, *J Clin Oncol* 22(8) (2004) 1447-53.
- [6] E. Szumacher, A. Wighton, E. Franssen, E. Chow, M. Tsao, I. Ackerman, L. Andersson, J. Kim, A. Wojcicka, Y. Ung, K. Sixel, C. Hayter, Phase II study assessing the effectiveness of Biafine cream as a prophylactic agent for radiation-induced acute skin toxicity to the breast in women undergoing radiotherapy with concomitant CMF chemotherapy, *International Journal of Radiation Oncology* Biology* Physics* 51(1) (2001) 81-86.
- [7] M.S. Williams, M. Burk, C.L. Loprinzi, M. Hill, P.J. Schomberg, K. Nearhood, J.R. O'Fallon, J.A. Laurie, T.G. Shanahan, R.L. Moore, Phase III double-blind evaluation of an aloe vera gel as a prophylactic agent for radiation-induced skin toxicity, *International journal of radiation oncology, biology, physics* 36(2) (1996) 345-349.
- [8] K. Hassey, C. Rose, Altered skin integrity in patients receiving radiation therapy, *Oncology nursing forum*, 1982, p. 44.
- [9] S.G. Margolin, J.C. Breneman, D.L. Denman, P. LaChapelle, L. Weckbach, B.S. Aron, Management of radiation-induced moist skin desquamation using hydrocolloid dressing, *Cancer Nurs* 13(2) (1990) 71-80.
- [10] D.J. Dudek, J. Thompson, M.M. Meegan, T.R. Haycocks, C. Barbieri, L.A. Manchul, Pilot study to investigate the toxicity of Aloe vera gel in the management of radiation induced skin reactions for post-operative primary breast cancer, *Journal of Radiotherapy in Practice* 1(04) (1999) 197-204.
- [11] D.L. Olsen, W. Raub Jr, C. Bradley, M. Johnson, J.L. Macias, V. Love, A. Markoe, The effect of aloe vera gel/mild soap versus mild soap alone in preventing skin reactions in patients undergoing radiation therapy, *Oncology nursing forum*, 2001, p. 543.
- [12] V. Liguori, C. Guillemin, G.F. Pesce, R.O. Mirimanoff, J. Bernier, Double-blind, randomized clinical study comparing hyaluronic acid cream to placebo in patients treated with radiotherapy, *Radiotherapy and Oncology* 42(2) (1997) 155-161.
- [13] M. Wells, M. Macmillan, G. Raab, S. MacBride, N. Bell, K. MacKinnon, H. MacDougall, L. Samuel, A. Munro, Does aqueous or sucralfate cream affect the severity of erythematous radiation skin reactions? A randomised controlled trial, *Radiotherapy and Oncology* 73(2) (2004) 153-162.
- [14] J.J. Yohn, W.L. Weston, Topical corticosteroids, in Weston WL (ed): *Current Problems in Dermatology*, Year Book Medical, Chicago, 1990.
- [15] A. Bostrom, H. Lindman, C. Swartling, B. Berne, J. Bergh, Potent corticosteroid cream (mometasone furoate) significantly reduces acute radiation dermatitis: results from a double-blind, randomized study, *Radiother Oncol* 59(3) (2001) 257-265.
- [16] M. Schmuth, M.A. Wimmer, S. Hofer, A. Sztankay, G. Weinlich, D.M. Linder, P.M. Elias, P.O. Fritsch, E. Fritsch, Topical corticosteroid therapy for acute radiation dermatitis: a prospective, randomized, double-blind study, *Br J Dermatol.* 146(6) (2002) 983-91.

- [17] A. Korinko, A. Yurick, Maintaining skin integrity during radiation therapy, *Am J Nurs* 97(2) (1997) 40-44.
- [18] C.T. Spann, W.D. Tutrone, J.M. Weinberg, N. Scheinfeld, B. Ross, Topical antibacterial agents for wound care: a primer, *Dermatol Surg* 29(6) (2003) 620-6.
- [19] M. Moolenaar, R. Louwrens Poorter, P. Paulus Gerardus Van Der Toorn, A. Willem Lenderink, P. Poortmans, A. Cornelis Gerardus Egberts, The effect of honey compared to conventional treatment on healing of radiotherapy-induced skin toxicity in breast cancer patients, *Acta Oncologica* 45(5) (2006) 623-624.
- [20] J.F. Fowler, The radiobiology of prostate cancer including new aspects of fractionated radiotherapy, *Acta Oncologica* 44(3) (2005) 265-276.
- [21] H. Mirhydar, *Encyclopedia of Plants: Indications of Plants in the Prevention and Treatment of Diseases*, Islamic Farhang, Tehran, 1998.
- [22] A. Ahmadiani, J. Hosseiny, S. Semnianian, M. Javan, F. Saeedi, M. Kamalinejad, S. Saremi, Antinociceptive and anti-inflammatory effects of *Elaeagnus angustifolia* fruit extract, *Journal of Ethnopharmacology* 72(1-2) (2000) 287-292.
- [23] H. Hosseinzadeh, M. Ramezani, N. Namjo, Muscle relaxant activity of *Elaeagnus angustifolia* L. fruit seeds in mice, *Journal of Ethnopharmacology* 84(2-3) (2003) 275-278.
- [24] M. Momen Hosseini, Tohfeh Hakim Momen, Mahmoudi Publication, Tehran, 1981.
- [25] Avicenna, *The Canon of Medicine*, 5 ed., Soroush Publication, Tehran, 1991.
- [26] A. Ansari Shirazi, Ekhtiyarat Badii, Razi Publication, Tehran 1991.
- [27] A. Zargari, *Medicinal Plants*, Tehran University Press, Tehran, 1990.
- [28] G.H. Alishiri, A. Ahmadiani, N. Bayat, M. Kamalinejad, A. Salimzadeh, S. Saremi, M. Miri, A.A. Noudeh, Efficacy of *Elaeagnus Angustifolia* Extract in Treatment of Osteoarthritis of Knee: A Randomized Double-Blind Placebo-Controlled Trial, *Kowsar Medical Journal* 12(1) (2007) 49-57.
- [29] L. Perry, *Medicinal Plants of the East and Southeast Asia*, MIT Press, London, 1980.
- [30] İ. Gürbüz, O. Üstün, E. Yesilada, E. Sezik, O. Kutsal, Anti-ulcerogenic activity of some plants used as folk remedy in Turkey, *J Ethnopharmacol* 88(1) (2003) 93-97.
- [31] Q. Wang, X. Ruan, J.-H. Huang, N.-y. Xu, Q.-c. Yan, Intra-specific genetic relationship analyses of *Elaeagnus angustifolia* based on RP-HPLC biochemical markers, *Journal of Zhejiang University Science B* 7(4) (2006) 272-278.
- [32] M. Karamedini, A. Rohani, Isolation and investigation of antimicrobial activity of total flavonoids of *Elaeagnus angustifolia*, *JOURNAL OF PHARMACY AND PHARMACOLOGY* 55 (2003) 152-152.
- [33] M. Mehrabani Natanzi, P. Pasalar, M. Kamalinejad, A.R. Dehpour, S.M. Tavangar, R. Sharifi, N. Ghanadian, M. Rahimi-Balaei, S. Gerayesh-Nejad, Effect of aqueous extract of *Elaeagnus angustifolia* fruit on experimental cutaneous wound healing in rats, *Acta medica Iranica* 50(9) (2012) 589-596.
- [34] L. Bucur, G. Taralunga, R. Alexandrescu, T. Negreanu, V. Istudor, [Evaluation of biological activity of a dermatological preparation with *elaieagnus angustifolia* flowers soft extract], *Rev Med Chir Soc Med Nat Iasi* 112(4) (2008) 1098-103.
- [35] L.H. Sobin, C.C. Compton, TNM seventh edition: What's new, what's changed, *Cancer* 116(22) (2010) 5336-5339.
- [36] S. Farahbakhsh, S. Arbabian, F. Emami, B. Rastegar Moghadam, H. Ghoshooni, A. Noroozadeh, H. Sahraei, L. Golmanesh, C. Jalili, H. Zrdooz, Inhibition of Cyclooxygenase Type 1 and 2 Enzyme by Aqueous Extract of *Elaeagnus Angustifolia* in Mice, *Basic and Clinical Neuroscience* 2(2) (2011) 31-37.
- [37] M. del Carmen Recio, R.M. Giner, S. Manez, A. Talens, L. Cubells, J. Gueho, H.R. Julien, K.

Hostettmann, J.L. Rios, Anti-inflammatory activity of flavonol glycosides from *Erythrospermum monticolum* depending on single or repeated local TPA administration, *Planta Med* 61(6) (1995) 502-4.

[38] A. Panthong, W. Tassaneeyakul, D. Kanjanapothi, P. Tantiwachwuttikul, V. Reutrakul, Anti-inflammatory activity of 5,7-dimethoxyflavone, *Planta Medica* 55(2) (1989) 133-136.

[39] M.J. Alcaraz, J.R. Hoult, Actions of flavonoids and the novel anti-inflammatory flavone, hypolaetin-8-glucoside, on prostaglandin biosynthesis and inactivation, *Biochem Pharmacol* 34(14) (1985) 2477-2482.

[40] M. Alcaraz, M. Moroney, J. Hoult, Effects of Hypolaetin-8-O-glucoside and its Aglycone in in vivo and in vitro Tests for Anti-Inflammatory agents, *Planta Medica* 55(01) (1989) 107-108.

[41] I. Merfort, J. Heilmann, U. Hagedorn-Leweke, B.C. Lippold, In vivo skin penetration studies of camomile flavones, *Pharmazie* 49(7) (1994) 509-11.

[42] N. Moezzi, H. Najafzadeh Varzi, S. Shirali, Comparing the effect of *Elaeagnus angustifolia* L. extract and *Lowsonia intermis* L. paste, with silver sulfadiazine ointment on wound healing in rat, *Iranian Journal of Medicinal and Aromatic Plants* 25(2) (2009) 253-260.

ONLINE SUBMISSION

www.ijps.ir