



Comparison between Alpha and Calendula for Healing of Third-Degree Burn in Rats

Nader Tanideh^{a,b}, Milad Yavari^c, Anahita Seddighi^{d,*}, Omid Koochi Hosseinabadi^e, Melika Farshad^f, Maral Mokhtari^g, Babak Shirazi Yeganeh^g, Akram Jamshidzadeh^h, Sajad Daneshi^{i,*}, Behrouz Nikahval^j

^a *Stem Cells Technology Research Center, Shiraz University of Medical Sciences, Shiraz, Iran.*

^b *Department of Pharmacology, School of Medicine, Shiraz University of Medical Sciences Shiraz, Iran.*

^c *Student Research Committee, Pharmacy school, Shiraz University of Medical Sciences, Shiraz, Iran.*

^d *Stem Cell & Transgenic Technology Research Center, Shiraz University of Medical Sciences, Shiraz, Iran.*

^e *Laboratory Animals Center, Shiraz University of Medical Sciences Shiraz, Iran.*

^f *Student Research Committee, Dental School, Shiraz University of Medical Sciences, Shiraz, Iran.*

^g *Department of Pathology, Shiraz University of Medical Sciences, Shiraz, Iran.*

^h *Pharmaceutical Sciences Research Center, Shiraz University of Medical Sciences, Shiraz, Iran.*

ⁱ *Stem Cells Technology Research Center, Shiraz University of Medical Sciences, Shiraz, Iran.*

^j *Department of Clinical Studies, School of Veterinary Medicine, Shiraz University, Iran.*

Abstract

In this study, we compared the effects of Calendula and Alpha ointment in the treatment of burn wounds and also compared its results with silver sulfadiazine (SSD). Seventy-five male Sprague-Dawley rats were divided into five groups, and similar burn ulcers were produced on anterior surface of thigh of rats. In the first group of rats no treatment was applied, base gel was applied topically to group II, in groups III-V, Alpha, SSD, and Calendula preparations were applied, respectively. Wound healing, contraction, and histopathological evaluation were evaluated at the end of 7, 14, and 21 days. Alpha ointment was equally effective as Calendula gel, and had better efficacy compared to SSD for all markers of wound healing at days of 7, 14, and 21. Alpha and Calendula preparations are less expensive drugs and significantly improve the quality of wound healing and scar formation and are more appropriate treatment choices than SSD. Therefore, we recommended them as alternative to SSD, especially in patients with low economical backgrounds or in those who show adverse reactions to SSD.

Key words: Alpha, Calendula, Silver sulfadiazine, wound healing, burn, Rat.

1. Introduction

Burn injuries are a major public health issue and yet there is not much that can be done to relief its symptoms [1]. It causes discomfort and it's prone to infection and other

complications [2]. Many of the popular drugs pose complications such as; adverse reaction and drug resistance, that has forced researchers to look for alternative remedies [3]. The effect of herbal medications in healing process of

Corresponding Author: Sajad Daneshi, Stem Cells Technology Research Center, Shiraz University of Medical Sciences, Shiraz, Iran

Tel: +98 917 845 0240

E-Mail: sa.daneshi@yahoo.com

Cite this article as: Tanideh N, Yavari, Seddighi A, Koochi Hosseinabadi O, Farshad M, Mokhtari M, Shirazi Yeganeh B, Jamshidzadeh A, Daneshi S, Nikahval B, Comparison between Alpha and Calendula for Healing of Third-Degree Burn in Rats. Iranian Journal of Pharmaceutical Sciences, 2017, 13 (2): 51-60.

burn injuries has been documented [4]. Herbal byproducts possess efficacy with no or less complications and are mostly inexpensive compared with synthetic drugs [5]. Many plants extract have shown to hold potent wound-healing properties [6].

Alpha is a topical ointment with ingredients extracted from Lawsonia (Lythraceae intermis). Studies have shown its healing properties in burn wounds [7, 8, 9, 10].

Calendula officinalis Linn. (Compositae) is widely used in traditional medicine as anti-inflammatory agent [11] and it has been reported to have anti-bacterial, anti-fungal, and anti-viral properties [12]. It has been reported that *Calendula* stimulates wound healing and might be effective in reducing the duration of wound healing [6, 13, 14, 15, 16].

The main chemical components of *Calendula officinalis* include steroids, terpenoids, free and esterified triterpenic alcohols, phenolic acids, flavonoids (quercetin, rutin, narcissin, isorhamnetin, kaempferol), and other active ingredients [17, 18].

In a clinical study, *Calendula* was highly effective in prevention of acute dermatitis in cancer patients who underwent irradiation [19]. It seems that *Calendula* can be effective

for managing second and third degree burns [20]. Thus, based on individual conditions the recommended doses can vary. For the first time we applied a higher dose (40%) of a *Calendula* topical gel to assess its wound healing effect on third-degree burn injuries in experimental rat model in compare to Alpha and Silver sulfadiazine (SSD).

2. Material and Methods

2.1. Materials

Ethanol, Carboxy Methyl Cellulose Sodium, Methyl Paraben Sodium and Propyl Paraben Sodium, Sodium metabisulphite, Triethanolamine and EDTA were purchased from Merck (Germany). Carbopol 934 as a gelling agent was purchased from Sigma-Aldrich, USA.

2.2. Plant Material & Preparation of Extract and Formulation

Flowering aerial parts of *Calendula officinalis* was collected during April 2014 from rural areas around Shiraz, Fars, south of Iran, and it was authenticated by Prof. Khosravi at Botany department of the faculty of sciences of Shiraz University. The plant was dried at the room temperature. Fifty gram of dried powder plant were macerated in 80% aqueous EtOH (100 ml) at room temperature for 48 hours. The extract was filtered and concentrated under reduced pressure and low temperature (40°C) on a rotary evaporator to dryness. The extract yield was 36 mg/g of dried plant.

To prepare *Calendula* gel Sodium metabisulphite, Methyl paraben sodium and

Propyl paraben sodium were dissolved in water. Gelling agent was added to it and stirred continuously till it got swollen completely. Triethanolamine was slowly added to the dispersion with continuous stirring which resulted in a stiff gel. Calendula extract was added to it and stirred for 15 min. Volume was made with water and stirred continuously till a uniform gel was formed (40%)

2.3. Animal Study

Seventy-five male Sprague-Dawley rats (180–250 g) were selected and housed in separate cages having a temperature-regulated conventional animal room at 22 ± 3 °C, 40-60% relative humidity with an artificial light cycle of 12-12 hours light/dark. The research protocol was complied with the guidelines for animal care of Shiraz University of Medical Sciences, Shiraz, Iran. All experiments were carried out under aseptic conditions in Laboratory Animal Center of Shiraz University of Medical Sciences. All efforts were made to minimize suffering during the exposure period. The rats were randomly allocated into five independent equal groups after wound induction.

2.4. Experimental Protocol

The rats were under general anesthetize 90 mg/kg/IP ketamine (GmbH, Germany), and 10 mg/kg/IP xylazine (Alfasan, Netherlands). Back of the neck was shaved, and their skin was disinfected with povidone iodine and sterile water. Third-degree burn was inflicted based on previous studies [21,

22]. Then, the rats were placed in an individual cage in order to recover. Two hour after inducing the injury, the subjects were randomly divided into five equal groups of 15. From each group five animals were selected in three different time periods (7, 14, and 21 days). Each group had subgroups including; without treatment (negative control), gel base-treated, Alpha, SSD (positive control), and Calendula treatments.

2.5. Histopathological Evaluation

Tissue samples were provided after 7, 14, and 21 day therapies for further histological assessment. All of the subjects were sacrificed under deep anesthesia, and the burn areas were removed and transferred to 10% neutral-buffered formalin until tissue processing for evaluation as described by Hosseini *et al.* with some minor modifications [23]. The minimum and maximum scores for each criterion were minus and 3+ or (3.5), respectively.

2.6. Statistical Analysis

All data were shown as mean and standard deviation (SD), and statistical analysis was performed using Mann–Whitney test (SPSS version 11.5, SPSS Inc., Chicago, IL, USA). $P < 0.05$ was considered as significant.

3. Results and Discussion

None of the animals expired during the study. Figures 1-3 show histological scores of wounds. Histopathological evaluations on days 7, 14, and 21 (figures 4-6) showed that burn healing was better in the Alpha and Calendula groups in comparison with the control group

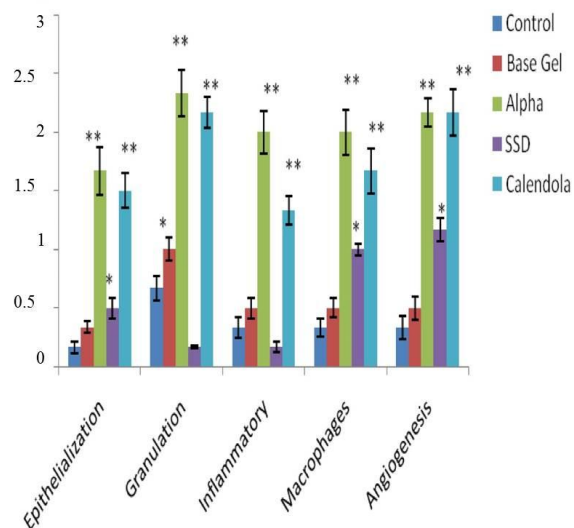


Figure 1. Histological scoring indices of wound healing activity in experimental groups on the 7th day. 0: absent; 1: mild; 2: moderate; 3: severe. Data are presented as Mean±SD (n=5).

SSD: Silver Sulfadiazine

*Significantly different as compared with control group ($P<0.05$).

**Significantly different as compared with control group ($P<0.01$).

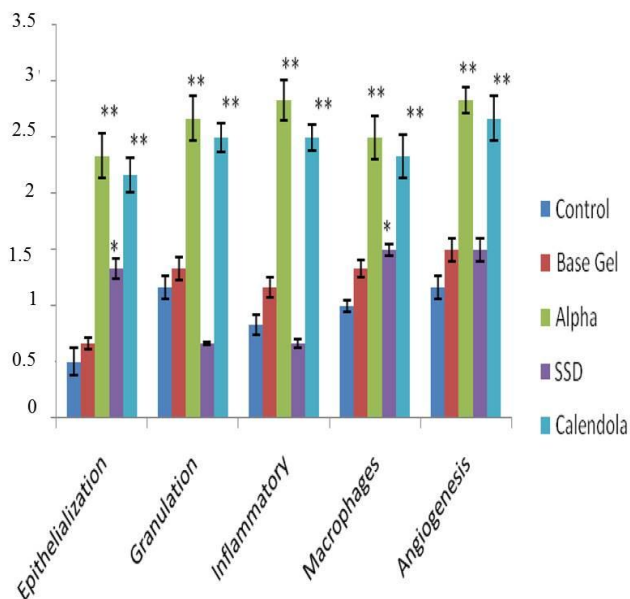


Figure 2. Histological scoring indices of wound healing activity in experimental groups on the 14th day. 0: absent; 1: mild; 2: moderate; 3: severe. Data are presented as Mean±SD (n=5).

SSD: Silver Sulfadiazine

*Significantly different as compared with control group ($P<0.05$).

**Significantly different as compared with control group ($P<0.01$).

($P < 0.01$). There was a marked infiltration of inflammatory cells, improved angiogenesis, and boosted proliferation of cells or

epithelialization due to treatment with Alpha and Calendula.

On the other hand, on days 7, 14, and 21

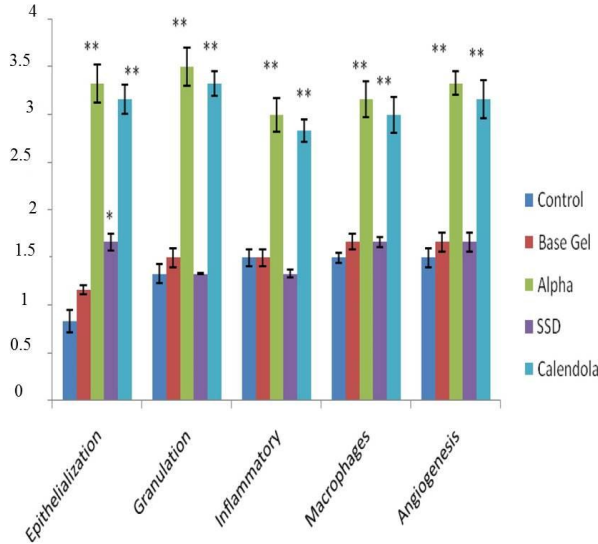


Figure 3. Histological scoring indices of wound healing activity in experimental groups on the 21th day.

0: absent; 1: mild; 2: moderate; 3: severe. Data are presented as Mean±SD (n=5).

SSD: Silver Sulfadiazine

*Significantly different as compared with control group ($P < 0.05$).

**Significantly different as compared with control group ($P < 0.01$).

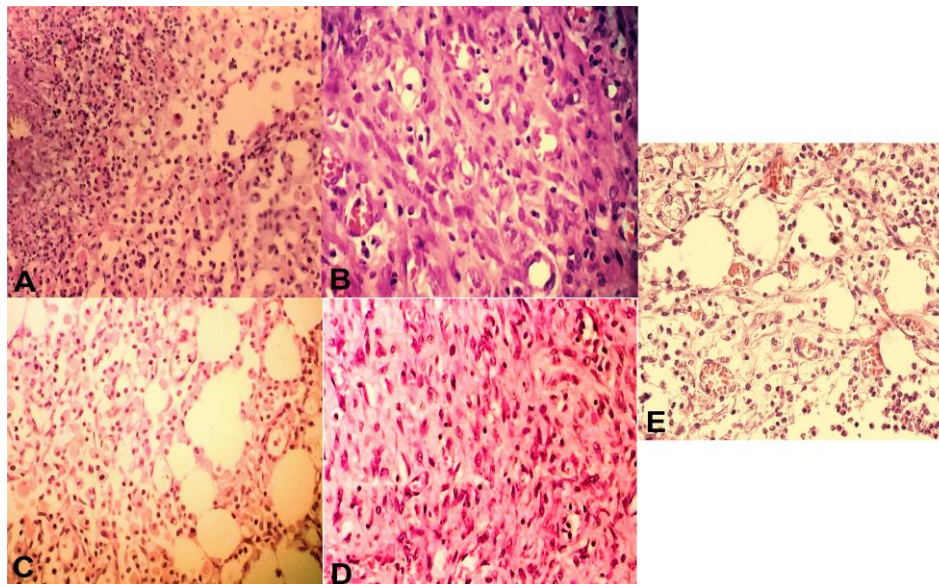


Figure 4. Microscopic appearance of burned skin on the 7th day.

Photographs of rats show infiltration of inflammatory cells in different groups.

A = Control; B = Base gel; C= Alpha; D= SSD; E= Calendula (H&E, 400×)

histological finding demonstrated that there were no significant differences between the Alpha and Calendula groups ($P>0.05$). While the best result for reepithelialization was observed on day 21 for the Alpha and Calendula groups (scores 3.5)

In fact wound healing effects of the Alpha and Calendula groups were much better in comparison with SSD group ($P<0.05$).

Wound healing is a process described by homeostasis, re-epithelialization, and granulation of tissues. Even though healing process occurs by itself without any facilitation, nevertheless numerous risk factors such as; infection and delay in healing process has attracted the attention of many researchers in this domain [24].

Silver sulfadiazine (SSD) topical ointment at 1% is the most widely used topical

treatment for burn injury [25]. Due to its antimicrobial properties it is widely used. However, its side effects have been reported in several reports such as; renal toxicity, and leukopenia. Therefore, it is not recommended that this topical ointment to be used for long duration on deep wounds [26].

L. inermis is commonly known as Hanna in Iran which is called Mehndi in India is a very popular natural dye for coloring hands and hair. *L. inermis* has been known for its medicinal values in traditional medicine. In Iran, Alpha is a new topical ointment which is used in medicine for sores, scars, blisters, and burns [27].

Hosseini *et al.* evaluated the efficacy of Alpha ointment in the treatment of *Pseudomonas* infections burn and compared its results with silver sulfadiazine. They showed

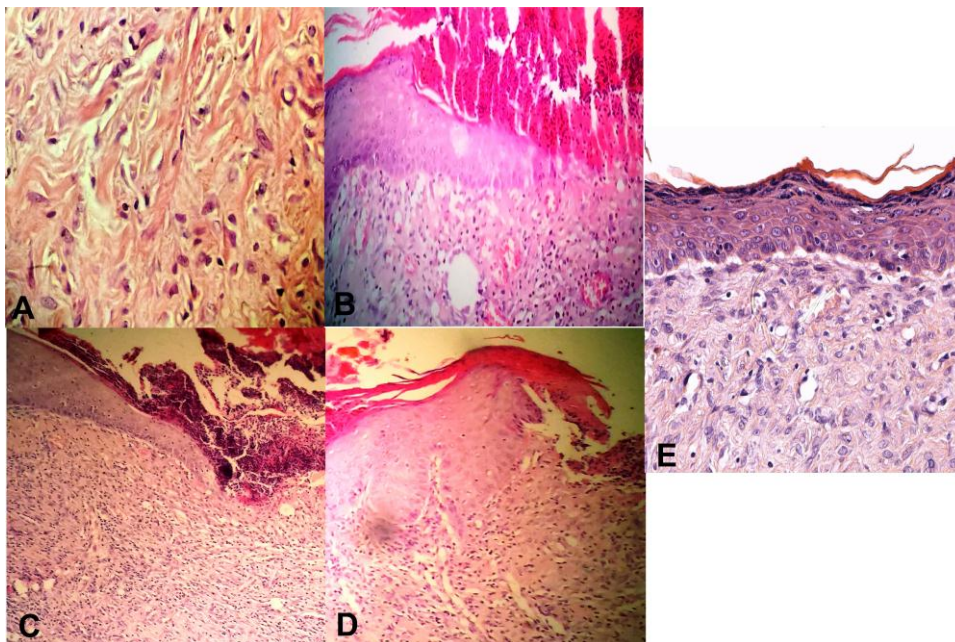


Figure 5. Microscopic appearance of burned skin on the 14th day.

Photographs of rats show proliferation of epithelial cells with Partial epithelialization in different groups.

A = Control; B = Base gel; C= Alpha; D= SSD; E= Calendula (H&E, 400×)

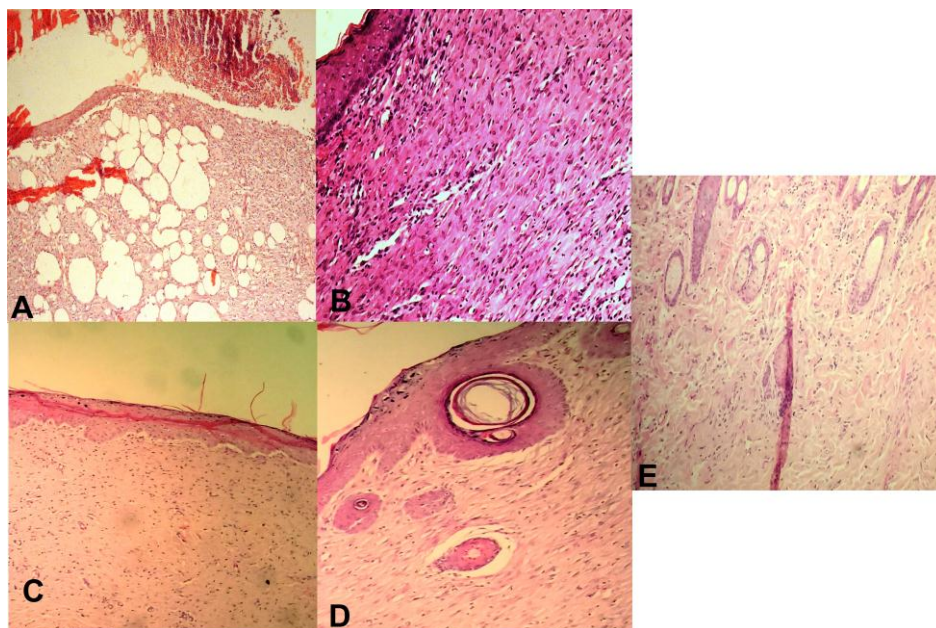


Figure 6. Microscopic appearance of burned skin on the 21th day.

Photographs of rats show completed epithelialization with dermal mature collagenization in different groups.

A = Control; B = Base gel; C= Alpha; D= SSD; E= Calendula (H&E, 400×)

that infected wounds were significantly less common in Alpha ointment group compared to SSD [23].

Calendula, also known as marigold, is used as a wound healing medicine but its mechanism is still unknown [11]. The effects of oral and topical administration of Calendula officinalis flower extract on wounds in rats were observed. This study showed the potent wound healing properties of Calendula officinalis flower extract in both rout of administration [15].

Also the effect of Calendula officinalis flower extract was examined in experimentally induced burn in rats, whose results indicated the efficiency of Calendula officinalis flower extract on increasing the antioxidant defense mechanism in order to decrease burn injury [28].

The effect of two different fractions of Calendula officinalis flowers (a hexane and an ethanolic) on fibroblasts migration and proliferation were investigated [29]. The data showed that both extracts of Calendula officinalis stimulated the proliferation and migration of fibroblasts in low concentrations.

In this study, the healing effects of Alpha and Calendula as natural products were evaluated and compared with SSD. Our findings confirmed that both Alpha and Calendula have beneficial effects on healing process after burn injuries in all evaluated parameters including gross and histopathological features. Histological findings demonstrated no significant difference between the Alpha and Calendula.

4. Conclusion

To sum up Alpha and Calendula ointments can be a suitable alternative for SSD. In addition these topical formulations are more cost-effective.

It is suggested that further studies should be conducted on larger sample sizes or on human cases for a longer period to thoroughly evaluate the efficacy of Alpha and Calendula formulations on burn wounds in human.

Acknowledgment

The authors would like to thank the Research Consultation Center (RCC) of Shiraz University of Medical Sciences for their invaluable assistance in editing this article.

References

- [1] Edraki M, Akbarzadeh A, Hosseinzadeh M, Tanideh N, Salehi A, Koohi-Hosseiniabadi O. Healing effect of sea buckthorn, olive oil, and their mixture on full-thickness burn wounds. *Adv Skin Wound Care* (2014) 27(7): 317-23.
- [2] Tanideh N, Rokhsari P, Mehrabani D, Mohammadi Samani S, Sabet Sarvestani F, Ashraf MJ, Koohi Hosseiniabadi O, Shamsian S, Ahmadi N. The healing effect of licorice on *Pseudomonas aeruginosa* infected burn wounds in experimental rat model. *WJPS* (2014) 3(2): 99-106.
- [3] Sai KP, Babu M. Traditional medicine and practices in burn care: need for newer scientific perspectives. *Burns* (1998) 24(5): 387-8.
- [4] Ashkani-Esfahani S, Imanieh MH, Khoshneviszadeh M, Meshksar A, Noorafshan A, Geramizadeh B, Ebrahimi S, Handjani F, Tanideh N. The healing effect of arnebia euchroma in second degree burn wounds in rat as an animal model. *IRAN RED CREACENT MED J* (2012) 2012(2): 70-4.
- [5] Albertyn R, Berg A, Numanoglu A, Rode H. Traditional burn care in sub-Saharan Africa: a long history with wide acceptance. *Burns* (2015) 41(2): 203-11.
- [6] Stipcevic T, Piljac A, Piljac G. Enhanced healing of full-thickness burn wounds using di-rhamnolipid. *Burns* (2006) 32(1): 24-34.
- [7] Mohsenikia M, Nuraei H, Karimi F, Jamalnia N, Esfahani SA, Rafiee S, Azizian Z, Moradi A. Comparing Effects of Arnebia euchroma and Alpha Ointment on Wound Healing Process. *Thrita* (2015) 4(1).
- [8] Hosseini SV, Tanideh N, Kohanteb J, Ghodrati Z, Mehrabani D, Yarmohammadi H. Comparison between Alpha and silver sulfadiazine ointments in treatment of *Pseudomonas* infections in 3rd degree burns. *Int J Surg* (2007) 5(1): 23-6.
- [9] Nayak BS, Isitor G, Davis E, Pillai G. The evidence based wound healing activity of *Lawsonia inermis* Linn. *Phytother Res* (2007) 21(9): 827-31.
- [10] Muhammad H, Muhammad S. The use of *Lawsonia inermis* Linn.(henna) in the management of burn wound infections. *Afr J Biotechnol* (2005) 4(9).
- [11] Parente LM, Lino Júnior RD, Tresvenzol LM, Vinaud MC, de Paula JR, Paulo NM. Wound healing and anti-inflammatory effect in animal models of *Calendula officinalis* L. growing in Brazil. *Evid Based Complement Alternat Med* (2012) 2012.
- [12] Muley B, Khadabadi S, Banarase N. Phytochemical constituents and pharmacological activities of *Calendula officinalis* Linn (Asteraceae): a review. *Trop J Pharm Res* (2009) 8(5).
- [13] Parente LM, Andrade MA, Brito LA, Moura VM, Miguel MP, Lino-Júnior RD, Tresvenzol LF, Paula JR, Paulo NM. Angiogenic activity of *Calendula officinalis* flowers L. in rats. *Acta Cir Bras* (2011) 26(1):19-24.
- [14] Preethi KC, Kuttan G, Kuttan R. Anti-inflammatory activity of flower extract of *Calendula officinalis* Linn. and its possible mechanism of action. *Indian J Exp Biol* (2009) 47(2): 113.
- [15] Preethi KC, Kuttan R. Wound healing activity of flower extract of *Calendula officinalis*. *J Basic Clin Physiol Pharmacol* (2009) 20(1): 73-80.

- [16] Leach MJ. Calendula officinalis and Wound Healing: A Systematic Review. *Wounds: a compendium of clinical research and practice* (2008) 20(8): 236-43.
- [17] Al-Snafi AE. The chemical constituents and pharmacological effects of Calendula officinalis-A review. *Indian Journal of Pharmaceutical Science & Research* (2015) 5(3): 172-85.
- [18] Re T, Mooney D, Antignac E, Dufour E, Bark I, Srinivasan V, et al. Application of the threshold of toxicological concern approach for the safety evaluation of calendula flower (*Calendula officinalis*) petals and extracts used in cosmetic and personal care products. *Food Chem Toxicol* (2009) 47(6): 1246-54.
- [19] Pommier P, Gomez F, Sunyach M, D'hombres A, Carrie C, Montbarbon X. Phase III randomized trial of Calendula officinalis compared with trolamine for the prevention of acute dermatitis during irradiation for breast cancer. *J Clin Oncol* (2004) 22(8): 1447-53.
- [20] Lievre M, Marichy J, Baux S, Foyatier J, Perrot J, Boissel J. Controlled study of three ointments for the local management of 2nd and 3rd degree burns. *Clin Trial Meta-Anal* (1992) 28(1): 9-12.
- [21] Tanideh N, Haddadi MH, Rokni-Hosseini MH, Hossienzadeh M, Mehrabani D, Sayehmiri K, Koochi-Hossienabadi O. The healing effect of scrophularia striata on experimental burn wounds infected to pseudomonas aeruginosa in rat. *WJPS* (2015) 4(1): 16-22.
- [22] Mehrabani D, Farjam M, Geramizadeh B, Tanideh N, Amini M, Panjehshahin MR. The healing effect of curcumin on burn wounds in rat. *WJPS* (2015) 4(1): 29-35.
- [23] Hosseini S, Niknahad H, Fakhar N, Rezaianzadeh A, Mehrabani D. The healing effect of mixture of honey, putty, vitriol and olive oil in Pseudomonas aeruginosa infected burns in experimental rat model. *Asian J Anim Vet Adv* (2011) 6(6): 572-9.
- [24] Game et al. IWGDF guidance on use of interventions to enhance the healing of chronic ulcers of the foot in diabetes. *Diabetes Metab Rev* (2016) 32(1): 75-83.
- [25] Leaper D. Appropriate use of silver dressings in wounds: international consensus document. *Int Wound J* (2012) 9(5): 461-4.
- [26] Atiyeh BS, Costagliola M, Hayek SN, Dibo SA. Effect of silver on burn wound infection control and healing: review of the literature. *Burns* (2007) 33(2): 139-48.
- [27] Khanavi M, Vatandoost H, Dehaghi NK, Dehkordi AS, Sedaghat MM, Hadjiakhoondi A, Hadjiakhoondi F. Larvicidal activities of some Iranian native plants against the main malaria vector, Anopheles stephensi. *Acta Med Iranica* (2013) 51(3): 141.
- [28] K. Chandran P, Kuttan R. Effect of Calendula officinalis flower extract on acute phase proteins, antioxidant defense mechanism and granuloma formation during thermal burns. *J Clin Biochem Nutr* (2008) 43(2): 58-64.
- [29] Fronza M, Heinzmann B, Hamburger M, Laufer S, Merfort I. Determination of the wound healing effect of Calendula extracts using the scratch assay with 3T3 fibroblasts. *J Ethnopharmacol* (2009) 126(3): 463-7.

ONLINE SUBMISSION

www.ijps.ir