

## The Effect of Chronic Exposure with Imidacloprid Insecticide on Fertility in Mature Male Rats

Golamreza Najafi, D.V.Sc.<sup>1</sup>, Mazdak Razi, Ph.D.<sup>2\*</sup>, Aref Hoshyar, D.V.M.<sup>3</sup>,  
Simineh Shahmohamadloo, D.V.M.<sup>1</sup>, Sajad Feyzi, Ph.D.<sup>1</sup>

1. Anatomy Department, Faculty of Veterinary Medicine, Urmia University, Urmia, Iran
2. Comparative Histology and Embryology Department, Faculty of Veterinary Medicine, Urmia University, Urmia, Iran
3. Basic Science Department, Razi Research Institute, Tehran, Iran

### Abstract

**Background:** This study was conducted to evaluate the effect of chronic exposure to imidacloprid (IM) insecticide on male testicular tissue, sperm morphology and testosterone levels in the serum of mature male rats.

**Materials and Methods:** Animals were divided into and control-sham groups. The test group was subdivided into two groups of rats which were administered doses of 225 and 112 mg/kg IM per group. Each test group received the designated oral dose of IM once daily, for 60 days while the control-sham group received corn oil (0.2 ml/day) for the same time period.

**Results:** Clinical observations demonstrated decreased movement, staggering gait, occasional trembling, diarrhea and spasms in the test groups. No clinical signs were seen in control-sham rats. Light microscopic analyses revealed increased thickness of tunica albuginea, obvious edema in the sub-capsular and interstitial connective tissue, atrophied seminiferous tubules, arrested spermatogenesis, negative tubular differentiation and repopulation indexes, decreased Leydig cells/mm<sup>2</sup> of interstitial tissue, hypertrophy and cytoplasmic granulation of the Leydig cells, vasodilation and thrombosis, elevated death, as well as immature and decreased immotile sperm velocity. Hormonal investigations showed significant ( $p < 0.05$ ) decrease in serum testosterone levels. No hormonal changes were seen in the testosterone levels of the control-sham group.

**Conclusion:** The current data provide inclusive histological feature of chronic IM exposure in two doses with an emphasis on reproductive disorders including a histological adverse effect on testicular tissue, spermatogenesis, sperm viability, velocity and abnormality which potentially can cause infertility.

**Keywords:** Imidacloprid, Testes, Spermatogenesis, Atrophy, Testosterone

### Introduction

Imidacloprid (IM) is a neonicotinoid compound, which is a class of neuro-active insecticides and manufactured after synthetic nicotine. It is widely used in pest control, seed treatment, termite control, flea control, as an insecticide spray and a systemic insecticide (1). According to the WHO and United States Environmental Protection Agency this compound is categorized as a "moderately toxic" Class II or III requiring a Warning or Caution labels on marketed products (2). Animal toxicities of IM are similar to that of toxicities in the parent compound, nicotine. Such toxicities as fatigue, twitching, cramps, and weakness leading to asphyxia are seen (2). The oral LD<sub>50</sub> of IM is 450 mg/kg body weight in rats and 131 mg/kg in mice (3). IM is rapidly and almost completely absorbed

from the gastrointestinal tract, and eliminated via urine and feces, in the case of chronic administration within 48 hours, 70-80% and 20-30% of compound respectively will be absorbed via urine and feces. The most important metabolic steps include the degradation to 6-chloronicotinic acid, a compound which affects the nervous system (4). Like other neonicotinoid compounds, IM is related to nicotine in its structure and action at the nicotinic acetylcholine receptor (5). IM has multiple agonist and antagonist effects on neuronal nicotinic acetylcholine receptor channels of clonal rat phaeochromocytoma cells (6). There are some reports that show IM has an adverse effect on the reproductive tract (7), also this compound has been identified as having teratogenic (8), mutagenic (9), carcinogenic (10) effects in animals and humans.

Received: 30 Sep 2009, Accepted: 21 Feb 2010

\* Corresponding Address: P.O.Box: 1177, Comparative Histology and Embryology Department, Faculty of Veterinary Medicine, Urmia University, Urmia, Iran  
Email: Mazdak\_razi22@yahoo.com



Royan Institute  
International Journal of Fertility and Sterility  
Vol 4, No 1, Apr-Jun 2010, Pages: 9-16

Therefore, the health risks to humans of this class of insecticides have attracted the attention of many investigators. Histopathological changes have been widely used as significant biological markers for environmental toxicity (11, 12). Thus the purpose of this study was to investigate the effect of IM on testicular tissue and to evaluate the effect of this compound on the quality, quantity and morphology of sperm content in chronic exposed mature male rats as a laboratory model for humans.

## Materials and Methods

### *Animals*

In this study, 42 mature male Wistar rats, 8 weeks old and weighing  $200 \pm 14$  g were used. The rats were purchased from the Animal Resources Center of the Faculty of Veterinary Medicine at Urmia University, Iran. Rats were acclimatized in an environmentally controlled room (20-23°C, and a 12 hours light/12 hours dark cycle). Special plates containing tap water were given to all group animals. In this study all experiments conducted on the animals were in accordance with the guidance of the Ethics Committee for Research on Laboratory Animals at Urmia University.

### *Experimental design*

Following an acclimation period of one week, the animals were assigned to three groups (n=10) as control and two test groups. All animals were weighed prior to the onset of treatment as well as following treatment to evaluate any increase in body weight gain (BWG). Animals in the control group were administered corn oil (0.2 ml/day) and animals in the test groups were gavaged with IM, 225 and 112 mg/kg per body weight, once daily a total of 60 days.

### *Testicular weight determination*

Following anesthesia with Ketamine (5%, 40 mg/kg, i.p.) on days 10, 20, 30, 40, 50, 60 all rats in each test group (n=6) were euthanized by using CO<sub>2</sub> gas in a special device and immediately following weighting of total body weight the testicles were excised free of surrounding tissues and weighed on a Mattler Basbal scale (Delta Range, Tokyo).

### *Serum sampling and hormonal analysis*

On days 10, 20, 30, 40, 50 and 60 blood samples from the corresponding animals were collected directly from the heart and the serum samples separated by centrifugation. The collected serum samples were subjected to hormonal analysis. Serum testosterone levels were measured by radioimmunoassay. The limit of detection (LOD) was 0.12 ng/

ml for testosterone. The intra-assay and inter-assay coefficient of variances for testosterone were determined to be 4.8 and 9.9 (both for 10 times), respectively.

### *Histopathological analyses*

All specimens were fixed in 10% formalin fixative for histological investigations and subsequently embedded in paraffin. Sections (5-6 µm) were stained with iron-weigert for histopathological assessment of germinal cell nuclei in the testes. All specimens were studied by multiple magnifications ( $\times 400$  and  $\times 1000$ ). For the quantification of cells and their dimensions, a 100 µm morphometrical lens - device was used. The dimensions were expressed in µm.

### *Epididymal sperm content, quantitative sperm mortality and morphology*

The epididymis was separated carefully from the testicle under  $\times 10$  magnification with the use of a stereo zoom microscope (model TL2, Olympus Co., Tokyo, Japan). The epididymis was divided into three segments: head, body and tail. The epididymal tail was trimmed and minced in 5 ml ham's F10 medium (Sigma Co.) for 20 minutes, 5% CO<sub>2</sub>, 37°C in a CO<sub>2</sub> incubator (Model LEEC, England). After 20 minutes, the epididymis was removed from the medium, 10 drops from medium were used for analyzing the percentage of sperm viability. Sperm with stained cytoplasm in the head, neck and tail pieces were considered nonviable. For this reason, the eosin-necrosin staining technique was conducted; moreover, sperm that contained any cytoplasmic droplets in the head, neck and tail pieces were labeled as immature. The proportion of nonviable spermatozoa was determined by counting 100 squares in a randomly selected field from ten smeared slides, for each case (13).

### *Tubular differentiation index (TDI) determination*

To estimate TDI, the percentage of seminiferous tubules (STs) with greater than three layers of differentiated germinal cells from spermatogonia type A, in 200 sections (6µm) were prepared. STs with greater than three layers were considered to be TDI positive.

### *Repopulation index (RI) calculation*

To determine RI, the ratio of active spermatogonia (spermatogonia type B with light nuclei as seen by iron-weigert staining) to inactive spermatogonia (spermatogonia type A with dark nuclei as seen by iron-weigert staining), in STs was calculated in 200 prepared sections, as mentioned earlier (14).

### Statistical analyses

Statistical analyses was performed on all data using the paired t test to compare quantitative parameters referring to paired organs within a group and one-way analyses followed by the Bonferroni test, using Graph Pad Prism 4.00, Graph Pad Software. All values were expressed as the mean  $\pm$  SD.  $P < 0.05$  was considered to be statistically significant.

### Results

Both IM and corn oil administration had no effect on food and water consumption in the test and control-sham cases, respectively. Corn oil did not exert any significant effect on BWG in the control-sham group, while administration of IM reduced body weight in the test group. Testicles decreased in size and weight in the IM administered rats (Table 1).

Also all animals in the test groups were observed to have decreased movement, staggering gait, oc-

casional trembling, diarrhea and spasms.

Histological investigations revealed that the tunica albuginea increased in thickness after day 30 in the high dose and day 40 in the low dose test rats. The control-sham group showed normal tunica thickness. Sub-capsular and perivascular edema was demonstrated in both test groups, which increased with time (Fig 1A, B, C). Considerable vasodilatation associated with remarkable thrombosis was demonstrated in both the right and left testicles after days 20 and 30 in both the high and low dose test rats, respectively.

Infiltration of the immune-mononuclear cells in the interstitial connective tissue was elevated in the test groups in comparison to the control-sham group.

After day 30 in the high dose and day 40 in the low dose cases,  $74.52 \pm 2.396$  and  $64.073 \pm 0.874$  percent of Leydig cells demonstrated severe hypertrophy and cytoplasmic granulation in both test groups, respectively.

**Table 1: Effect of IM on testicular weight (T.W), body weight (B.W), germinal epithelium height (G.E.H), Sts diameter (STs.D) in high dose (H.D) and low dose (L.D) test rats (Mean  $\pm$  SD).**

	Con	10	20	30	40	50	60
<b>T.W (gr)</b>							
H.D	0.89 $\pm$ 0.106	0.88 $\pm$ 0.10*	0.74 $\pm$ 0.07*	0.68 $\pm$ 0.06*	0.65 $\pm$ 0.10*	0.63 $\pm$ 0.09*	0.63 $\pm$ 0.10*
L.D	0.89 $\pm$ 0.106	0.89 $\pm$ 0.10*	0.76 $\pm$ 0.08*	0.69 $\pm$ 0.10*	0.66 $\pm$ 0.08*	0.66 $\pm$ 0.08*	0.64 $\pm$ 0.10*
<b>B.W (gr)</b>							
H.D	208.64 $\pm$ 5.64	197.44 $\pm$ 1.68 <sup>ab</sup>	192.65 $\pm$ 1.41 <sup>ab</sup>	175.94 $\pm$ 1.99 <sup>ab</sup>	166.19 $\pm$ 3.48*	162.37 $\pm$ 2.07 <sup>ab</sup>	157.24 $\pm$ 2.33 <sup>ab</sup>
L.W	208.64 $\pm$ 5.64	200.91 $\pm$ 1.78 <sup>at</sup>	195.37 $\pm$ 1.04 <sup>at</sup>	178.51 $\pm$ 1.26 <sup>at</sup>	169.61 $\pm$ 4.20*	165.33 $\pm$ 2.61 <sup>at</sup>	157.17 $\pm$ 1.37 <sup>at</sup>
<b>G.E.H (<math>\mu</math>m)</b>							
H.D	64.88 $\pm$ 1.98	59.10 $\pm$ 0.63 <sup>ab</sup>	54.41 $\pm$ 2.64 <sup>ab</sup>	41.91 $\pm$ 0.78 <sup>ab</sup>	42.60 $\pm$ 2.06 <sup>ab</sup>	46.47 $\pm$ 1.72 <sup>ab</sup>	47.98 $\pm$ 2.33 <sup>ab</sup>
L.D	64.88 $\pm$ 1.98	59.85 $\pm$ 1.43 <sup>ab</sup>	54.30 $\pm$ 1.87 <sup>ab</sup>	42.51 $\pm$ 3.48 <sup>ab</sup>	47.41 $\pm$ 0.95 <sup>ab</sup>	50.31 $\pm$ 2.55 <sup>ab</sup>	49.09 $\pm$ 2.55 <sup>ab</sup>
<b>STs.D (<math>\mu</math>m)</b>							
H.D	224.80 $\pm$ 1.07	213.59 $\pm$ 1.36 <sup>c</sup>	208.82 $\pm$ 1.96 <sup>c</sup>	190.01 $\pm$ 5.27 <sup>c</sup>	184.28 $\pm$ 0.66 <sup>c</sup>	191.10 $\pm$ 1.61 <sup>c</sup>	196.87 $\pm$ 6.17 <sup>c</sup>
L.D	224.80 $\pm$ 1.07	216.80 $\pm$ 2.48 <sup>c</sup>	210.65 $\pm$ 3.00 <sup>c</sup>	197.99 $\pm$ 2.00 <sup>c</sup>	199.32 $\pm$ 2.98 <sup>c</sup>	203.93 $\pm$ 3.80 <sup>c</sup>	196.87 $\pm$ 6.17 <sup>c</sup>

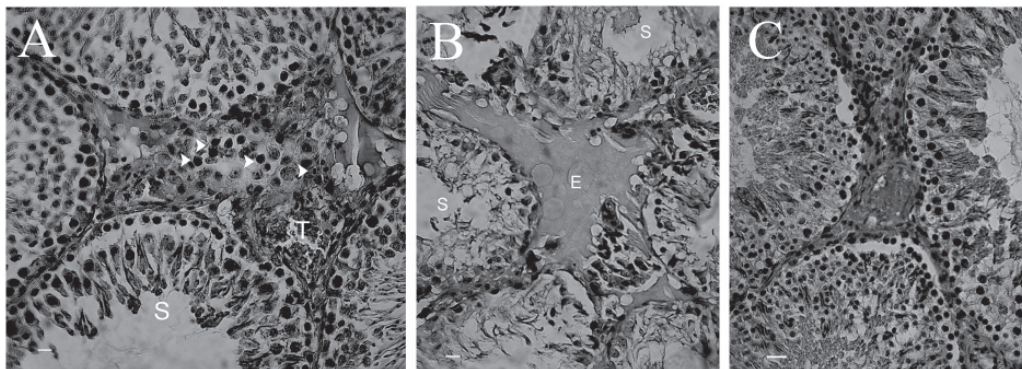
Different superscript letters indicate significant differences ( $p < 0.05$ ) between the high and low dose test rats in the same column. The stars represent significant differences between all test and control-sham groups in the same rows.

**Table 2: Mean average for immune-mononuclear cells (IMN) and Leydig cells (L.Cells) (number/mm<sup>2</sup> of the interstitial connective tissue) in high dose (H.D) and low dose (L.D) test rats (Mean  $\pm$  SD)**

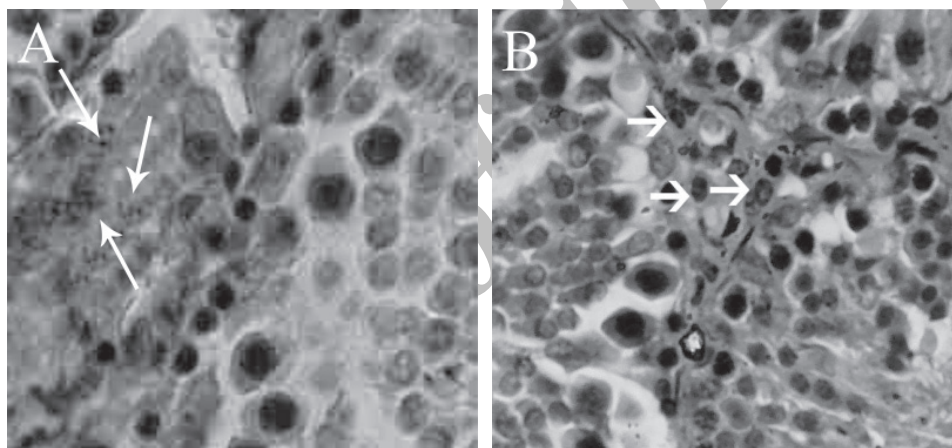
	Con	10	20	30	40	50	60
<b>IMN. Cells (NO)</b>							
H.D	7.88 $\pm$ 1.16	3.11 $\pm$ 1.45 <sup>ab</sup>	22.66 $\pm$ 1.50 <sup>ab</sup>	25.55 $\pm$ 1.01*	30.11 $\pm$ 2.147*	32.33 $\pm$ 1.33*	31.11 $\pm$ 3.25*
L.D	7.88 $\pm$ 1.66	8.11 $\pm$ 1.05 <sup>at</sup>	17.77 $\pm$ 0.97 <sup>at</sup>	23.44 $\pm$ 1.94*	27.44 $\pm$ 1.33*	29.33 $\pm$ 1.58*	29.88 $\pm$ 3.75*
<b>L.Cells (NO)</b>							
H.D	9.40 $\pm$ 0.14	8.80 $\pm$ 0.83*	6.20 $\pm$ 1.33*	4.4 $\pm$ 0.89*	3.6 $\pm$ 0.54*	2.6 $\pm$ 0.54*	4.8 $\pm$ 0.83*
L.D	9.40 $\pm$ 0.14	9.00 $\pm$ 0.70*	7.20 $\pm$ 1.33*	4.8 $\pm$ 0.83*	3.8 $\pm$ 0.83*	3.6 $\pm$ 1.14*	5.00 $\pm$ 1.00*

Different superscript letters indicate significant differences ( $p < 0.05$ ) between the high and low dose test rats in the same column. The stars represent significant differences between all test and control-sham groups in the same rows.

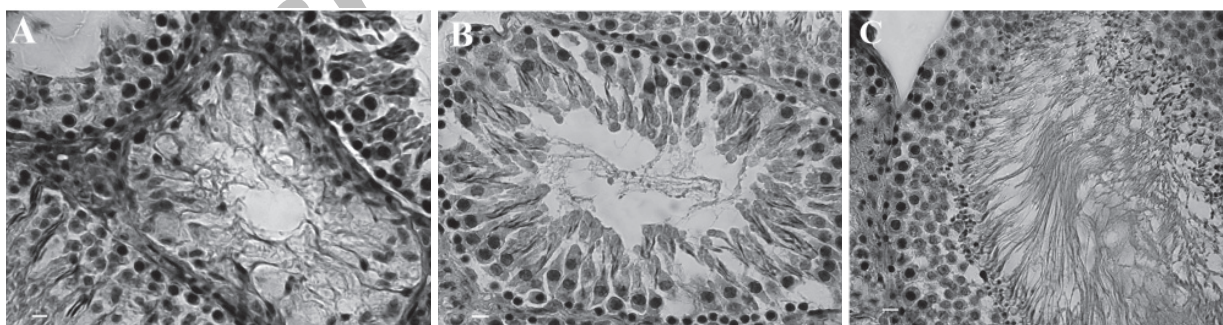




**Fig 1:** (A&B) Histological architecture of the testis in test groups. A) Edema (E) in interstitial connective tissue with high infiltration of immune-mononuclear cells (arrows) is noted, vascular thrombosis (T), depleted seminiferous tubules (S). B) Note the advanced edema with increased infiltration of the immune-mononuclear cells (E), remarkable seminiferous tubule depletion. C) Histological architecture of the testis in the control-sham group. STs with no histological changes in germinal cell proportion and edema in the interstitial tissue are present. Iron-weigert staining technique ( $\times 100$ ).



**Fig 2:** A) Histological architecture of the testis in test groups. The Leydig cells present with cytoplasmic granulation, hypertrophy and aggregation. B) Histological architecture of the testis in the control-sham group. Leydig cells have a normal appearance. Iron-weigert staining technique, ( $\times 400$ ).



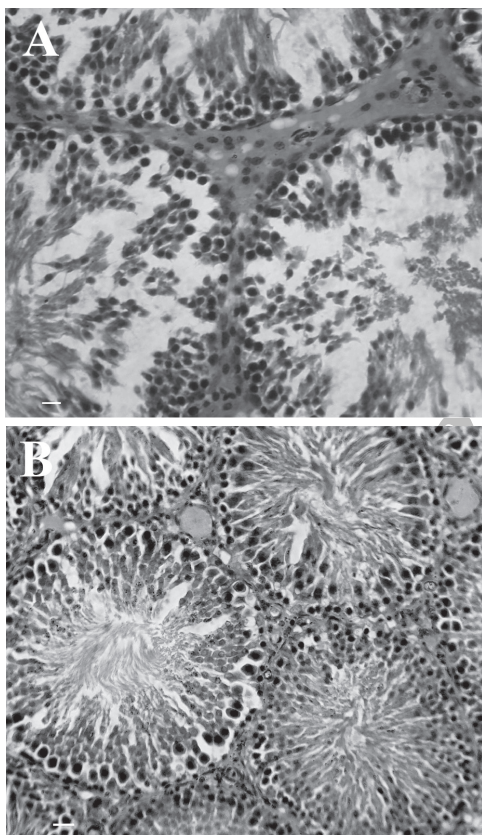
**Fig 3:** (A & B) Histological architecture of the testis in test groups. A) Note the arrested spermatogenesis with severe STs depletion in advanced stages of exposure to IM. B) In this figure STs present with a negative tubular differentiation index and repopulation index in the earlier stages of exposure to IM. Note the weak spermatogenesis. C) Histological architecture of the testis in the control-sham group. The spermatogenesis and spermatogenesis processes are normal, seminiferous tubules present with a high proportion of spermatozoa, Iron-weigert staining technique ( $\times 100$ ).

No histological changes were observed in the control-sham group (Figs. 2A, B). The data for immune and Leydig cells are presented in table 2. Light microscopic analyses showed severe atrophy

of the STs. Degenerated germinal epithelium was seen in 90% of the STs in both test groups after day 30. Accordingly this situation progressed in the high dose administered rats. It should be men-

tioned that spermatozoa presentation decreased in the lumen of the STs and the spermatogenesis process was arrested in both test groups. Histological investigations demonstrated arrested spermatogenesis in the test groups (This is the same as the previous sentence.). Decreased height (2-3 layers) was seen in the germinal epithelium of 90% of the STs after days 40 and 50 in high and low dose administered rats (negative TDI), respectively (Figs. 3A, B, C).

In both test groups increased spacing between the germinal cells and the association between Sertoli and germinal cells was also disrupted (Fig 4A, B).

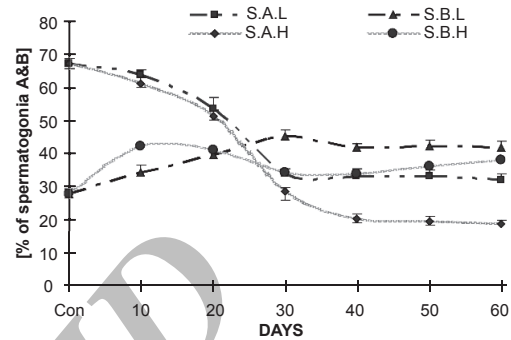


**Fig 4:** (A) Histological architecture of the testis in test groups. Note the germinal cells that are dissociated in STs. (B) Histological architecture of the testis in the control-sham group, STs are normal and no histological changes are seen in the figure B, iron-weigert staining technique, ( $\times 100$ ).

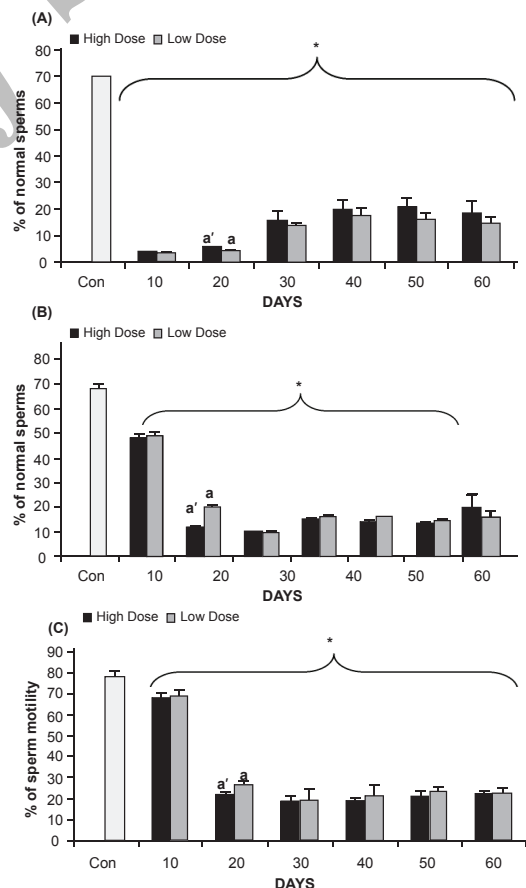
No histological changes were observed in the control-sham group. Prior to day 50 in the high dose and 40 in the low dose test groups, the percentages of spermatogonia type B decreased in comparison to spermatogonia type A when compared to the control-sham group (negative RI; Fig 5). This weakly improved on days 50 and 40 in the high and low dose cases, respectively.

The eosin-necrosin staining technique showed in-

creased abnormal sperm velocity with decreased sperm viability. The motile sperm velocity was reduced in the test groups in comparison to the control-sham rats (Fig 6A, B, C).



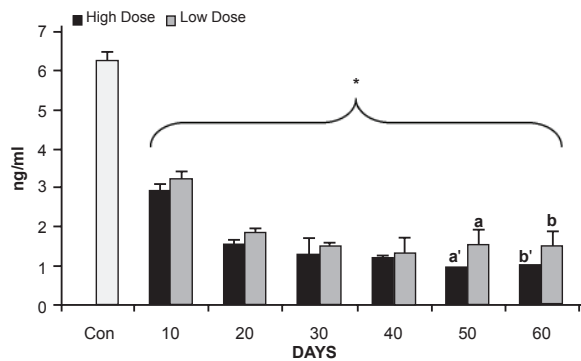
**Fig 5:** Repopulation index seen in different groups. There are significant differences ( $p < 0.05$ ) between data for spermatogonia A (S.A) and spermatogonia B (S.B) in the low (L) and high (H) dose test groups when compared with the control-sham group).



**Fig 6:** (A) Normal sperm content, (B) viability of sperm content and, (C) motile sperm content in the control-sham and test groups. Star indicates significant differences between test and control-sham groups. Letters indicate significant differences between the two doses. ( $p \leq 0.05$ ).



Meanwhile these parameters insignificantly improved after days 50 in both test groups, when compared to prior to day 50. Hormonal analyses showed significantly ( $p < 0.05$ ) reduced testosterone levels in both test groups until day 50, followed by a slight increase on day 60 in both test groups (Fig 7).



**Fig 7:** Testosterone levels in the control-sham and test groups. Star indicates significant differences between test and control-sham groups. Letters indicate significant differences between the two doses. ( $p \leq 0.05$ ).

## Discussion

Different insecticides are in wide use worldwide, of which 5% of the world's population (mainly agro-workers) are directly exposed to these insecticides. According to recent reports, this population is calculated to be 2.6 million persons (15). IM is a chlorinated analog of nicotine, which belongs to the class of neonicotinoid insecticides. IM has low vapor pressure and the technical product (94.0% IM) has a moderate order of toxicity with respect to ingestion in the rat, but appears to be less toxic when absorbed by the skin or inhaled. IM may cause minimal redness to the eyes but is non-irritating to the skin (16). In agreement with other reports; in the present study no dermal lesions and irritations were seen in rats were exposed to IM. All animals were observed to have decreased movement, staggering gait, occasional trembling, diarrhea and spasms - clinical findings which were similar to those reported by a Smith Corporation report in 1999 (17). In the present study, all animals in the test groups showed significant decreases in body weight gain in comparison to the control rats. Testicular weight and size. Insecticides and pesticides act as reproductive toxicants in male rats and histologically induce severe focal necrosis of the germinal cells in STs associated with tubular atrophy (18-20).

In accordance with previous findings, light microscopic analyses of the current study showed that the adverse effect of IM was not limited to cellular de-

generation in the germinal epithelium of STs, but also affected TDI and RI of the germinal epithelium by causing severe inflammation in the STs.

The importance of androgens for normal spermatogenesis has been previously well documented. Previous studies indicated that most insecticides inhibit the non-specific esterase activity in leydig cells that, in turn, result in reduced testosterone production (20, 21). Testosterone, through modulation of P-mod-S in the peritubular cells, could affect Sertoli cell function (22, 23). Any functional damage in sertoli cells could lead to germinal cells degeneration and dissociation. In light of the previous findings, our histological investigations demonstrated decreased numbers/mm<sup>2</sup> of Leydig cells of the interstitial connective tissue in the test groups. On the other hand, hormonal analyses showed testosterone reduction in animals administered IM. Spermatogenesis depends on testosterone production by Leydig cells in response to stimulation by follicular stimulation hormone (FSH) and luteinizing hormone (LH) (23). Therefore, it would be more logical to hypothesize that IM-exposure resulted in leydig cell degeneration, lead to reduction in blood testosterone level and altimetry caused sertoli cell dysfunction. Consequently, sertoli cell dysfunction in turn could be able to result in germinal cell degeneration and dissociation in STs of test animals. Similar results were obtained for bromopropane (an organophosphorus compound), endosulfan, malathion, and methomyl (insecticide compounds) when rats were chronically exposed to these compounds (20, 24-26).

Some authors reported a significant reduction in the number of motile sperm with a considerable increase in the percentage of dead sperm in the cases with chronic insecticide exposure (20, 25, 26). Researchers attributed the dramatic dysfunction of the testicular tissue to the direct toxic effect of the insecticides on testicular tissue. Insecticides deplete the renewing type A spermatogonia, which essential for proliferation in spermatogenesis (20). Thus, we can conclude that any degeneration event by IM in the germinal epithelium was able to lead interruption in the mitotic activity of type A spermatogonia cells, which in turn could arrest spermatogenesis and spermyogenesis processes. According to previous reports, chronic exposure to insecticides (for example carbendazim) increased the death, abnormal and immature sperm ratios (27, 28).

Reactive oxygen species (ROS) are known to mediate many toxin-induced testicular injuries (30). There are some reports concerning the association between organophosphate compounds

(as well known pesticides and/or insecticides) and ROS that cause injuries to different organs (31, 32). A variety of components in the male genital system are capable of generating ROS, including: morphologically abnormal spermatozoa, precursor germ cells, leukocytes, particularly those which are peroxidase-positive, and degenerated cells in the spermatogenesis series (29). Exposing the sperm to artificially produced ROS causes DNA damage in the form of modification of all bases, and leads to production of base-free sites, deletions, frame shifts, DNA cross-links, and chromosomal rearrangements (30). In the present study such evidence including: elevated abnormal sperm content, increased infiltration of immune-mononuclear cells/mm<sup>2</sup> of the interstitial connective tissue, degenerated germinal cells in both test groups, all of which indicate a probable major role of imbalanced oxidative stress in the generation of various disorders. According to this finding, it is possible that IM has exerted oxidative stress in the testicles of the test group rats and consequently it possibly increases nonviable sperm velocity (because of severe DNA damage).

Levels of ROS production by sperm correlate negatively with sperm quality in the original semen (34). The link between poor sperm quality and increased ROS generation lies in the retention of excess residual cytoplasm (cytoplasmic droplets) in abnormal spermatozoa. When spermatogenesis is impaired, the cytoplasmic extrusion mechanisms are defective (35). In the present study all animals in the test groups manifested with impaired spermatogenesis and the sperm morphological study showed an elevated immature sperm content with cytoplasmic droplets in different components of the sperm. Thus we can conclude that possibly the direct effect of toxin on testicles and androgens secretion increased all the pathological characteristics that were able to cause oxidative stress and, in the second phase, generated an oxidative condition that enhanced dysfunction of the testicular tissue.

Insecticides generally affect the liver as a probable target. According to a California Environmental Protection Agency report in 1992, the rats that were chronically exposed to varying doses of different insecticides showed pathological changes to the liver, as seen under light microscopic analyses, which included: tumors, hypertrophy and malignancy (30). Repeated doses of methomyle (an insecticide) were found to induce inhibition of B6-dependent kyurinine hydrolase and kyurinin aminotransferase activities in the mouse liver (24). The liver, kidneys, thyroid, heart, lungs, spleen, adrenal, brain, and gonads have been reported as affected organs for IM

toxicity (16). It is well known that IM rapidly absorbs via the gastrointestinal tract (4) and the liver is the main organ to metabolize this compound. Thus, physiologically the liver will be affected directly by this toxin in the different period of consumption. According to our results, rats in the test groups showed insignificant improvement for all of the pathological characteristics in the testes, sperm content and testosterone levels. This can suggest that possibly the pathological changes that occurred in the liver and its enzyme activities in the test groups stopped IM metabolism. Therefore, this deficiency lead to a decrease in the main toxic metabolite of IM in the circulatory system. Therefore our results showed an insignificant improved condition in germinal cells series, abnormal, immature and death sperm velocity in the test groups. On the other hand, more than 89% of the IM induced rats showed clinically severe diarrhea after days 30 in the high and 40 in the low dose administrated rats. It was possible that the diarrhea itself participated in reducing IM absorption in the test groups. Physiologically if the absorption rate of IM reduced, the proportion of IM would be decreased in the total blood circulation.

## Conclusion

According to our results male reproductive tract can be consider as a target for IM in the case if animals which expose to this compound chronically and it can cause histological damage on testicular tissue, sperm mortality, morphology and decreased testosterone level in mature male rats. Thus this compound can cause infertility problems in chronically induced cases.

## Acknowledgments

The authors acknowledge no conflict of interest in this study. The authors wish to thank Mr. Ali Karimi and the Department of Comparative Histology and Embryology for their assistance. This manuscript has not been supported with any organization.

## References

1. Kidd H, James D. *Agrochemicals Handbook*. 3<sup>rd</sup> ed. England: Royal Society of Chemistry; 1994; 232-234.
2. Avery ML, Decker DG, Fischer DL. Cage and flight pen evaluation of avian repellancy and hazard associated with imidacloprid-treated rice seed. *Crop Protection*. 1994; 13(7): 535-540.
3. Doull J, Klassen CD, Amdure MO. Cassaret and Doull's toxicology. *The Basic Science of Poisons*. 4<sup>th</sup> ed. Germany: Pergamoon Press; 1991; 401-400.
4. Meister RT. *Farm Chemicals Handbook*. 2<sup>nd</sup> ed. New York. Meister Publishing Company; 1994; 301-305.
5. Casida JE. Cholinergic insecticide toxicology. *Crisp Data Base*, National Institutes of Health, National Insti-

- tute of Environmental Health Sciences. Germany: WHO report; 1998; 21.
6. Nagata K, Song JH, Shono T, Narahashi T. Modulation of the neuronal nicotinic acetylcholine receptor-channel by the nitromethylene heterocycle imidacloprid. *J Pharmacol Exp Ther.* 1998; 285: 731-738.
  7. Rouchard J, Gustin F, Wauters A. Soil organic matter aging and its effect on insecticide imidacloprid soil biodegradation in sugar beet crop. *Toxicol Environ Chem.* 1994; 45(4): 149-155.
  8. Pike KS, Reed GL, Graf GT, Allison D. Compatibility of imidacloprid with fungicides as a seed-treatment control of russian wheat aphid (Homoptera: Aphidae) and effect on germination, growth, and Yield of Wheat Barley. *J Econ Entomol.* 1993; 86(2): 586-593.
  9. Placke FJ, E Weber. Method of determining imidacloprid residues in plant materials. *Pflanzenschutz-Nachrichten Bayer.* 1993; 46(2): 109-182.
  10. Scholz K, M Spittler. Influence of groundcover on the degradation of <sup>14</sup>C-imidacloprid in soil. *Proceeding of the Brighton Crop Protection Conference;* 1992, may 13-15, UK. Germany: Extention Toxicology Net Work. 1992.
  11. Hinton DE, Baumann PC, Gardner GR, Hawkins WE, Hendricks JD. Histopathologic biomarkers. In: *Biochemical, physiological and histological markers of anthropogenic stress.* 3<sup>rd</sup> ed. New York: Lew Pub; 1992; 155-209.
  12. Bhuiyan A, Nesa B, Nessa Q. Effects of sumithion on the histological changes of spotted murrel, *Channa punctatus* (Bloch). *Pak J Biol Sci.* 2001; 4: 1288-1290.
  13. Suzuli N, Sofikitis N. Protective Effects of Antioxidants on testicular functions of varicocele rats. *Yonago Acta Medica.* 1999; 42: 87-94.
  14. Shetty G, Wilson G, Huhtaniemi I, Shuttlesworth GA, Reissmann T, Meistrich ML. Gonadotropin releasing hormone analogs and testosterone inhibits the recovery of spermatogenesis in irradiated rats. *Endocrinology.* 2000; 141: 1735-1745.
  15. David JG. Toxicity of imidacloprid to *Galendromus occidentalis*, *Neoseiulus fallacis* and *Amblyseius andersoni*. *Exp Applied Acarol.* 2004; 34: 275-281.
  16. Mizzel RF, Sconyers MC. Toxicology of imidacloprid to selected arthropod predators in laboratory. *Flor Entomol.* 1992; 75: 277-280.
  17. Smith SF, Krischik VA. Effects of systemic imidacloprid on *Coleomegilla maculate*. *Environ Entomol.* 1999; 28: 1189-1195.
  18. Narayana K, Prashanthi N, Bairy LD, Souza U. An organophosphate insecticide methyl parathion (0-0-dimethyl 0-4-nitrophenylphosphorothioate) induces cytotoxic damage and tubular atrophy in the testis despite elevated testosterone level in rats. *J Toxicol Sci.* 2006; 31: 177-189.
  19. Swart Y, Kruger TF, Menkveld R, Schabort I, Lombard CJ. Effect of Lead and Organophosphates on Sperm Morphology. *System Biol Reprod Medicine.* 1991; 26: 67-70.
  20. Bustos OE, González HP. Effect of a single dose of malathion on spermatogenesis in mice. *Asian J Androl.* 2003; 5: 105-107.
  21. Chapin RE, Phelps JL, Somkuti SG, Heindel JJ, Burka LT. The interaction of Sertoli and Leydig cells in the testicular toxicity of tri-o-cresyl phosphate. *Toxicol Appl Pharmacol.* 1990; 104: 483-495.
  22. Skinner MK, Fritz IB. Testicular peritubular cells secrete a protein under androgen control that modulates Sertoli cell functions. *Proc Natl Acad Sci.* 1985; 82: 114-118.
  23. Kackar R, Srivastava MK, Raizada RB. Assessment of toxicological effects of mancozeb in male rats after chronic exposure. *Indian J Exp Biol.* 1999; 37: 553-559.
  24. Mahgoub AA, Azza EIM. Evaluation of subchronic Exposure of the male rat's reproductive system to the insecticide methomyl. *Saudi J Biol.* 2000; 7(2): 138-145.
  25. Saiyed H, Dewan A, Bhatnagar V, Shenoy U, Shenoy R, Rajmohan H, et al. Effect of endosulfan on male reproductive development. *Environ Health Perspect.* 2003; 111(16): 1958-1962.
  26. WU X, Faqi AS, Yang L, Ding X, Jiang X, Chahoud, I. Male reproductive toxicity and beta-lutenizing hormone gene expression in sexually mature and immature rats exposed to 2-bromopropane. *Hum Exp Toxicol.* 1999; 8: 683-690.
  27. Kishimoto K, Fukuyado T, Sawamoto O, Kurisu K. Influence of daily subcutaneous administration of reserpine for 4 weeks or 9 weeks before mating on testis, sperm and male fertility in rats. *J Toxicol Sci.* 1995; 20: 367-374.
  28. Goldman JD, Rehnberg GL, Cooper RL, Gray LE, Hein JF, McElroy WK. Effects of the benomyl metabolite, carbendazim, on the hypothalamic - pituitary reproductive axis in the male rat. *Toxicol.* 1989; 57: 173-182.
  29. Ashok A, Ramadan A. Role of oxidants in male infertility: rationale, significance, and treatment. *Urolog Clin North America.* 2002; 29(4): 10-11.
  30. Gultekin F, Ozturk M, Akdogan M. The effect of organophosphate insecticide chlorpyrifos-ethyl on lipid peroxidation and antioxidant enzymes (in vitro). *Arch Toxicol.* 2000; 74(9): 533-538.
  31. Yu F, Wang Z, Ju B, Wang Y, Wang J, Bai D. Apoptotic effect of organophosphorus insecticide chlorpyrifos on mouse retina in vivo via oxidative stress and protection of combination of vitamins C and E. *Exper Toxicol Pathol.* 2008; 59(6): 415-423.
  32. Kessopoulou E, Tomlinson MJ, Banat CLR. Origin of reactive oxygen species in human semen-spermatozoa or leukocytes. *J Reprod Fertil.* 1992; 94: 463-70.
  33. Duru NK, Morshedi M, Oehninger S. Effects of hydrogen peroxide on DNA and plasma membrane integrity of human spermatozoa. *Fertil Steril.* 2000; 74: 1200-1207.
  34. Gomez E, Irvine DS, Aitken RJ. Evaluation of a spectrophotometric assay for the measurement of malondialdehyde and 4-hydroxyalkenals in human spermatozoa: relationships with semen quality and sperm function. *Int J Androl.* 1998; 21: 81-94.
  35. Huszar G, Sbracia M, Vigue L. Sperm plasma membrane remodeling during spermiogenic maturation in men: relationship among plasma membrane beta 1,4-galactosyltransferase, cytoplasmic creatine phosphokinase and creatine phosphokinase isoform ratios. *Biol Reprod.* 1997; 56: 1020-1024.