

Case Report

Ectopic Pregnancy in Cesarean Section Scar: A Case Report

Firoozeh Ahmadi, M.D.*, Fatemeh Zafarani, B.Sc., Hadieh Haghighi, B.Sc.,
Maryam Niknejadi, M.D.

Reproductive Imaging Department, Royan Institute for Reproductive Biomedicine,
ACECR, Tehran, Iran

Abstract

Pregnancy implantation within the scar of a previous cesarean delivery is one of the rarest locations for an ectopic pregnancy. Early diagnosis of this condition with the use of ultrasound imaging allows for preserving the uterus and subsequent fertility. However, a delay in either diagnosis or treatment can lead to uterine rupture, hysterectomy and significant maternal morbidity.

With increasing incidence of cesarean sections (CS) worldwide and more liberal use of transvaginal sonography (TVS) in early pregnancy, more cases of cesarean scar pregnancy (CSP) are diagnosed. Thus every woman with a previous CS presenting to the early pregnancy unit should have a routine check for the cesarean scar appearance.

We present the case of a 34 year-old multigravid woman who was found to have an ectopic pregnancy in a cesarean scar at six weeks gestation, with significantly elevated beta-human chorionic gonadotrophin (Beta-hCG) level.

Keywords: Cesarean Section, Ectopic Pregnancy, Pregnancy

Introduction

An ectopic pregnancy is a complication of pregnancy in which the fertilized ovum develops in any tissue other than the uterine wall. Cesarean scar pregnancy (CSP) is a rare but potentially serious complication of early pregnancy. In this rare condition, the gestational sac implants within the myometrium at the site of a previous cesarean hysterotomy. The incidence of ectopic pregnancy is unknown, as very few cases have been reported in the literature. A recent case series estimates an incidence of 1:2226 of all pregnancies, with a rate of 0.15% in women with a previous cesarean section (CS) and a rate of 6.1% of all ectopic pregnancies in women who had at least one cesarean delivery (1). The time interval between the last CS and the CSP was six months to 12 years (1, 2). The gestational age at diagnosis ranged from 5+0 to 12+4 weeks (3). It is important to be able to diagnose the condition as early as possible in order to prevent catastrophic consequences. We describe a case of CSP with early diagnosis at six weeks gestation. The mass eventually resolved without any treatment.

Case Report

We present a 34 year-old woman, gravida 3;

para 2 that was referred to our institute approximately six weeks after her last normal menstrual period (LMP) and with a significantly elevated beta-human chorionic gonadotrophin (Beta-hCG) level (460 IU/ml). She had a history of two prior cesarean deliveries, nine and five years ago, and a curettage following a spontaneous abortion. The initial transvaginal ultrasound at approximately six weeks gestational age revealed an 8 mm long embryo with no cardiac activity that was implanted in an ectopic position in the cesarean section scar. The gestational sac of 2.5 cm diameter was anterior to the cervix and adjacent to the bladder, which was covered only by a thin 3 mm thickness of the myometrium. No intrauterine pregnancy was identified (Fig 1).

One week later she referred with vaginal bleeding. A repeat ultrasound revealed a hemorrhagic mass around the sac and no fetal growth was seen.

Complete disappearance of the gestational sac was confirmed by a follow-up ultrasound one week later in the absence of any treatment.

β -hCG levels progressively declined during the weekly follow-ups.

Received: 25 Feb 2010, Accepted: 14 Sep 2010

* Corresponding Address: P.O.Box 19395-4644, Reproductive Imaging Department, Royan Institute for Reproductive Biomedicine, ACECR, Tehran, Iran

Email: f_ahmadi@royaninstitute.org



Royan Institute
International Journal of Fertility and Sterility
Vol 4, No 3, Oct-Dec 2010, Pages: 140-142

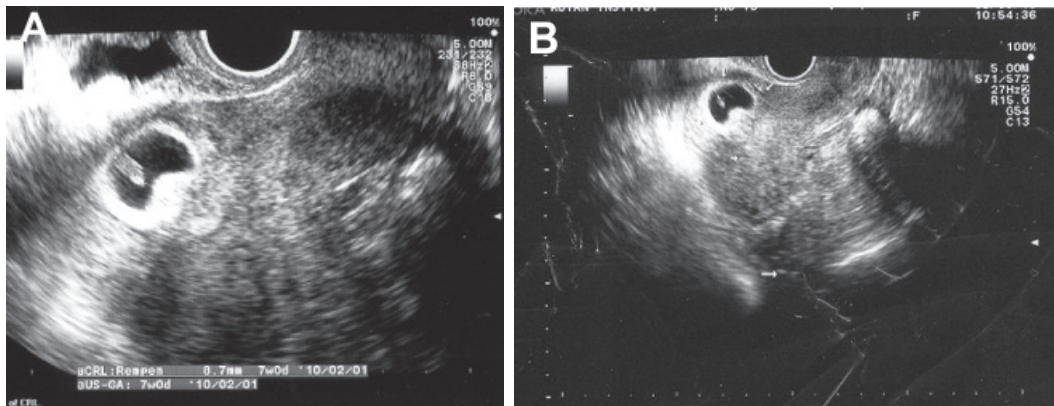


Fig 1: A, B. Sagittal transvaginal ultrasound shows gestational sac with embryo and yolk sac in ectopic pregnancy. Real time scanning showed no cardiac activity.

Discussion

Sonography is the first-line diagnostic tool for CSP. A delay in diagnosis can lead to uterine rupture with a high risk of hysterectomy causing serious maternal morbidity and loss of future fertility. There is also a danger of bladder invasion by the growing placenta.

In most cases implantation occurs at the site of a defect in the scar. Deficient uterine scars are a frequent finding in women with a history of previous CS and other traumas such as curettage, myomectomy, metroplasty, hysteroscopy and even manual removal of the placenta (1).

We have obtained diverse findings about the association between the number of previous cesarean deliveries and subsequent cesarean scar ectopic pregnancies. Sadeghi et al. and Ash et al. have shown no association between the number of previous cesarean deliveries and subsequent cesarean scar ectopic pregnancies (4, 5). More than half of all cases of cesarean scar ectopic pregnancies were in woman with only one prior cesarean delivery (4). Although some authors have claimed that the risk of cesarean scar ectopic pregnancies is increased in women with more than three previous cesarean deliveries (6, 7) despite the fact that no statistically important difference exists between groups of patients after one and two CS (5). The time interval from the last CS to the diagnosis of CSP has ranged from six months to 12 years (2,8). CSP has been reported after IVF and embryo transfer as well as spontaneous pregnancy (7).

Today, serial serum hCG measurements and transvaginal ultrasound examination can provide early detection of most ectopic pregnancies, thus allowing for medical treatment with methotrexate.

In those who require surgery, the type of procedure depends on the clinical situation and the location of the pregnancy (9).

Diagnosis of CSP is relatively easy in the early weeks of pregnancy, but as the pregnancy progresses the distinction between CSP, cervical pregnancy, a lowly implanted intrauterine pregnancy and spontaneous miscarriage in progress becomes more difficult. Implantation of a pregnancy within the scar of a previous CS is different from an intrauterine pregnancy with placenta accreta. In CSP, the gestation sac is completely surrounded by the myometrium and the fibrous tissue of the scar, quite separate from the endometrial cavity. transvaginal sonography (TVS) combined with color flow Doppler provides high diagnostic accuracy with very few false positives. Doppler can show a distinct circular peritrophoblastic perfusion surrounding the gestational sac that can help delineate the CSP sac with location of the placenta in relation to the scar and proximity to the bladder (3, 10, 11). Three-dimensional ultrasound also in combination with the multiplanar views and surface-rendered images helps identify subtle anatomical details of a well-developed trophoblastic shell around the gestational sac (12, 13). Magnetic resonance imaging (MRI) has been used as an adjunct to the ultrasound scan. Many authors do not routinely recommend MRI, but it is reserved for cases where TVS and color flow Doppler are inconclusive (1, 2, 14).

Ravhon et al. have proposed that since the placenta is implanted on mainly fibrous tissue, abortion of gestational sac is slow (15).

Post-treatment surveillance should include serial clinical examinations, serum β -hCG measurements until undetectable (defined as ≤ 5 mIU/mL) and repeat ultrasound examinations as indicated, especially if the patient is symptomatic. According to follow-up data from patients, 20.5% of these were complicated by recurrence of a cesarean scar ectopic pregnancy (4).

References

1. Ash A, Smith A, Maxwell D. Cesarean scar pregnancy. *BJOG*. 2007; 114(3): 253-263.
 2. Weimin W, Wenqing L. Effect of early pregnancy on a previous lower segment cesarean section scar. *Int J Gynaecol Obstet*. 2002; 77(3): 201-207.
 3. Seow KM, Cheng WC, Chuang J, Lee C, Tsai YL, Hwang JL. Methotrexate for cesarean scar pregnancy after in vitro fertilization and embryo transfer. A case report. *J Reprod Med*. 2000; 45(9): 754-757.
 4. Sadeghi H, Rutherford T, Rackow BW, Campbell KH, Duzyj CM, Guess MK, et al. Cesarean scar ectopic pregnancy: case series and review of the literature. *Am J Perinatol*. 2010; 27(2): 111-120.
 5. Seow KM, Huang LW, Lin YH, Lin MY, Tsai YL, Hwang JL. Cesarean scar pregnancy: issues in management. *Ultrasound Obstet Gynecol*. 2004 ; 23(3): 247-253.
 6. Ofili-Yebovi D, Ben-Nagi J, Sawyer E, Yazbek J, Lee C, Gonzalez J, et al. Deficient lower-segment cesarean section scars: prevalence and risk factors. *Ultrasound Obstet Gynecol*. 2008; 31(1): 72-77.
 7. Armstrong V, Hansen WF, Van Voorhis BJ, Syrop CH. Detection of cesarean scars by transvaginal ultrasound. *Obstet Gynecol*. 2003; 101(1): 61-65.
 8. Zimmer M, Pomorski M, Fuchs T, Tomiałowicz M, Michniewicz J, Wiatrowski A, et al. Ultrasonographic analysis of cesarean scars features in nonpregnant uterus. *Ginekol Pol*. 2007; 78(11): 842-846.
 9. Arslan M, Pata O, Dilek TU, Aktas A, Aban M, Dilek S. Treatment of viable cesarean scar ectopic pregnancy with suction curettage. *Int J Gynaecol Obstet*. 2005; 89(2): 163-166.
 10. Godin PA, Bassil S, Donnez J. An ectopic pregnancy developing in a previous caesarian section scar. *Fertil Steril*. 1997; 67(2): 398-400.
 11. Vial Y, Petignat P, Hohlfeld P. Pregnancy in a cesarean scar. *Ultrasound Obstet Gynecol*. 2000; 16(6): 592-593.
 12. Shih JC. Cesarean scar pregnancy: diagnosis with three-dimensional (3D) ultrasound and 3D power doppler. *Ultrasound Obstet Gynecol*. 2004; 23(3): 306-307.
 13. Wang CJ, Yuen LT, Yen CF, Lee CL, Soong YK. Three-dimensional power Doppler ultrasound diagnosis and laparoscopic management of a pregnancy in a previous cesarean scar. *J Laparoendosc Adv Surg Tech A*. 2004 ;14(6): 399-402.
 14. Maymon R, Halperin R, Mendlovic S, Schneider D, Herman A. Ectopic pregnancies in a Cesarean scar: review of the medical approach to an iatrogenic complication. *Hum Reprod Update*. 2004; 10(6): 515-523.
 15. Ravhon A, Ben-Chetrit A, Rabinowitz R, Neuman M, Beller U. Successful methotrexate treatment of a viable pregnancy within a thin uterine scar. *Br J Obstet Gynaecol*. 1997; 104(5): 628-629.
-

Archive of SID