

**Case Report****Root Canal Treatment of a Maxillary Second Molar with Two Palatal Canals:  
a Case Report**

MohammadReza Nabavizadeh <sup>a</sup>, Abbas Abbaszadegan <sup>a</sup>, Hosein Mirhadi <sup>a</sup>, Yasmin Ghahramani <sup>a</sup>

<sup>a</sup> Dept. of Endodontics, School of Dentistry, Shiraz University of Medical Sciences, Shiraz, Iran.

**KEY WORDS**

Maxillary Second Molar;  
Two Palatal Canals;  
Root canal therapy

Received October 2014;  
Received in revised form December 2014;  
Accepted January 2014;

**ABSTRACT**

Careful understanding of internal anatomy of root canal system is crucial for successful endodontic treatment. The presence of two palatal canals in maxillary second molar is unusual but noteworthy as an aid to appropriate diagnosis and treatment. This paper reported a case of a maxillary right second molar with two root canals in the palatal root. The root canal treatment and case management were also explained.

**Corresponding Author:** Ghahramani Y., Dept. of Endodontics, School of Dentistry, Shiraz University of Medical Sciences, Shiraz, Iran. Tel:+98-71-36289660 Email: [ghahramani.yas@gmail.com](mailto:ghahramani.yas@gmail.com)

**Cite this article as:** Nabavizadeh M., Abbaszadegan A., Mirhadi H., Ghahramani Y. Root Canal Treatment of a Maxillary Second Molar with Two Palatal Canals: a Case Report. *Dent Shiraz Univ Med Sci.*, December 2015; 16(4): 371-373.

**Introduction**

A thorough knowledge of the root morphology and canal anatomy is mandatory to achieve the main objectives of root canal treatment, such as pain relief, root canal disinfection and prevention of reinfection. On the other hand, insufficient understanding of the canal morphology may lead to many of the challenges faced during root canal treatment.

While it is common for maxillary second molars to have 3 roots with 3 canals, additional palatal canals are more common in maxillary first molars. [1-8] A single palatal root with two canals or two separate palatal roots have been described in these teeth in the literature. However, there were few clinical case reports exhibiting the presence of extra palatal canals and/or roots in maxillary second molars. [8-13] For instance, in the comprehensive studies performed by Shalabi, Green, and Vertucci, the presence of two palatal root canals in maxillary second molars has not been reported. [14-16]

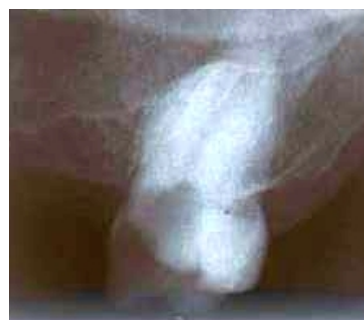Christi et al. reported 14 cases of maxillary second molar with two palatal roots over 40 years. [17] In 2012, Ghodduzi et al. reported a case of maxillary second molars that had two palatal canals. [18] A case of bilateral four-rooted maxillary second molar with two buccal and two palatal roots was reported by Alani in 2003. [19]

The aim of the present report was to describe nonsurgical endodontic treatment of a maxillary second molar with two palatal canals.

**Case Report**

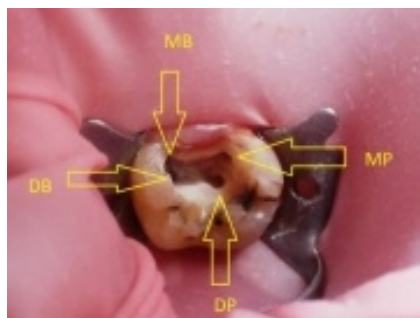
A 52-year-old male patient with no history of systemic diseases was directed to the Department of Endodontics at Shiraz University of Medical Sciences for spontaneous pain in the maxillary right second molar. The pain steadily increased in intensity from mild to moderate, lasting for a few minutes.

Examination showed that all teeth in the maxillary right posterior quadrant were extracted except the mentioned tooth. The patient did not indicate any history of trauma to the head region. Clinical and radiographic inspection of the maxillary right second molar revealed deep occlusal caries (Figure 1) with severe pain on probing by explorer.



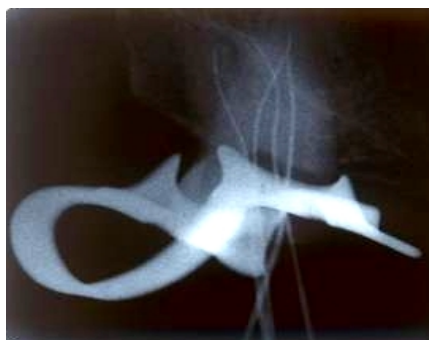**Figure 1:** Initial radiograph of maxillary second molar

These findings and pulp vitality tests led to the diagnosis of irreversible pulpitis, requiring root canal therapy. After anesthetizing the affected tooth and isolating it with a rubber dam, the standard access opening was prepared using a round diamond bur (No.4, MANI Inc.; Tochigi-Ken, Japan). Four canal orifices, two on each of the buccal and palatal canals, were confirmed by clinical evaluation of chamber floor. (Figure 2)



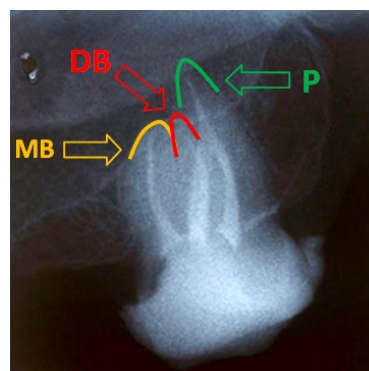
**Figure 2:** Access cavity with demonstrating arrows (MP: Mesiopalatal, DP: Distopalatal, MB: Mesiobuccal, DB: Distobuccal)

An Apex locator (Root ZX; Morita, Tokyo, Japan) was used to estimate the working length of each canal. These lengths were confirmed by conventional intraoral periapical radiography. (Figure 3)



**Figure 3:** Working Length determination radiograph with four K-files.

NiTi rotary ProTapers and 5.25% NaOCl were employed to prepare and clean the root canals. Then, the canals were obturated by using cold lateral condensation technique with AH26 sealer (Dentsply DeTrey; Konstanz, Germany) and gutta-percha cones on the same visit. (Figure 4) After the temporary restoration of the access cavity with temporary filling material (Cavit; 3M, ESPE), the patient was referred for permanent restoration.



**Figure 4:** Final obturation. Yellow arrow shows the mesiobuccal apex, red and green arrows determine the distobuccal and palatal apices, respectively. Distopalatal and mesio-palatal canals merged into one apex.

**Discussion**

Peikoff et al. [20] reported six variations of a second maxillary molar in a retrospective study as Three distinct roots and canals (56%), three separate roots and four canals (two mesiobuccal canals) (22.7%), three roots and canals uniting mesiobuccal and distobuccal canals (9%), two separate roots and canals (6.9%), a single root with one canal (3.1%), and four roots or canals including two palatal canals (1.4 %).

According to this classification, our report falls into the latter group. The palatal root had two canals merging to one apex (type II Vertucci). Such cases have already been reported by Benenati [9] describing root canal therapy of an intact permanent maxillary second molar with two separate palatal canals and a palatogingival groove. Almeida et al. [11] reported a case of two palatal root canals in a maxillary second molar that was endodontically treated. Eskandarinezhad and Ghasemi [13] described non-surgical retreatment of maxillary second molar with two palatal root canals.

Palatal orifices in our report were located wider than that of the buccal orifices. This anatomic feature appears to be like the clinical photograph in the previous studies. [19, 21-22] Although radiographic evaluation is effective for locating anatomic variations, for the present case, the initial radiograph failed to detect two palatal canals.

Posterior location and superimposition of the anatomic structures on the radiographs are two important reasons for the possibility of failure to diagnose a second palatal root canal.

Owing to the challenges in interpreting the morp-

hologic variations on radiographs, the use of operating microscope, visualization techniques, cone beam or spiral computed tomography scan are recommended.

### Conclusion

The possibility of two palatal canals should be scrutinized in second maxillary molars.

### Conflict of Interest

The authors of this manuscript certify that they have no conflict of interest regarding this research.

### References

- [1] Beatty RG. A five-canal maxillary first molar. *J Endod.* 1984; 10: 156-157.
- [2] Gopikrishna V, Reuben J, Kandaswamy D. Endodontic management of a maxillary first molar with two palatal roots and a single fused buccal root diagnosed with spiral computed tomography - a case report. *Oral Surg Oral Med Oral Pathol Oral Radiol Endod.* 2008; 105: e74-e78.
- [3] Aggarwal V, Singla M, Logani A, Shah N. Endodontic management of a maxillary first molar with two palatal canals with the aid of spiral computed tomography: a case report. *J Endod.* 2009; 35: 137-139.
- [4] Baratto-Filho F, Fariniuk LF, Ferreira EL, Pecora JD, Cruz-Filho AM, Sousa-Neto MD. Clinical and macroscopic study of maxillary molars with two palatal roots. *Int Endod J.* 2002; 35: 796-801.
- [5] Bond JL, Hartwell G, Portell FR. Maxillary first molar with six canals. *J Endod.* 1988; 14: 258-260.
- [6] Kottoor J, Velmurugan N, Sudha R, Hemamalathi S. Maxillary first molar with seven root canals diagnosed with cone-beam computed tomography scanning: a case report. *J Endod.* 2010; 36: 915-921.
- [7] Stone LH, Stroner WF. Maxillary molars demonstrating more than one palatal root canal. *Oral Surg Oral Med Oral Pathol.* 1981; 51: 649-652.
- [8] Holderrieth S, Gernhardt CR. Maxillary molars with morphologic variations of the palatal root canals: a report of four cases. *J Endod.* 2009; 35: 1060-1065.
- [9] Benenati FW. Maxillary second molar with two palatal canals and a palatogingival groove. *J Endod.* 1985; 11: 308-310.
- [10] Badole GP, Bahadure RN, Warhadpande MM, Kubde R. A rare root canal configuration of maxillary second molar: a case report. *Case Rep Dent.* 2012; 2012: 767582.
- [11] de Almeida-Gomes F, Maniglia-Ferreira C, dos Santos RA. Two palatal root canals in a maxillary second molar. *Aust Endod J.* 2007; 33: 82-83.
- [12] Pasternak Júnior B, Teixeira CS, Silva RG, Vansan LP, Sousa Neto MD. Treatment of a second maxillary molar with six canals. *Aust Endod J.* 2007; 33: 42-45.
- [13] Eskandarinezhad M, Ghasemi N. Nonsurgical endodontic retreatment of maxillary second molar with two palatal root canals: a case report. *J Dent Res Dent Clin Dent Prospects.* 2012; 6: 75-78.
- [14] al Shalabi RM, Omer OE, Glennon J, Jennings M, Claffey NM. Root canal anatomy of maxillary first and second permanent molars. *Int Endod J.* 2000; 33: 405-414.
- [15] Green D. Morphology of the pulp cavity of the permanent teeth. *Oral Surg Oral Med Oral Pathol.* 1955; 8: 743-759.
- [16] Vertucci FJ. Root canal anatomy of the human permanent teeth. *Oral Surg Oral Med Oral Pathol.* 1984; 58: 589-599.
- [17] Christie WH, Peikoff MD, Fogel HM. Maxillary molars with two palatal roots: a retrospective clinical study. *J Endod.* 1991; 17: 80-84.
- [18] Shojaeian S, Ghodousi J, Hajian S. A case report of maxillary second molar with two palatal root canals and a furcal enamel pearl. *Iran Endod J.* 2013; 8: 37-39.
- [19] Alani AH. Endodontic treatment of bilaterally occurring 4-rooted maxillary second molars: case report. *J Can Dent Assoc.* 2003; 69: 733-735.
- [20] Peikoff MD, Christie WH, Fogel HM. The maxillary second molar: variations in the number of roots and canals. *Int Endod J.* 1996; 29: 365-369.
- [21] Patel S, Patel P. Endodontic management of maxillary second molar with two palatal roots: a report of two cases. *Case Rep Dent.* 2012; 2012: 590406.
- [22] Shin SJ, Park JW, Lee JK, Hwang SW. Unusual root canal anatomy in maxillary second molars: two case reports. *Oral Surg Oral Med Oral Pathol Oral Radiol Endod.* 2007; 104: e61-65.