Original Article

Efficacy of Human Umbilical Stem Cells Cultured on Polylactic/ Polyglycolic Acid Membrane in the Treatment of Multiple Gingival Recession Defects: a Randomized Controlled Clinical Study

Kushal Zanwar [1], Kiran Kumar Ganji [2], Manohar L Bhongade [1]

[1] Dept. of Periodontics, Sharad Pawar Dental College, Wardha, India Affifilated to Datta Meghe Institute of Medical Sciences, Nagpur, India.
[2] Dept. of Periodontics, College of Dentistry, Sakaka Affifilated to Aljouf University, Aljouf Province, KSA.

KEY WORDS
PLA/PGA membrane;
Stem cells;
Gingival recession;

Received October 2015;
Received in Revised form July 2016;
Accepted September 2016;

ABSTRACT

Statement of the Problem: Recently allogenic mesenchymal stem cells are proposed to have multipotential progenitor cell capabilities to differentiate into cementoblasts, osteoblasts, and periodontal ligament fibroblasts.

Purpose: The aim of the present study was to compare the efficacy of human umbilical stem cells cultured on polylactic acid (PLA), polyglycolic acid (PGA) membrane with PLA/PGA membrane alone in the treatment of multiple gingival recession defects.

Materials and Method: A total number of 14 cases of multiple gingival recession (Miller's Class I or II) located in the anterior region were randomly selected and divided into test (stem cells in combination with PLA/PGA membrane) and control group (PLA/PGA membrane alone). Clinical parameters including gingival recession, probing pocket depth, clinical attachment level, and width of keratinized gingiva were recorded at baseline, and at 6 months postoperative.

Results: At baseline, there was 2.28 mm and 2.14mm mean gingival recession at 16 sites and 14 sites in test and control groups respectively. At 6 months post-surgery, test group showed 1.57 mm mean reduction of gingival recession indicating 66% root coverage, while the control group showed 1.24mm mean reduction of gingival recession indicating 57% root coverage.

Conclusion: In the present study, the stem cell with PLA/PGA membrane showed significantly higher mean root coverage compared to only PLA/PGA membrane group.

Corresponding Author: Kiran Kumar Ganji, Dept. of Periodontics, College of Dentistry, Sakaka Affifilated to Aljouf University, Aljouf Province, KSA. Tel: +966540640338 Email: kiranperio@gmail.com

Cite this article as: Zanwar K., Kumar Ganji K., Bhongade ML. Efficacy of Human Umbilical Stem Cells Cultured on Polylactic/ Polyglycolic Acid Membrane in the Treatment of Multiple Gingival Recession Defects: a Randomized Controlled Clinical Study. *J Dent Shiraz Univ Med Sci.,* 2017 June; 18(2): 95-103.

Introduction

Gingival recession defects present both functional and aesthetic problems that require effective treatment to achieve long-term positive clinical outcomes. Many techniques have been developed to deal with this problem, including the use of pedicle flaps, [1-3] free gingival grafts, [4] allografts, [5] and connective tissue grafts with pedicle flaps. [6-8] The use of a subepithelial connective tissue graft (SCTG) is the most widely used, most predictable technique and considered the gold standard in recession management. [9] Although effective, it requires a second surgical site (palate) and only a finite amount of donor tissue is available. Thus, an alternative to SCTG is desired. Since, the early 1990's clinician have shown increasing interest in root coverage techniques based on the principle of guided tissue regeneration (GTR) [10-12] with the purpose of a more stable root coverage and healing by the formation of new cementum, periodontal ligament and bone over the exposed root surface. [13] In a recent meta-analysis, 40 investigations in which GTR was applied for root coverage were reviewed. [10] An average of 75% of exposed roots was covered, with complete coverage in 42% of the treated sites. The GTR technique of using polylactic acid (PLA), polyglycolic acid (PGA) bioabsorbable membrane doesn't require a second surgical procedure for its removal and previous studies have demonstrated that PLA/PGA is biocompatible, nonallergic and does not produce any inflammatory response. However, it has been claimed that the healing of periodontal defects using GTR therapy occurs by new attachment. [14] Therefore, periodontal regeneration in the context of GTR therapy in the management of gingival recession needs to be evaluated further with more randomized controlled clinical trials. [15]

Recently, McAlliste [16] used commercially available allogenic mesenchymal stem cells for the treatment of periodontal defects in human and reported significant radiographic defect fill at 6 months post surgery in infrabony defects. Allogenic mesenchymal stem cells (MSCs) are multipotential nonhematopoietic progenitor cell capable of differentiating into cementoblasts, osteoblast, and periodontal ligament fibroblast. [17] Because of their low immunogenicity due to their lacking expression of co-stimulator molecule, they are able to escape alloantigen recognition. In addition, MSCs can inhibit immune response *invitro* and *invivo* in a dose-dependent non-human leukocyte antigen (HLA) restricted manner. [18-19] These properties make allogenic MSCs promising candidate cells for tissue regeneration. The favorable results of the studies on GTR in the treatment of gingival recession defects, the combination of the bioresorbable membrane with allogenic stem cells for the treatment of multiple gingival recession defects may provide favorable root coverage by true periodontal regeneration. Therefore the present randomized controlled clinical study was undertaken to evaluate the effectiveness of human umbilical stem cells in combination with bioresorbable PLA/PGA membrane under coronally positioned flap and compared with PLA/PGA membrane alone in the treatment of multiple marginal tissue recession.

Materials and Method

Fourteen systemically healthy patients aged between 18 to 35 years with multiple gingival recession defects on the labial or buccal surface of the teeth were selected from the outpatient department of Periodontics, Sharad Pawar Dental College, Sawangi (Meghe), Wardha. The patients fulfilling following criteria were included in the study. Patients having either Miller's Class I or II gingival recession, radiographic evidence of sufficient interdental bone (the distance between the crestal bone and cementoenamel junction as ≤ 2mm), presence of width of keratinized gingiva apical to recession ≥ 3mm with adequate vestibular depth were included in the study and patients with thin gingival biotype, malposition of teeth, unacceptable oral hygiene, using tobacco products, pregnant lady or lactating mother were excluded. Prior to initiating this study, the purpose and design of this clinical trial was explained to the patients and agreed to participate during the entire period of study. This study was approved by an Ethical Committee, Datta Meghe Institute of Medical Sciences, Sawangi, Wardha.

Study Design

A randomized parallel single blinded designed controlled clinical study was performed over six month period. Each patient with minimum two adjacent recession defects was included in the study. Prior to surgery, the patients were randomly assigned by a coin flip to the stem cell in combination with PLA/PGA membrane (test group) and only PLA/PGA membrane (control group) with both groups consisting of 7 patients each.

Isolation and culture of mesenchymal stem cell

Human umbilical cord was collected from the hospital in a sterile tube and then isolated and cultured by the international stem cell services (Shri Raghvendra Biotechnology Pvt. Ltd. Bangalore). The cord was washed properly such as to clean up the blood from the cord. The cord was surface sterilized by 70% ethanol and then chopped into pieces of 2 inches. The Wharton's jelly was opened and the cord tissue was subjected to enzymatic treatment with collagenase Type II. The cell suspension was taken and was washed twice with ringer lactate. The cells were plated in a T75 flash with Stem Pro MSC SFM media. After 3 days the media was replaced. The flask was kept in cultured until confluence. The cells in the flask were then subjected for trypsinization. The cells were counted and then cultured for 3days on the scaffold (PLA/PGA bioresorbable membrane; BioMesh - S®, Samyang corp, Korea) of 3X4 cm which

www.SID.ir

was provided 10 days before proposed date of the surgical procedure, to the international stem cell services. The stem cells were cryopreserved with different media containing dimethyl sulfoxide, patient's serum and human albumin. The viability of the cells was studied by dye exclusion method and motility. An estimated count of 5 lakh stem cells per mm^2 on the membrane was considered as acceptable for the membrane to be used in the surgical procedure.

Initial therapy

Every patient was received initial therapy consisting of oral hygiene instructions, scaling and root planning, professional polishing with the use of rubber cup and a low abrasive polishing paste. Occlusal adjustments were done if needed. A modified Stillman's brushing technique will be prescribed for teeth with recession -type defects in order to minimize tooth brushing trauma.

If needed, additional professional oral hygiene procedures were carried out and oral instructions reinstituted to achieve plaque scores of ≤ 1. Further needed dental treatments were also being carried out. All patients were asked to sign a written consent form and should agree to participate during the entire period of study.

Clinical Measurements

Before anesthesia, on the day of the surgical procedure, 3 months and 6 months later, full-mouth plaque scores were recorded using the plaque index by Turkey- Gilmore- Glickman modification of Quigley-Hein [20] while gingival inflammation was assessed using gingival bleeding point index by Lenox and Kopczyk. [21]

The following clinical parameters were measured for assessment of the results in all the treated cases: probing pocket depth (PPD), clinical attachment level (CAL), gingival recession (GR) and width of keratinized gingiva (WKG) by using a UNC-15 periodontal probe (PCP-UNC 15 probe tip; Hu-Friedy, Chicago, IL). All the probing measurements were recorded at maximum depth recession (mid-facially per tooth). These measurements were recorded only on teeth to be treated at baseline and 6 months postoperatively. Baseline clinical parameters were recorded 6 weeks after initial therapy.

Surgical procedure

Prior to the surgical procedure, the patients were instructed to rinse with 0.2% chlorhexidine gluconate (Hexidine-ICPA Health Product Ltd., India) for one minute. The surgical protocol would emphasize complete asepsis and infection control. After induction of local anesthesia (2% lidocaine, epinephrine 1: 100,000), the exposed root surfaces were carefully planned with ultrasonic instruments followed by curettes.

Preparation of recipient site

The intra-sulcular incision was made at the buccal/labial aspect of the involved teeth and the incision was extended horizontally into the adjacent interdental areas, at the level slightly coronal to the cementoenamel junction without interfering with the gingival margin of the neighboring teeth. Two oblique vertical incisions mesial and distal to the selected sites were given extending beyond the mucogingival junction and a trapezoidal mucoperiosteal flap was raised up to the mucogingival junction. After this point, a split thickness flap was extended apically beyond the mucogingival junction releasing the tension and favoring the coronal positioning of the flap. The epithelium from the adjacent papillae was stripped away so as to create a connective tissue bed for suturing the coronally positioned flap. The root surface was instrumented with curettes and washed with saline solution.

A sterile template (aluminum foil) was utilized to obtain the approximate dimension of the recipient site. Using the surgical template, stem cell cultured PLA/PGA membrane was trimmed and placed extending 1 mm apical to CEJ and covering 2 to 3 mm on mesial, distal and apical to the recession area and sutured in place by using continuous sling sutures with the help of resorbable sutures (4-0 absorbable surgical suture; braided black silk, Vicryl, Ethicon, Johnson & Johnson Ltd.). The flap was carefully placed over the site, ensuring the membrane was not moved. The flap was coronally repositioned in such a way that the flap margin was located 1mm coronal to CEJ, thereby completely covering the membrane. The flap was then sutured by using continuous sling sutures (4-0 Non-absorbable surgical suture; braided black silk, Mersilk, Ethicon, Johnson & Johnson Ltd.). Surgical procedure for the control group (Figure 1a-1e) was same as that of the test group (Figure 2a-2e) except for the omission of stem cell in the membrane. Immediately after surgery, periodontal dressing (Coe-Pak; GC America, Alsip, IL, USA) was placed on the recipient site as well as a donor site.

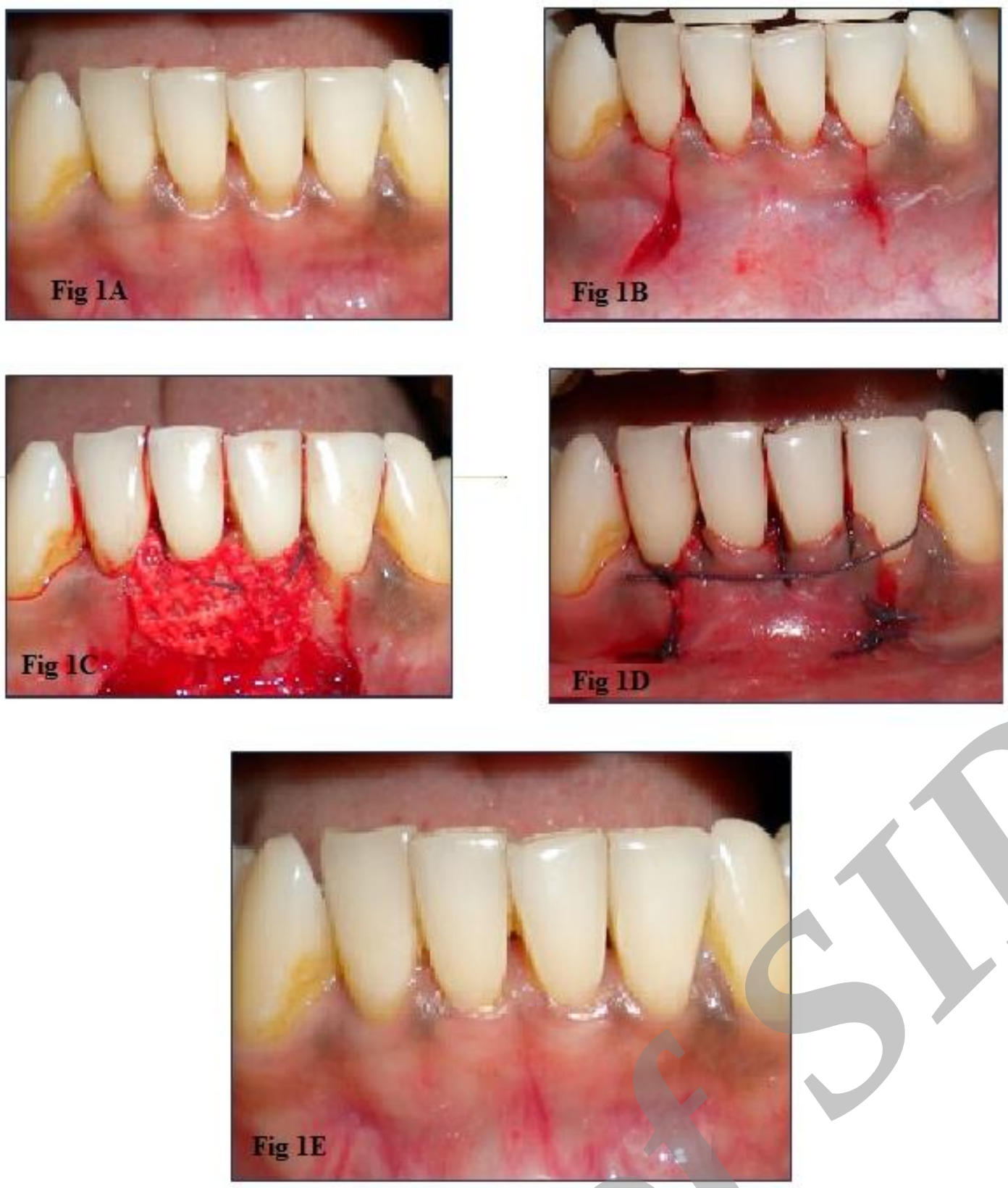

Figure 1a: Pre- operative view with recession in #31 & #41 region, **b:** Releasing incision at recipient site, **c:** PLA/PGA membrane stabilized at the recipient site, **d:** Sutures placed at the operated site, **e:** Post-operative view after 6 months.

Post-operative care

Patients were instructed to refrain from brushing and flossing around the surgical area until suture removal (14 days post-surgery) and to consume only soft foods

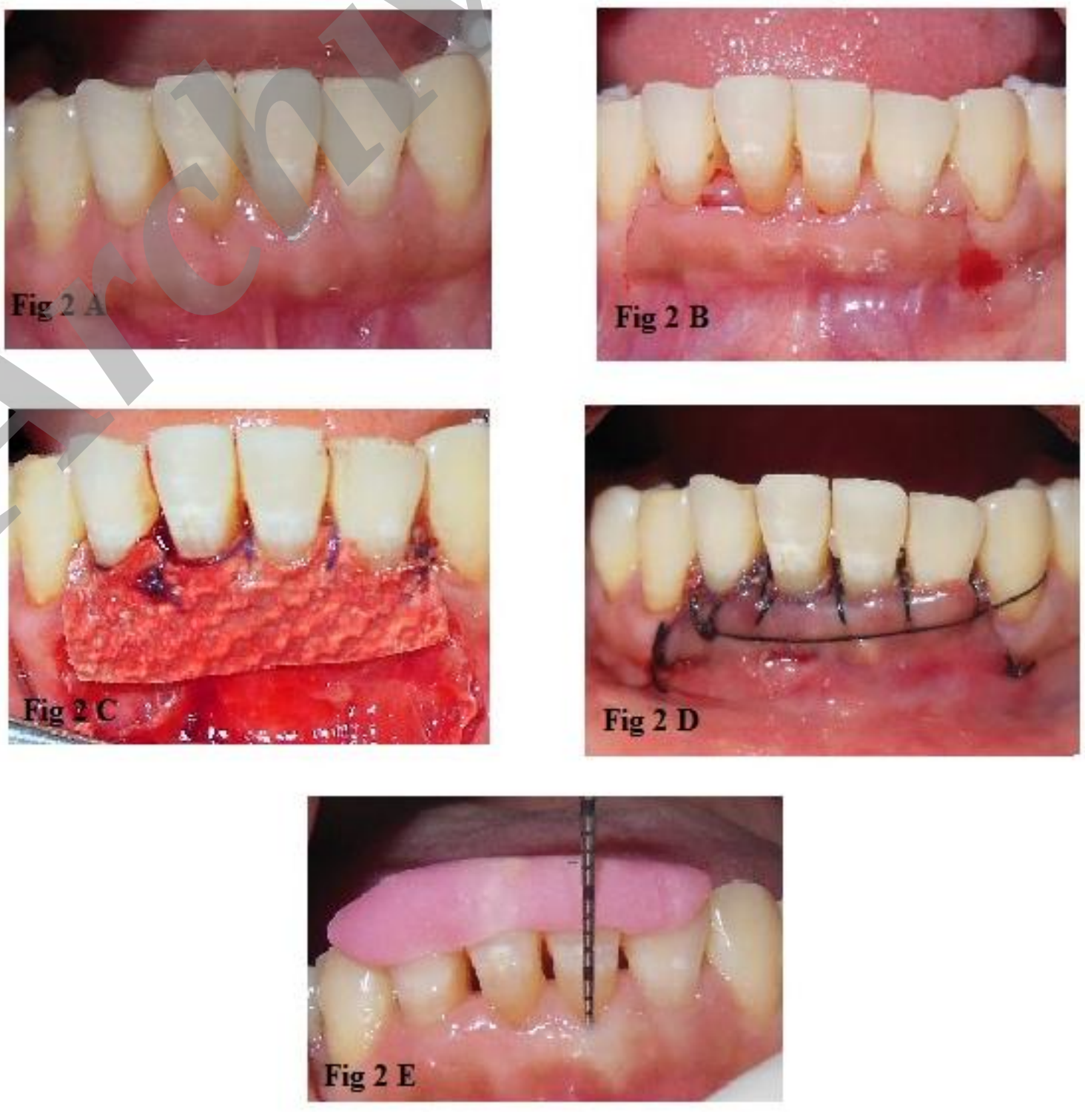

Figure 2a: Pre- operative view with gingival in #31 & #41 region, **b:** Releasing incision extending beyond muco-gingival junction, **c:** Stem cells impregnated PLA/PGA membrane stabilized at the recipient site, **d:** Sutures placed to cover the membrane, **e:** Post-operative view after 6 months.

Table 1: Comparison of mean full mouth plaque index (FMPI) and gingival bleeding point index (GBI) percentage between baseline, 3 months and 6 months follow-up for stem cell in combination with PLA/PGA membrane(test group) and PLA/PGA membrane alone (control group).

		(MV± SD)		
Parameters	**Groups**	**Baseline**	**3 Months**	**6 Months**
FMPI	Test	0.41±0.06	0.18±0.04	0.28±0.048
	Control	0.38±0.05	0.16±0.06	0.30±0.03
GBI (percentage)	Test	34.33±7.34%	20.41±6.24%	27.50±6.84%
	Control	35.41±5.55%	15.50±3.17%	25.08±4.03%

during the first week after surgery. Patients were also instructed to avoid any mechanical trauma to treated sites. For 4 weeks, patients used a 0.12% chlorhexidine solution rinse for 1 minute twice daily.

Statistical Analysis

The means and standard deviation (Mean±SD) values were calculated for all clinical parameters including PPD, CAL, GR, and WKG. The mean data was analyzed for the statistical significance by the standard statistical method. Student's paired t-test was used to compare data from baseline to those at 6 months for each treatment group. A comparison between treatment groups at baseline and 6 months was accomplished with student's unpaired t-test. If the probability value (*p*) was more than 0.05, the difference observed was considered non-significant and if less than 0.05, it was considered significant.

Results

The mean full mouth plaque index score at baseline was 0.41±0.06 and 0.38±0.05 for the test and control group respectively. There was statistically significant decrease in plaque score at 3 months and 6 months compared to baseline in both the groups. The mean PI scores during 6 months period remained below score 1 (Table 1). At baseline, the GBI percentage was 34.33± 7.34% and 35.41±5.55% for test and control group respectively. Gingival bleeding point index scores, when compared with baseline measurements versus 3 months and 6 months post-surgical measurements by using paired t-test, we observed statistically significant reduction in gingival bleeding point index percentage at 3 and 6 months post-surgery ($p< 0.05$), indicating improvement in gingival condition throughout the study period (Table 1).

Mean values for all the clinical parameters at baseline and 6 months for test and control group were reported in Table 2 and 3, while the comparison between the groups was reported in Table 4 and 5. Both test and control group showed a significantly greater reduction in gingival recession (1.57±0.89mm and 1.24±0.47 mm respectively) at 6 months postoperatively ($p< 0.05$), when to mean gingival recession reduction in the test group compared with the control group a non-significantly greater reduction was demonstrated in the test group. Similarly, when the comparison was made for mean root coverage between test group and control group at 6 months, significantly higher root coverage was observed in the test group (66.26% Vs 57.38%). (Table 5) CAL gain was also greater in the test group (1.78±1.1 mm) as compared to control group (1.74±0.62 mm) and a statistically non-significant difference was found between test and control group (Table 4). Mean PPD reduction was 0.35±0.37mm and 0.42±0.34 mm in test and control group respectively and mean an increase in WKG was 0.74± 0.75mm in the test group and 0.78±0.56 mm in the control group at 6 months postoperatively. When comparison was made between test and control group statistically non-significant difference was observed in both PPD reduction and WKG increase (Table 4).

In the test group, on an average 66.26±26.95 % of the root surfaces initially exposed due to the recession were covered with soft tissue at 6 months post-surgery.

Table 2: Comparison of clinical parameters between baseline and 6 months follow-up for Stem cell in combination with PLA/ PGA membrane group (MV± SD; in mm)

Parameters	**Baseline**	**6 months**	**Difference**	**p-value**
PPD (Range)	1.5±0.5 (1-2)	1.14±0.24 (1-1.5)	0.35±0.37 *(Reduction)*	0.11*
CAL (Range)	3.78±0.95 (2.5-5)	1.99±0.83 (1-3.5)	1.78±1.1 *(CAL Gain)*	0.002[†]
GR (Range)	2.28±0.56 (1.5-3)	0.71±0.59 (0-1.5)	1.57±0.89 *(Reduction)*	0.000[†]
WKG (Range)	3.54±1.06 (2-5.5)	4.28±1.25 (3-7)	0.74±0.75 *(Gain)*	0.25*

*Non-Significant ($p> 0.05$) [†]Significant ($p< 0.05$)

www.SID.ir

Table 3: Comparison of clinical parameters between baseline and 6 months follow-up in PLA/PGA membrane group.

		(MV± SD; in mm)		
Parameters	**Baseline**	**6 months**	**Difference**	**p-value**
PPD (Range)	1.28±0.26 (1-1.5)	0.85±0.37 (0.5-1.5)	0.42±0.34 (*Reduction*)	0.03†
CAL (Range)	3.42±0.53 (2.5-4)	1.68±0.36 (1-2.5)	1.74±0.62 (*CAL Gain*)	0.000†
GR (Range)	2.14±0.47 (1.5-3)	0.90±0.33 (0-1.5)	1.24±0.47 (*Reduction*)	0.000†
WKG (Range)	3±0.64 (2-4)	3.78±0.48 (3-4.5)	0.78±0.56 (*Gain*)	0.018†

†Significant (*p*< 0.05)

At this point, 7 of the 18 treated recession defects (45.23%) showed complete root coverage. In the control group, on an average 57.38±15.57 % of the root surfaces initially exposed due to the recession were covered with soft tissue at 6 months post-surgery. At this point, 4 of the 17 treated recession defects (21.42%) showed complete root coverage (Table 5).

Discussion

Gingival recession mostly involves a group of adjacent teeth than being localized to a single tooth. When multiple recession defects affecting adjacent teeth in esthetic areas of the mouth are present, they should all be treated at the same time to help ensure the best esthetic results. Therefore, the present controlled parallel design clinical study was carried out to compare the effectiveness of human umbilical stem cell in combination with PLA/PGA membrane and only PLA/PGA membrane for the treatment of multiple gingival recessions. The present clinical study was conducted over a 6- month period. The experimental design included two treatment groups that differed only by the presence of stem cells allowing the evaluation of the influence of the cultured membrane in clinical results and not the surgical technique employed. At baseline, none of the investigated parameters in both the study groups showed any statistical difference, thus ensuring the same starting point for the procedures tested. During the course of the study, wound healing was uneventful. There was no sign of allergy, infection or any other complication in any patient after the use of stem cells, which indicates that the stem cells were well tolerated. There were no post-operative complications in any patients. None of the selected patients dropped out before the termination of the study.

The results presented here indicate that both the treatment modalities showed significant improvement in the studied clinical parameters compared to baseline. At 6 months, statistically, significant reduction in gingival recession was found in both the treated groups (1.57 mm for test group and 1.24 for the control group). In the test group, mean recession defect coverage of 66.26% with 45.23 % of teeth showed complete root coverage. While at the end of 6 months, the control group showed mean recession defect coverage of 57.38% with 21.42 % of teeth showed complete root coverage. The results of the present study on the use of PLA/PGA membrane for the treatment of multiple gingival recession are comparable to those reported by Matarasso *et al.* [22] (73%) and Tatakis *et al.* [23] (58%).

Regeneration of lost tissues in gingival recession has long been an altruistic goal of periodontal therapy.

The application of stem cells in periodontal defects for regeneration in recent years [24, 16] holds promise for the development of novel, more effective approaches to periodontal regeneration during root coverage procedures. Therefore, in the present study human umbilical stem cells cultured on PLA/PGA membrane was used to test its efficacy for the treatment of multiple gingival recession defects to achieve periodontal regeneration. Since no clinical data available in the literature on the use of stem cells in combination with PLA/PGA

Table 4: Comparison of clinical parameters between stem cell in combination with PLA/PGA membrane+CPF group and PLA/ PGA membrane alone at 6 months follow-up.

	(MV ± SD; in mm)		
Parameters	**Stem cell with PLA/PGA membrane + CPF group**	**PLA/PGA membrane group**	***p*-value**
GR reduction	1.57±0.89	1.24±0.47	0.35*
PPD reduction	0.35±0.37	0.42±0.34	0.71*
CAL gain	1.78±1.1	1.74±0.62	0.92*
WKG increase	0.74±0.75	0.78±0.56	0.90*

*Non-Significant (*p*> 0.05)

www.SID.ir

Table 5: Comparison of mean percentage of root coverage corresponding to mean reduction in gingival recession in stem cell in combination with PLA/PGA membrane + CPF group and PLA/PGA membrane group.

Parameters	Stem cell with PLA/PGA membrane+CPF group	PLA/PGA membrane group	*p*-value
GR reduction	1.57±0.89	1.24±0.47	0.35*
Mean root coverage (in %)	66.26±26.95	57.38±15.57	0.001†
Complete root coverage (in %)	45.23±41.62	21.42±20.89	0.36*

*Non-Significant ($p > 0.05$)
†Significant ($p < 0.05$)

membrane for the treatment of multiple gingival recession defects, the results obtained in this group were compared with the studies reported on the use of other regenerative biomaterials for the treatment of multiple gingival recession defects. Koseoglu *et al.* [25] evaluated the effectiveness of collagen membrane in combination with autologous gingival fibroblast prepared by tissue engineering approach under coronally advanced flap for root coverage and observed mean root coverage of 72.39% at 6 months postoperatively.

MSCs appear to be an attractive tool in the context of tissue engineering and cell-based therapy. Mesenchymal stem cells have also been shown to form new cementum, periodontal ligament and alveolar bone in vivo after implantation into periodontal defects in beagle dogs [26-27] suggesting that bone marrow may be a useful source of mesenchymal stem cells for periodontal regeneration. Currently, bone marrow represents the main source of MSCs for both experimental and clinical studies. [28-29] However, the use of bone marrow-derived cells is not always acceptable due to the high degree of viral infection and the significant drop in cell number as well as their relative proliferative/ differentiation capacity. In addition, aspirating bone marrow is an invasive procedure.

Recently MSCs have been isolated from the umbilical cord, placenta, perivascular areas, amniotic fluid, and from the tissue surrounding the umbilical cord vessels, i.e., Wharton's jelly. [30] The collection of MSC-like cells from umbilical cord tissues that are discarded at birth is easier and less expensive. The collection of umbilical cord MSCs (UC-MSCs) does not require any invasive procedure. These cells may be stored frozen and then thawed to provide stem cells for therapeutic use after cryogenic storage. In addition to the well-documented self-renewal and multipotent differentiation properties, UC-MSCs possess immunoregulatory capacities that have been permissive to allogenic transplantation. [31] Given these characteristics, particularly the plasticity and developmental flexibility, the UC-MSCs are now considered an alternative source of stem cells for the long-term clinical trials. [32]

In the present study, CAL gain was non-significant more in test group as compared to control group. The type of healing obtained in human umbilical stem cells cultured on PLA/PGA group between the soft tissue and previously denuded root surface can only be speculated on since no histological evaluation were available due to ethical considerations. Yildirim *et al.* [33] evaluated histologically the osteogenic differentiation potential of human umbilical stromal cells and reliability of these cells for dental tissue engineering. They reported that stem cell populations isolated from the human umbilical cord, have osteogenic differentiation potential and could be a choice in dental tissue engineering applications, based on this observation it may be assumed that the healing following treatment with stem cells in combination with PLA/PGA membrane may represent, a real periodontal regeneration characterized by the formation of new cementum, periodontal ligament, and alveolar bone.

A large number of allogenic stem cells can be derived from a single donor for multiple uses. A potential limitation to this universal donor concept is a rejection of donor cells by the recipient's immune system. However, recently it has been shown that MSCs have the ability to modify and influence almost all the cells of the innate and adaptive immune systems that interfere with and affect cellular proliferation, differentiation, maturation, and function to induce an anti-inflammatory phenotype. [34] MSCs modulate the immune response by soluble factors, including IL-6, M-CSF, IL-10, TGFβ, HGF and PGE2. MSCs have been shown to suppress inflammatory cells like neutrophils, dendritic cells, natural killer (NK) cells, eosinophils, mast cells, and macrophages and alter NK cell phenotype and suppress proliferation, cytokine secretion, and cytotoxicity against HLA class I expressing targets. [35] In this study, GTR

www.SID.ir

membrane (PLA/ PGA membrane) was used as a scaffold for delivery of MSCs. The test group in the study showed mean recession defect coverage of 66.26% with 45.23 % of teeth showed complete root coverage, the mean PPD reduction in test group was 0.35±0.37mm and mean CAL gain in test group was 1.78±1.1mm at 6 months. Results of the present study were in agreement with the similar study by Zanwar claiming stem cells in combination with bioresorbable PLA/PGA membrane resulted in significantly higher CAL gain than subepithelial connective tissue grafts. [34] McAllister [16] claimed 6 mm reduction in probing depth and three-dimensional bone fill when he used stem cell containing allograft.

The allogenic material undergoes a selective immune-depletion process that results in a graft-rich in MSCs and osteoprogenitor cells without cells of hematopoietic lineage. [16] For the delivery of umbilical cord mesenchymal stem cells, different scaffolds were used which includes calcium phosphate cement, electrospun fiber-CPC, chitosan, collagen and different polymers. Scaffolds can deliver cells to the correct site, improve cell survival, enhance cell integration, and direct cell differentiation, thereby; providing a promising platform for cell transplantation.

Conclusion

We conclude that stem cell with PLA/PGA membrane showed significantly higher mean root coverage compared to only PLA/PGA membrane group. Further, long-term studies controlled clinical studies with large sample size and histological evaluation for the mode of attachment need to be performed to quantitatively compare the results to other well-documented treatment approaches.

Acknowledgment

We thank Dr. Pavan Bajaj for helping out in carrying out the statistical analysis.

Conflict of Interest

The authors of this manuscript certify that they have no financial or other competing interest concerning this article.

References

[1] Grupe HE, Warren RF. Repair of gingival defects by a sliding flap operation. J Periodontol. 1956; 27: 92–95.

[2] Cohen DW, Ross SE. The double papillae repositioned flap in periodontal therapy. J Periodontol. 1968; 39: 65-70.

[3] Bernimoulin JP, Lüscher B, Mühlemann HR. Coronally repositioned periodontal flap. Clinical evaluation after one year. J Clin Periodontol. 1975; 2: 1-13.

[4] Sullivan HC, Atkins JH. Free autogenous gingival grafts. 3. Utilization of grafts in the treatment of gingival recession. Periodontics. 1968; 6: 152-160.

[5] Harris RJ. A comparative study of root coverage obtained with an acellular dermal matrix versus aconnective tissue graft: results of 107 recession defects in 50 consecutively treated patients. Int J Periodontics Restorative Dent. 2000; 20: 51-59.

[6] Langer B, Langer L. Subepithelial connective tissue graft technique for root coverage. J Periodontol. 1985; 56: 715-720.

[7] Raetzke PB. Covering localized areas of root exposure employing the "envelope" technique. J Periodontol. 1985; 56: 397-402.

[8] Harris RJ. The connective tissue and partial thickness double pedicle graft: a predictable method of obtaining root coverage. J Periodontol. 1992; 63: 477-486.

[9] Roccuzzo M, Bunino M, Needleman I, Sanz M. Periodontal plastic surgery for treatment of localized gingival recessions: a systematic review. J Clin Periodontol. 2002; 29 Suppl 3: 178-194.

[10] Al-Hamdan K, Eber R, Sarment D, Kowalski C, Wang HL. Guided tissue regeneration-based root coverage: meta-analysis. J Periodontol. 2003; 74: 1520-1533.

[11] Trabulsi M, Oh TJ, Eber R, Weber D, Wang HL. Effect of enamel matrix derivative on collagen guided tissue regeneration-based root coverage procedure. J Periodontol. 2004; 75: 1446-1457.

[12] Trombelli L, Minenna L, Farina R, Scabbia A. Guided tissue regeneration in human gingival recessions. A 10-year follow-up study. J Clin Periodontol. 2005; 32: 16-20.

[13] Cortellini P, Clauser C, Prato GP. Histologic assessment of new attachment following the treatment of a human buccal recession by means of a guided tissue regeneration procedure. J Periodontol. 1993; 64: 387-391.

[14] Schroeder HE. Biological problems of regenerative cementogenesis: synthesis and attachment of collagenousmatrices on growing and established root surfaces. Int Rev Cytol. 1992; 142: 1-59.

[15] Araújo M, Berglundh T, Lindhe J. The periodontal tissues in healed degree III furcation defects. An experimentalstudy in dogs. J Clin Periodontol. 1996; 23: 532-541.

[16] McAllister BS. Stem cell-containing allograft matrix enhances periodontal regeneration: case presentations. Int J Periodontics Restorative Dent. 2011; 31: 149-155.

[17] Lin NH, Gronthos S, Bartold PM. Stem cells and periodontal regeneration. Aust Dent J. 2008; 53: 108-121.

[18] Le Blanc K, Tammik L, Sundberg B, Haynesworth SE, Ringdén O. Mesenchymal stem cells inhibit and stimulate mixed lymphocyte cultures and mitogenic responses independently of the major histocompatibility complex. Scand J Immunol. 2003; 57: 11-20.

[19] Klyushnenkova E, Mosca JD, Zernetkina V, Majumdar MK, Beggs KJ, Simonetti DW, Deans RJ, McIntosh KR. T cell responses to allogeneic human mesenchymal stem cells: immunogenicity, tolerance, and suppression. J Biomed Sci. 2005; 12: 47-57.

[20] Turesky S, Gilmore ND, Glickman I. Reduced plaque formation by the chloromethyl analogue of victamine C. J Periodontol. 1970; 41: 41-43.

[21] Lenox JA, Kopczyk RA. A clinical system for scoring a patient's oral hygiene performance. J Am Dent Assoc. 1973; 86: 849-52.

[22] Matarasso S, Cafiero C, Coraggio F, Vaia E, de Paoli S. Guided tissue regeneration versus coronally repositioned flap in the treatment of recession with double papillae. Int J Periodontics Restorative Dent. 1998; 18: 444-453.

[23] Tatakis DN, Trombelli L. Gingival recession treatment: guided tissue regeneration with bioabsorbablemembrane versus connective tissue graft. J Periodontol. 2000; 71: 299-307.

[24] Yamada K, Yamaura J, Katoh M, Hata K, Okuda K, Yoshie H. Fabrication of cultured oral gingiva by tissue engineering techniques without materials of animal origin. J Periodontol. 2006;77: 672-677.

[25] Köseoğlu S, Duran İ, Sağlam M, Bozkurt SB, Kırtıloğlu OS, Hakkı SS. Efficacy of collagen membrane seeded with autologous gingival fibroblasts in gingival recessiontreatment: a randomized, controlled pilot study. J Periodontol. 2013; 84: 1416-1424.

[26] Hasegawa N, Kawaguchi H, Hirachi A, Takeda K, Mizuno N, Nishimura M, et al. Behavior of transplanted bone marrow-derived mesenchymal stem cells in periodontal defects. J Periodontol. 2006; 77: 1003-1007.

[27] Kawaguchi H, Hirachi A, Hasegawa N, Iwata T, Hamaguchi H, Shiba H, et al. Enhancement of periodontal tissue regeneration by transplantation of bone marrow mesenchymal stem cells. J Periodontol. 2004; 75: 1281-1287.

[28] Deans RJ, Moseley AB. Mesenchymal stem cells: biology and potential clinical uses. Exp Hematol. 2000; 28: 875-884.

[29] Minguell JJ, Conget P, Erices A. Biology and clinical utilization of mesenchymal progenitor cells. Braz J Med Biol Res. 2000; 33: 881-887.

[30] Rao MS, Mattson MP. Stem cells and aging: expanding the possibilities. Mech Ageing Dev. 2001; 122: 713-734.

[31] Baksh D, Yao R, Tuan RS. Comparison of proliferative and multilineage differentiation potential of human mesenchymal stem cells derived from umbilical cord and bone marrow. Stem Cells. 2007; 25: 1384-1392.

[32] Weiss ML, Anderson C, Medicetty S, Seshareddy KB, Weiss RJ, VanderWerff I, et al. Immune properties of human umbilical cord Wharton's jelly-derived cells. Stem Cells. 2008; 26: 2865-2874.

[33] Yıldırım S, Balcı D, Akpınar P, Can A. Differentiation potentials of two stroma-resident tissue-specific stem cells. Niche. 2012; 1: 1–7.

[34] Aggarwal S, Pittenger MF. Human mesenchymal stem cells modulate allogeneic immune cell responses. Blood. 2005; 105: 1815-1822.

[35] Sotiropoulou PA, Perez SA, Gritzapis AD, Baxevanis CN, Papamichail M. Interactions between human mesenchymal stem cells and natural killer cells. Stem Cells. 2006; 24: 74-85.

[36] Zanwar K, Laxmanrao Bhongade M, Kumar Ganji K, B Koudale S, Gowda P. Comparative evaluation of efficacy of stem cells in combination with PLA/PGA membrane versus sub-epithelial connective tissue for the treatment of multiple gingival recession defects: a clinical study. J Stem Cells. 2014; 9: 253-267.