

Original Article

Cone Beam CT Study of Temporal Crest Canal

Mahvash Hasani¹, Shoaleh Shahidi², Shahrzad Alsadat Shamszade³¹ Dept. of Oral and Maxillofacial Radiology, School of Dentistry, Shiraz University of Medical Sciences, Shiraz, Iran.² Dept. of Oral and Maxillofacial Radiology, Biomaterial Research Center, School of Dentistry, Shiraz University of Medical Sciences, Shiraz, Iran.³ Undergraduate students, School of Dentistry, International Branch of Shiraz University of Medical Science, Shiraz, Iran.

KEY WORDS

Cone-Beam Computed Tomography;
Prevalence;
Mandible;Received August 2016;
Received in Revised form November 2016;
Accepted December 2016;

ABSTRACT

Statement of the Problem: It is crucial for clinicians to be certain about the location of mandibular canal and determine any anatomical variants relevant to it. The temporal crest canal (TCC) is a rare anatomical variant of mandibular canal that lack of awareness about its presence can complicate surgical procedures.**Purpose:** This study investigated the anatomical characteristics and prevalence of the TCC using CBCT.**Materials and Method:** This descriptive cross-section study evaluated 327 CBCTs (654 sides) from all the patients with various problems. TCC on sagittal and axial plans were identified and then classified into two types based on their configuration. The prevalence of TCC was calculated amongst men and women.**Results:** Six TCC (0.91%) were observed in 654 sides. We observed all 6 TCCs in females. One case (0.30%) was bilateral TCC, and the remaining four (1.22%) cases were unilateral TCC (two on the left and two on the right side). Considering the classification of TCC, five sides had presentation of type I and one case was type II based on Kawai *et al.* study.**Conclusion:** Three-dimensional images of CBCT data are useful in confirming the presence of TCC. TCC is considered as a clinically significant structure; therefore, this variation should be carefully investigated using reconstructed CBCT images.**Corresponding Author:** Hasani M., Dept. of Oral and Maxillofacial Radiology, School of Dentistry, Shiraz University of Medical Sciences, Shiraz, Iran. Tel: +98-71-36285275 Fax: +98-71-36270325 Email: hasanim8@gmail.comCite this article as: Hasani M., Shahidi Sh., Shamszade Sa. Cone Beam CT Study of Temporal Crest Canal. *J Dent Shiraz Univ Med Sci.*, 2018 March; 19(1): 15-18.

Introduction

The mandibular canal originates from the mandibular foramen and transmits the inferior alveolar artery and nerve to the mental incisive region. [1-3]

The inferior alveolar nerve (IAN) is of particular interest to all who deal with oral maxillofacial surgery. Reliable insight in the three-dimensional relationship of the mandibular third molar root with the mandibular canal is essential to avoid any pressure on the IAN. [4] Moreover, the IAN may be traumatized by an implant intruded into the canal or penetrated by the drill preceding implant placement. [5] In addition, in cases of a bilateral sagittal split osteotomy, three-dimensional information about the IAN may prevent nerve damage du-

ring surgery. [6]

Thereby, before any surgical procedure, it is important for clinicians to be certain about the location of mandibular canal and to determine any anatomical variants relevant to it is of a high importance for clinicians. Mandibular canal as a single structure bears variations such as bifid mandibular canal, retromolar canal and temporal crest canal.

The temporal crest canal begins from accessory foramen in the posterior side of the temporal crest to another accessory foramen in the anterior side of temporal crest, which is the halfway zone between superior side of coronoid process and the third molar crypt (Figure 1). [7-9] Considering its origin and its pathway,

TCC convey all or part of the buccal nerve. Inaccurate diagnoses of these variants can complicate surgical and dental operations that cause lack of anesthesia, hemorrhage and nerve damage. [10-11]

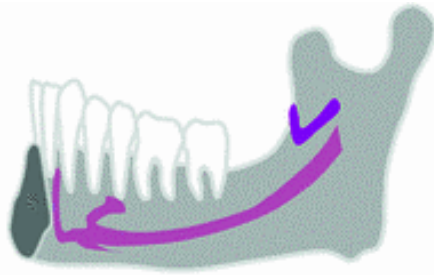


Figure 1: Temporal crest canal

Even though, there have been numerous reports [1, 3, 6-8] about some of these variations in the literature, information about temporal crest canal as a variation in posterior aspect of mandibular canal is still inadequate.

Nowadays, cone beam computed tomography (CBCT) is commonly used to detect oral and maxillofacial abnormalities. In recent years, several studies reported variations of mandibular canal, which were determined by using CBCT images. [7]

The present study was conducted to determine the prevalence and characteristics of temporal crest canal in the CBCT images in private radiology center, Shiraz, Iran.

Materials and Method

A total of 327 cases (654 sides) were selected from all the patients with variety of problems from the files of a private radiology center in Shiraz from September 2014 to April 2015. All Patients with history of maxillofacial trauma and surgeries were excluded from the study.

The CBCT images were obtained from FDP-based CBCT (New Tom VGi, QR SrL, Italy). Each study was performed by observing the following parameters: 110kv, 3mA and total exposure time of 3.5 seconds using 15cm×15cm field of view. The subjects were positioned with the Frankfurt plane parallel to the floor. The analyses were done using New Tom VGi Software on a 17-inch LG monitor (Flatron 55SE) with (1366*768) pixel resolution in semi-dark room. All cases were assessed twice by an intern dentistry student and then by a maxillofacial radiologist to achieve the final decision. Each CBCT was evaluated to feature the presence of this variety.

As mentioned, TCC starts from mandibular foramen or an accessory foramen in the posterior of the temporal crest to another accessory foramen in the anterior of temporal crest. TCC were classified into two types based on the study of Kawai *et al.* study. [10]

The first type is initiated at the mandibular foramen that runs parallel to the mandibular canal, curves in the middle and ends at a foramen on the anterior of the ramus inferior to the coronoid process (Figure 2).

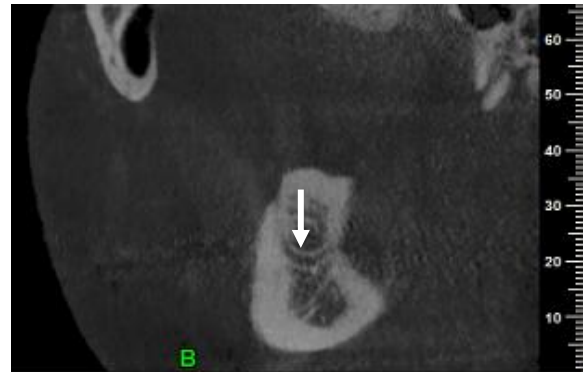


Figure 2: Oblique sagittal images of type 1 temporal crest canal

The second type starts from accessory mandibular foramen near the mandibular foramen that runs anteriorly and inferiorly which ends at the accessory foramen in the antero-inferior region of coronoid process (Figure 3).

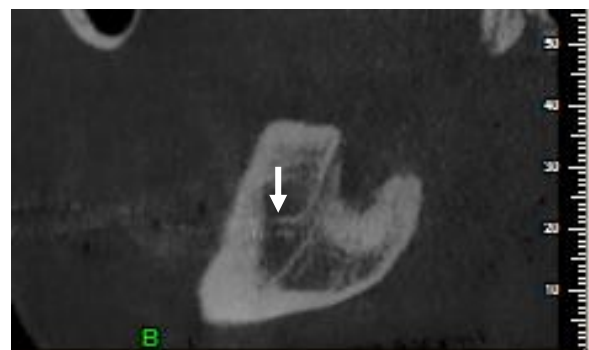


Figure 3: Oblique sagittal images of type 2 temporal crest canal

We first identified the TCC on oblique sagittal images. For every patient, we recorded the location of TCC (unilaterally or bilaterally). We also calculated their prevalence among men and women. Then statistical analysis was performed using SPSS (version16, SPSS Inc, Chicago, IL, USA).

Results

We studied 327 participants, comprised of 195(59.63%)

female and 132 (40.36%) male patients. Six TCC were observed in 684 sides. We observed all the TCC in females (Table 1).

Table 1: Distribution of temporal crest canal according to the gender

| Characteristics | Male | Female |
|-----------------|------|--------|
| TCC | 0 | 5 |

Assessment of CBCT images revealed this variation in five patients. From these cases, one case demonstrated bilateral TCC and the remaining four cases were unilateral TCC. Two unilateral TCC were on the left side and the other two were on the right side (Table 2). Considering the classification of TCC, four participants had presentation of type I, and one case was categorized as type II (Table 2).

Table 2: The characteristics of temporal crest canal

| Characteristics | Patients (n = 327) % |
|-----------------|----------------------|
| Absence | 322 (98.47) |
| Presence | 5 (1.52) |
| Unilaterally | 4 (1.22) |
| In left | 2 (0.61) |
| In right | 2 (0.61) |
| Bilaterally | 1 (0.30) |
| Type I | 4 (1.22) |
| Type II | 1(0.30) |

Discussion

Anatomical variants of mandibular canal can complicate surgical operation if not appropriately diagnosed. Nerve damage and hemorrhage that diminish the visibility of environment can occur because of surgical entrance. The information on bifid mandibular canal and retromolar canal is well-established; [12-15] however, adequate information is not available about temporal crest canal.

Based on Ossenberg classifications, [8] type III retromolar canal is corresponded to TCC, which suggests that this variation is hereditary; its prevalence in Northeast Asia was 1.3 %. [9, 11] In a CBCT study by Naitoh *et al.*, [8] they reported the presence of three TCC in two sides of two mandibles (0.068%). However, Kawai *et al.* [7] stated the relatively high incidence of 8.3% in CBCT of 48 cadavers.

The study conducted by Han *et al.*, [2] found lower prevalence (4 of 446 patients) (0.9%) of TCC. In our investigation, generality of TCC was 1.5%. We identified six TCC in five of 327 patients. Considering the location of variations, majority of our cases with TCC

had unilateral appearance. This finding is in line with the results of previous studies. [2, 10, 13]

Review of the literature indicates that TCC is more prevalent in male patients. In a study by Han *et al.*, male predominance [2] was reported. In contrast, in our study all TCC were found in female patients.

In our study, we categorized TCC in two types based on Kawai *et al.* study. [10] The first type was initiated at the mandibular foramen and the second type starts from accessory foramen near the mandibular foramen. However, Han *et al.* [2] only applied classification that considered TCC originated from accessory foramen. However, this difference in classifications can illustrate higher incidence rate of TCC in Kawai *et al.* study. [10]

Considering the content of TCC, Ossenberg stated that TCC is in line with the course of buccal nerve; thus, it is considered as a branch of long buccal nerve. [8] In agreement with this result, in Kawai's study on cadaver dissection and histopathological assessment, neurovascular structures were confirmed. [10]

The presence of TCC has clinical importance. It can provide an accessible rout for the spread of tumor and infection. [16-17] Furthermore, the presence of additional innervation may lead to failure in obtaining adequate anesthesia during dental and surgical operations. [18-19] Damage to TCC during sagittal split osteotomy, bone block harvesting and removal of the lesions involving the ramus, can lead to nerve injury, which is manifested as paresthesia, dysesthesia and traumatic neuroma. [7, 20-21]

Conclusion

Regarding the clinical significance of TCC and the ability of CBCT images in confirming the presence of TCC, this variation should be carefully investigated using reconstructed CBCT images.

Acknowledgments

This paper has been extracted from Dr. Shahrzad Al-sadat Shamszade's DDS thesis, which was conducted under supervision of Dr. Mahvash Hasani and advisory of Dr. Shoaleh Shahidi. The study was approved, registered with ID 8895157 and supported by the International Branch of Shiraz University of Medical Sciences.

Conflict of Interest

None to declare.

References

- [1] Kaufman E, Serman NJ, Wang PD. Bilateral mandibular accessory foramina and canals: a case report and review of the literature. *Dentomaxillofac Radiol.* 2000; 29: 170-175.
- [2] Choi YY, Han SS. Double mandibular foramen leading to the accessory canal on the mandibular ramus. *Surg Radiol Anat.* 2014; 36: 851-855.
- [3] Claeys V, Wackens G. Bi-fid mandibular canal: literature review and case report. *Dentomaxillofac Radiol.* 2005; 34: 55-58.
- [4] Ghaemina H, Meijer GJ, Soehardi A, Borstlap WA, Mulder J, Bergé SJ. Position of the impacted third molar in relation to the mandibular canal. Diagnostic accuracy of cone beam computed tomography compared with panoramic radiography. *Int J Oral Maxillofac Surg.* 2009; 38: 964-971.
- [5] Worthington P. Injury to the inferior alveolar nerve during implant placement: a formula for protection of the patient and clinician. *Int J Oral Maxillofac Implants.* 2004; 19: 731-734.
- [6] Mizbah K, Gerlach N, Maal TJ, Bergé SJ, Meijer GJ. The clinical relevance of bifid and trifid mandibular canals. *Oral Maxillofac Surg.* 2012; 16: 147-151.
- [7] Naitoh M, Nakahara K, Suenaga Y, Gotoh K, Kondo S, Ariji E. Variations of the bony canal in the mandibular ramus using cone-beam computed tomography. *Oral Radiol.* 2010; 26: 36-40.
- [8] Ossenberg NS. Retromolar foramen of the human mandible. *Am J Phys Anthropol.* 1987; 73: 119-128.
- [9] Kang JH, Lee KS, Oh MG, Choi HY, Lee SR, Oh SH, et al. The incidence and configuration of the bifid mandibular canal in Koreans by using cone-beam computed tomography. *Imaging Sci Dent.* 2014; 44: 53-60.
- [10] Kawai T, Asaumi R, Kumazawa Y, Sato I, Yosue T. Observation of the temporal crest canal in the mandibular ramus by cone beam computed tomography and macroscopic study. *Int J Comput Assist Radiol Surg.* 2014; 9: 295-299.
- [11] Orhan K, Aksoy S, Bilecenoglu B, Sakul BU, Paksoy CS. Evaluation of bifid mandibular canals with cone-beam computed tomography in a Turkish adult population: a retrospective study. *Surg Radiol Anat.* 2011; 33: 501-507.
- [12] Kuribayashi A, Watanabe H, Imaizumi A, Tantanapornkul W, Katakami K, Kurabayashi T. Bifid mandibular canals: cone beam computed tomography evaluation. *Dentomaxillofac Radiol.* 2010; 39: 235-239.
- [13] Han SS, Hwang YS. Cone beam CT findings of retromolar canals in a Korean population. *Surg Radiol Anat.* 2014; 36: 871-876.
- [14] von Arx T, Hänni A, Sendi P, Buser D, Bornstein MM. Radiographic study of the mandibular retromolar canal: an anatomic structure with clinical importance. *J Endod.* 2011; 37: 1630-1635.
- [15] Ossenberg NS. Temporal crest canal: case report and statistics on a rare mandibular variant. *Oral Surg Oral Med Oral Pathol.* 1986; 62: 10-12.
- [16] Fanibunda K, Matthews JN. Relationship between accessory foramina and tumour spread in the lateral mandibular surface. *J Anat.* 1999; 195(Pt 2): 185-90.
- [17] Das S, Suri RK. An anatomico-radiological study of an accessory mandibular foramen on the medialmandibular surface. *Folia Morphol (Warsz).* 2004; 63: 511-513.
- [18] Lew K, Townsen G. Failure to obtain adequate anaesthesia associated with a bifid mandibular canal: a case report. *Aust Dent J.* 2006; 51: 86-90.
- [19] DeSantis JL, Liebow C. Four common mandibular nerve anomalies that lead to local anesthesia failures. *J Am Dent Assoc.* 1996; 127: 1081-1086.
- [20] Muto T, Kanazawa M. Mandibular reconstruction using the anterior part of ascending ramus: report of two cases. *J Oral Maxillofac Surg.* 1997; 55: 1152-1156.
- [21] Silva FM, Cortez AL, Moreira RW, Mazzonetto R. Complications of intraoral donor site for bone grafting prior to implant placement. *Implant Dent.* 2006; 15: 420-426.