

## Original Article

## Evaluation of Infraorbital Canal in Cone Beam Computed Tomography of Maxillary Sinus

Abdolaziz Haghnegahdar<sup>1</sup>, Leila Khojastepour<sup>1</sup>, Atefe Naderi<sup>2</sup><sup>1</sup> Dept. of Oral and Maxillofacial Radiology, School of Dentistry, Shiraz University of Medical Sciences, Shiraz, Iran.<sup>2</sup> Postgraduate Student, Dept. of Oral and Maxillofacial Radiology, School of Dentistry, Shiraz University of Medical Sciences, Shiraz, Iran.

## KEY WORDS

Anatomy;  
Maxillofacial injuries;  
Maxillary Sinus;  
Cone-Beam Computed  
Tomography;Received April 2017;  
Received in Revised form June 2017;  
Accepted July 2017;

## ABSTRACT

**Statement of the Problem:** Ignoring anatomic variations may lead to iatrogenic injuries by surgeons.**Purpose:** The aim of this study was to examine the relationship between the course of infraorbital canal and maxillary sinus using cone beam computed tomography scans (CBCT).**Materials and Method:** One hundred and ninety two CBCT scans were reviewed for 384 infraorbital canals. The anatomic variants of infraorbital canals were classified into three types based on the protrusion degree of the infraorbital nerve from the maxillary roof into the sinus. Measurements were made on infraorbital canal as vertical distance from the infraorbital rim to the infraorbital foramen, the maximum horizontal distance from the infraorbital canal to the canine root, the maximum diagonal length of the nerve protruded in sinus, the maximum vertical distance from the center of the nerve to the sinus roof.**Results:** 26.5% of infraorbital canals were entirely contained within the sinus roof. 50.3% of infraorbital canals were located below the roof but remaining juxtaposed to it. In 23.2%, the nerve canal descended into the sinus. The prevalence of type3 of infraorbital canal significantly increased from 14.8% in cases without an ipsilateral Haller cell to 29.1% when a Haller cell was present. The average distance between the infraorbital foramen and the infraorbital rim were increased proportionally to the degree of protrusion of the nerve course into the maxillary sinus (ANOVA  $p < 0.001$ ).**Conclusion:** The infraorbital canal protrusion into the sinus is a common variation that must be considered during surgical procedures to avoid iatrogenic injury.**Corresponding Author:** Naderi A., Dental School, Shiraz University of Medical Sciences, Ghasroddast Street, Postal Code: 71976-15875. Tel: +98-7136263193-4 Fax: +98-7136270325  
Email: [atefe\\_naderi2007@yahoo.com](mailto:atefe_naderi2007@yahoo.com)Cite this article as: Haghnegahdar A., Khojastepour L., Naderi A. Evaluation of Infraorbital Canal in Cone Beam Computed Tomography of Maxillary Sinus. *J Dent Shiraz Univ Med Sci.* 2018 March; 19(1): 41-47.

## Introduction

The Infraorbital nerve (ION) is the terminal and largest branch of the maxillary nerve. When the maxillary nerve enters the orbit through the maxillary fissure, it is called the infraorbital nerve. On the orbital floor, ION passes through the infraorbital groove and infraorbital canal (IOC) then comes down over the anterior wall of the maxillary sinus to reach the face through the infraorbital foramen (IOF). The inferior orbital nerve pro-

vides the sensation for the skin of the lower eyelid, conjunctiva, upper lip and lateral surface of the nose. [1] According to Kazkayasi *et al.*, [2] investigating 10 cadavers, the IOC is unroofed along one fourth of its length in about 50% of cases. They also found that the superior roof of the IOC is a very thin bony layer in comparison with thick inferior wall at the roof of the maxillary sinus. However, it is not a fact in all cases as the ION can protrude into the maxillary sinus in several

instances. [2] Ference *et al.* [3] classified the ION course according to degree of its protrusion into the maxillary sinus in CT scans of 100 individuals. They reported that in 12.5% of cases the IOC was completely protruded into the maxillary sinus. This protrusion is more prevalent when a Haller cell exists in maxillary sinus. [3] Long term sensory disturbance of ION reported from 10% to 50% of patients who had correction of orbitozygomatic complex fracture. Meanwhile protrusion of IOC into maxillary sinus roof is considered as a significant risk upon fractures and different surgical procedures. [4-5] Iatrogenic injuries also could occur during different procedures such as Caldwell-Luc surgery, rhinoplasty, endoscopic sinus surgery, maxillary resections, removing tumors from maxilla and antrum. [6-8] Facial numbness has been reported in 2% to 9% of patients after Caldwell-Luc procedures. [6, 9] When the attachment of inverted papilloma is far lateral or anterior in the sinus, endoscopic resection must be completed with a Caldwell-Luc approach or antral trephination. [10-11]

In endoscopic maxillary sinus surgery, the possibility of injury to the ION is even more when the nerve is attached by a septum to the sinus roof. [12] Facial numbness has also been reported in 44% to 67% of patients following endoscopic surgeries in pterygopalatine fossa. [13-14]

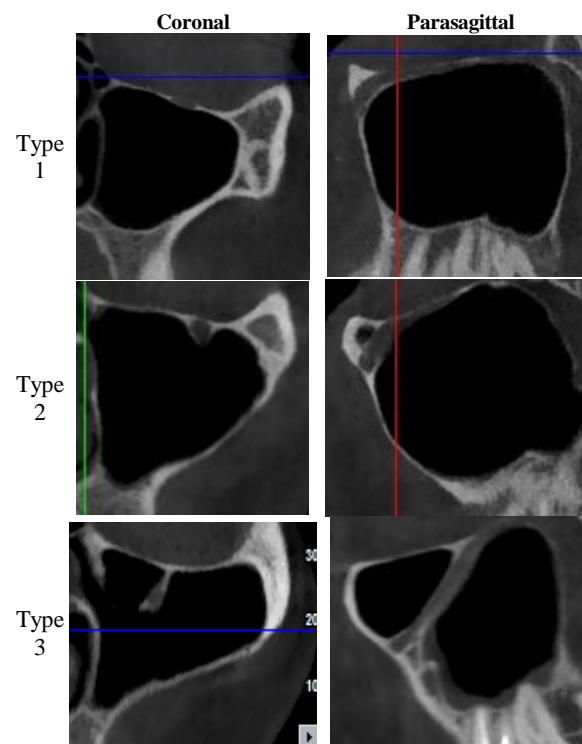
On the other hand, Haller cells' (infraorbital ethmoidal air cells) location in inferior rim of orbit is much closed to IOC and has a positive correlation with orbital floor dehiscence. [15] Choi [16] reported a case with complaints of unilateral medial facial hypoesthesia resulted from the influence of a mucocele in ipsilateral Haller cell on the infraorbital nerve dermatome.

Nowadays, cone beam computed tomography (CBCT) imaging is an accepted modality for radiographic evaluation of paranasal sinuses and related structures such as IOC and IOF because of low radiation dose, high bony resolution and easy image processing. [17-18] Few previous articles have investigated this nerve course by computed tomography. [3] To the best of our knowledge, none of the articles has used CBCT for investigating anatomic variations of IOC course and its relation with canine and Haller cells. This study is designed to evaluate the relation of the IOC course with the maxillary sinus and its different anatomic variations

in order to aid surgeons in preventing unintentional injury to a protruded ION.

### Materials and Method

This study was performed on 192 CBCT scans of paranasal sinuses (384 sinuses) of patients who referred to a private clinic of oral and maxillofacial radiology in Shiraz, Iran from 2012 to 2014. All CBCT scans included in this study contained maxillary sinus images and were prepared for other purposes. The exclusion criteria were evidence of previous trauma or manipulation of the maxillary sinuses, pathologic changes in maxillary sinuses, edentulous patients and patients with impacted or missing canine. All CBCT images were obtained with NewTom VGI (Quantitative Radiology, Verona, Italy, pixel size: 0.180mm) machine operated at 80 kV and 4 mA, 0.3mm voxel size and 12×8 field of view. Both slice thickness and slice intervals were 1mm. An oral and maxillofacial radiologist and a senior resident of oral and maxillofacial radiology examined the images by agreement using default NNT viewer.



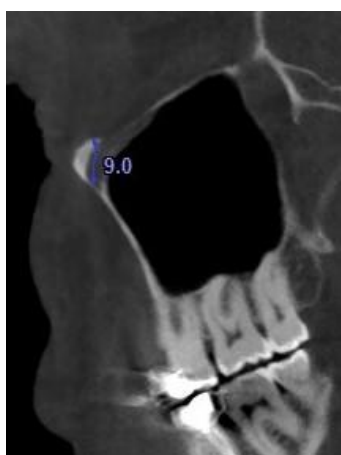
**Figure 1:** Coronal and parasagittal examples of anatomic variants based on the descendance of the infraorbital canal from the maxillary sinus roof

The axial, coronal and parasagittal plane were used to evaluate 386 IOCs on CBCT images. According to Ference *et al.* [3] anatomic variants of IOC were clas-

sified into three types based on the protrusion degree of the nerve from the maxillary roof into the sinus in axial and parasagittal plane. (Figure 1)

Type 1 in which nerve canal entirely contained within the sinus roof, type 2 in which nerve canal located below the roof but remaining juxtaposed to it, and type 3 in which nerve descending into the sinus lumen, suspended from the sinus roof within a septa or the lamella of an infraorbital ethmoid cell.

In parasagittal plane, the maximum vertical distance from the infraorbital rim to the IOF center in all types of infraorbital course variations was measured. (Figure 2)



**Figure 2:** The maximum vertical distance from infraorbital canal to the infraorbital rim in parasagittal plane

In coronal plane, a vertical line was drawn from the apex to the crown of the canine; the maximum horizontal distance from the center of IOC to this line was measured in axial plane. This measurement was done for all types. (Figure 3)

Two separate measurements were done in just type 3. First, the maximum diagonal length of the nerve canal protruded in sinus from the orbital floor to the center of IOF in parasagittal plane, second the maxi-

imum vertical distance from the center of the nerve canal to the sinus roof. (Figure 4)

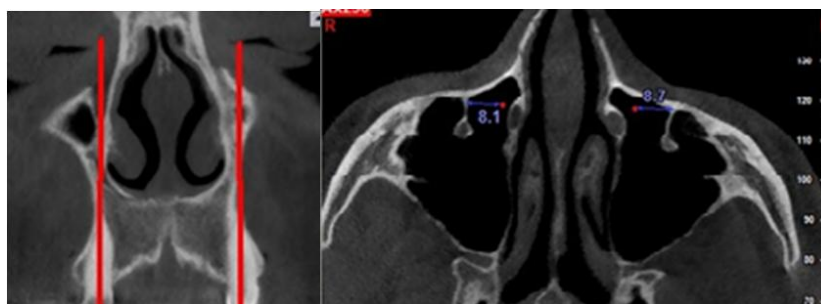
In axial planes, we noted which wall of the maxillary sinus the septum arose from (anterior, medial or posterior). The prevalence of accessory IOF was also recorded. The presence of the Haller cell and its relation with the nerve course was also searched in coronal planes. Data were collected according to gender, age and side.

All analysis was done by statically package for social sciences version 17 (SPSS Inc. Chicago, IL). Qualitative and quantitative variables were described by frequency (percent) and mean & standard deviation (SD), respectively. Comparisons of qualitative and quantitative variables between the types were done by Chi-Square test and analysis of variances (ANOVA) with Tukey post hoc test, respectively. A  $p < 0.05$  was considered significant.

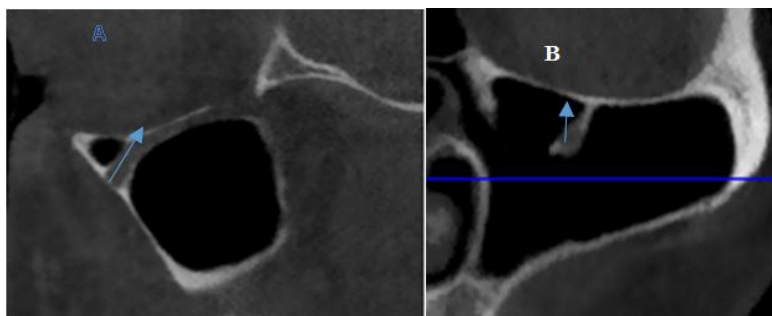
**Results**

Three hundred and eighty four IOCs of 192 CBCT studies of patients with the mean age of  $32.32 \pm 10.50$  were evaluated (age range: 14-62). The study sample consisted of 98(51%) males with the mean age of  $32.00 \pm 10.54$  and 94(49%) females with the mean age of  $32.67 \pm 10.51$ .

Table 1 shows the distribution of cases according to side, gender, presence of Haller cell, presence of nerve within the Haller cell and accessory foramen. The prevalence of Haller cells and nerve within the Haller cells were significantly higher in type 2 and 3 than type 1 ( $p < 0.01$ ). The prevalence of nerves totally protruded (type3) into the sinus significantly increased from 14.8% in cases without an ipsilateral Haller cell to 29.1% when a Haller cell was present ( $x=20.40$ ,  $p < 0.0001$ ) and to 43.9% when the nerve contained within a lamella of such a cell ( $x=19.66$ ,  $p < 0.0001$ ). The gender had co-



**Figure 3:** The distance between infraorbital canal and midroot of canine



**Figure 4a:** The diagonal length of the nerve, **b:** the vertical distance from the center of the infraorbital canal to the sinus roof

relations with different types ( $p < 0.001$ ). The prevalence of type 1 was higher in females while the prevalence of type 2 was higher in males.

The average distance of the foramen from the infraorbital rim were increased proportionally to the degree of protrusion of the nerve course into the maxillary sinus (ANOVA  $p < 0.001$ ). Table 2 shows the measurements in mm. The mean distance of IOF to infraorbital rim in type3 (descended type) was significantly higher than type 1 and type 2 (non-descended type). All the septa of type3 IOCs arose from the anterior wall of the maxillary sinus.

**Discussion**

This study showed that the incidence of protrusion of IOC into the maxillary sinus is a common variation and can be seen in 23.2% of studied population. This prevalence was found to be greater than the reports of the previous studies reported by Ference *et al.*, [3] to be 12.5%, by Yenigum *et al.* [19] to be 12.3% and finally by Lantos *et al.* [20] to be 10.8%. This may be contributed to the anatomic variations of different populations, patients' age group, race and resolution of the evaluated images. The high percentage of type3 in our analysis may represent the greater sensitivity of CBCT scan in the detection of small bony structures compared with CT scans. Ference *et al.* [3] investigated anatomic variation of IOC in 100 patients by CT scans. They reported

that the prevalence of type3 ION is not a rare finding (12.3%) and type 1 is the most common type among their patients (60.5%). They also found that protrusion of the IOC into the maxillary sinus increased from 7.8% in cases without an ipsilateral Haller cell to 27.7% when a Haller cell was present and to 50% when the nerve was within the lamella of the Haller cell, compatible with our study results. [3] Prevalence of infraorbital ethmoid air cell is reported from 2.7% to 65% in different studies. [15-16] It is divided into three classes of small, medium and large, according to their size. [16] The medium and large Haller cells can be regarded as an etiologic factor for maxillary sinusitis. Haller cell is also accompanied with orbital floor dehiscence and the orbit may be involved during Haller cell diseases or surgical instrumentation of ostiomeatal complex. [15, 21] In our sample, the most common type of IOC anatomic variations was type 2(50.3%) which is compatible with Yenigum *et al.* [19] in Turkey (51.2%). They classified IOC types according to Lee *et al.* [22] approach. They found no correlation between IOC type and presence of Haller cells, but they reported that the rate of the IOC totally protruded into the maxillary sinus increased from 9.8% in cases without maxillary sinus septa to 25% when maxillary sinus septa are present. [19] Gandhi *et al.* [23] found that septa were more common in edentulous specimens and the presence of septa increases by tooth loss and atrophy of the maxillary alveolar b-

**Table 1:** The prevalence of different types according to gender, side and presence of Haller cells, nerve within the Haller cell and accessory foramen and measurements of IOC course in maxillary sinus

Canal type		Male	Female	Right side	Left side	Haller cell	Nerve within Haller Cell	Accessory Foramen	Mean distance from IOF to orbital rim	Mean distance from IOF to Canine root
Type 1	26.5%(102)	18.4%(36)	35.1%(66)	29.7%(57)	23.4%(45)	14.5%(16)	2.4%(1)	27.9%(19)	7.41±1.33	12.15±2.36
Type 2	50.3%(193)	58.7%(115)	41.5%(78)	46.6%(89)	54.2%(104)	56.4%(62)	53.7%(22)	51.5%(35)	8.19±1.37	12.35±2.30
Type 3	23.2%(89)	23%(45)	23.4%(44)	24.0%(46)	22.4%(43)	29.1%(32)	43.9%(18)	20.6%(14)	9.39±1.44	12.92±2.36
P-value	0.262	<0.01		0.262		<0.01	<0.01	0.895	<0.001	0.64

**Table 2:** Mean± SD (All the measurements in mm) describes quantitative variables

	HD-TO-3*				VDP**				DL***	VDC****
	Type 1	Type 2	Type 3	ANOVA p Value	Type 1	Type 2	Type 3	ANOVA p Value	Type 3	Type 3
Right	12.35±2.22	12.78±2.22	13.60±2.31	0.021	7.51±1.27	8.11±1.42	9.30±1.37	0.001	11.67±2.81	5.80±1.62
Left	11.75±2.49	11.98±2.20	12.39±2.42	0.379	7.78±1.47	8.24±1.47	9.12±1.58	0.001	11.55±2.27	6.29±1.76
Total		12.43±2.34		0.064		8.26±1.54		0.001	11.61±2.55	6.37±2.70

\* The maximum horizontal distance from the center of IOC to canine midroot measured in axial plane. \*\* In parasagittal plane the maximum vertical distance from the infraorbital rim to the IOF. \*\*\*the maximum diagonal length of the nerve protruded in sinus from the orbital floor to the center of IOF in parasagittal plane. \*\*\*\*the maximum vertical distance from the center of the nerve to the sinus roof

one. They stated that there are two types of septa: primary and secondary. Primary septa develop during mid-face growth, which might be detected in all parts of the sinuses. Secondary septa develop during maxillary alveolar bone atrophy and tooth loss. [23]

During routine endoscopic uncinectomy sinus surgery with maxillary antrostomy, a protruded nerve will not be at increased risk of injury. However, any surgical attempt to clear disease from the roof of the maxillary sinus, or to break down septa or the lamellae of a Haller cell, may cause ION injury. [12, 24] For example, approximately 40% of inverted papillomas occur in the maxillary sinus, and during resection the mucosal lining of the sinus must be stripped and the wall addressed with a burr or cautery; placing a protruded ION at a great risk. [10-11] When the attachment of the papilloma is far lateral or anterior in the maxillary sinus, a targeted external Caldwell-Luc approach or antral trephination supplement the endoscopic resection. [10-11]

Yenigum *et al.* [19] investigated a wide range of age (18-84). They have not explained that this correlation between septa and IOC type was in dentate or edentulous patients.

The results of present study confirmed the correlation between IOC type and gender. This correlation was not found in any previous studies, which may be explainable by anatomic variations in different populations. We found that type 1 is more common in females and type 2 in males. The clinical importance of this finding is not established. According to Lantos *et al.* [20] when the septa of type 3 IOC is short, it does not make clinical importance. They investigated 500 CT scans for prevalence of type 3 IOC and classified it to three types according to its length. The prevalence of protruded IOC was reported 10.8%. ION is more susceptible to be injured when it is protruded for a longer distance. [20] The importance of protruding IOC into

the maxillary sinus is not fully understood. Some of the following possibilities might be true. First, this variant impairs normal drainage pathway. Second, the endoscopic access to distal areas is hindered. Third, a potential predisposing factor for occult disease is present, and finally fourth; the risk of surgical errors increases. [25]

Lantos *et al.* [20] also investigated that from which wall of the maxillary sinus the septum arises. In all subjects, the septa of type3 IOC was attached to the anterior wall except one patient had attachment to the posterior wall. It is compatible with the present study which the whole type3 IOCs attached to the anterior wall of the maxillary sinus. Attachment to the medial wall is theoretically at greater risk during maxillary antrostomy. [20]

In descended nerves (type 3), the distance of the infraorbital foramen to the infraorbital rim was 1.98mm greater than non-descended types. Ference *et al.* [3] found this difference to be 2.9mm. In the present study, the mean distance of the infraorbital foramen to the orbital rim, the diagonal length of the nerve protruded in maxillary sinus, and distance from the nerve canal to sinus roof in type 3 were shorter than Ference *et al.*'s study. [3] It was 9.39± 1.44, 6.37±2.70, 11.61±2.52mm, respectively in our study compared to 11.87±2.46, 8.58±2.85, 15.40±3.60mm in their study. The distance of the IOF to the orbital rim is reported from 4 to 12mm in literature. [26] Berry [27] reported that there were variations regarding different populations and genus. Aziz *et al.* [28] studied forty-seven cadaveric heads and measured the distance of the infraorbital foramen to the orbital rim and to the facial midline and supraorbital foramen. They found that the IOF varies according to location, size, shape, laterality and incidence of accessory foramen. [28]

The most obvious significance of the distance from the IOF to the orbital rim is in Caldwell-Luc surgery

and local anesthesia procedures. During the Caldwell-Luc procedure, the facial flap is elevated at the IOF and facial numbness has been reported in 2% to 9% of patients following this surgery. [9, 29] Endoscopic approach has been substituted Caldwell-Luc surgery but Caldwell-Luc is sometimes being applied for resection of neoplasms, ligation of internal maxillary artery and orbital floor repair. [12]

The length of the nerve exposed into the maxillary sinus and the distance of the IOC to the sinus roof must be considered during endoscopic sinus surgery. For instance, during an expanded endoscopic approach, if access to the infratemporal fossa is necessary the back wall of the maxillary sinus must be removed and the infraorbital nerve will be at risk. [30-31] Facial numbness has been reported in 44% to 67% of patients after endoscopic pterygopalatine fossa surgery. [13-14]

The present study showed correlation between totally- protruded nerve and increased distance between IOF and the infraorbital rim, which increase the risk of the injury to ION during Caldwell-Luc approach. This outcome was in accordance with Ference *et al.*'s [3] result. The horizontal distance from IOF to the canine root did not make difference in different types of IOC, which was compatible with Ference *et al.*, study [3] i.e.,  $11.99 \pm 2.54$  mm versus  $12.43 \pm 2.34$  mm. Therefore, the distance from canine can be used as a supplemental landmark for locating IOC during surgeries since it is nearly constant in all types of ION canals.

There are some studies about the morphological structure of the IOC on cadaveric skulls using CT data. [2, 25] Radiologists must mention any anatomical variations in the sinonasal regions before any surgery to prevent any complications. There were few studies [3] looking at the influence of the course of the nerve on distance from IOF to the orbital rim or canine on CT. This is the first study to use CBCT sinus scans to measure the length of the protruded nerve below the infraorbital rim, among patients with anatomic variations in the course of the infraorbital nerve.

### Conclusion

Protrusion of IOC into the maxillary sinus is not rare and it must be considered during different surgical procedures. This variation increases when there is a Haller cell. The distance from IOF to the orbital rim increases,

when the nerve is protruded into the maxillary sinus. Preoperative examination, by a low dose technique, avoids iatrogenic injuries and surgical complications.

### Acknowledgements

The authors would like to thank the Vice Chancellor of Shiraz University of Medical Sciences for supporting this research. This article is based on a postgraduate thesis of Dr. Naderi, under the supervision of Dr. Haghnegahdar.

### Conflict of Interest

The authors of this manuscript certify that they have no conflict of interest regarding this research.

### References

- [1] Leo JT, Cassell MD, Bergman RA. Variation in human infraorbital nerve, canal and foramen. *Ann Anat.* 1995; 177: 93-95.
- [2] Kazkayasi M, Ergin A, Ersoy M, Tekdemir I, Elhan A. Microscopic anatomy of the infraorbital canal, nerve, and foramen. *Otolaryngol Head Neck Surg.* 2003; 129: 692-697.
- [3] Ference EH, Smith SS, Conley D, Chandra RK. Surgical anatomy and variations of the infraorbital nerve. *Laryngoscope.* 2015; 125: 1296-1300.
- [4] Jungell P, Lindqvist C. Paraesthesia of the infraorbital nerve following fracture of the zygomatic complex. *Int J Oral Maxillofac Surg.* 1987; 16: 363-367.
- [5] Vriens JP, Moos KF. Morbidity of the infraorbital nerve following orbitozygomatic complex fractures. *J Cranio-maxillofac Surg.* 1995; 23: 363-368.
- [6] Brandão FH, Machado MRCS, Aquino JEP, Coelho Júnior RG, Pereira SHP, Fabi RP. The Foramen and infraorbital nerve relating to the surgery for external access to the maxillary sinus. *Arq Int Otorrinolaringol.* 2008; 12: 342-346.
- [7] Meyer M, Moss AL, Cullen KW. Infraorbital nerve palsy after rhinoplasty. *J Craniomaxillofac Surg.* 1990; 18: 173-174.
- [8] Ohki M, Takeuchi N. Objective evaluation of infraorbital nerve involvement in maxillary lesions by means of the blink reflex. *Arch Otolaryngol Head Neck Surg.* 2002; 128: 952-955.
- [9] Stefánsson P, Andréasson L, Jannert M. Caldwell-Luc operation: long-term results and sequelae. *Acta Otolar-*

- ngol Suppl. 1988; 449: 97-100.
- [10] Busquets JM, Hwang PH. Endoscopic resection of sinonasal inverted papilloma: a meta-analysis. *Otolaryngol Head Neck Surg.* 2006; 134: 476-482.
- [11] Kamel R, Khaled A, Kandil T. Inverted papilloma: new classification and guidelines for endoscopic surgery. *Am J Rhinol.* 2005; 19: 358-364.
- [12] Chandra RK, Kennedy DW. Surgical implications of an unusual anomaly of the infraorbital nerve. *Ear Nose Throat J.* 2004; 83: 766-767.
- [13] Har-El G. Combined endoscopic transmaxillary-transnasal approach to the pterygoid region, lateral sphenoid sinus, and retrobulbar orbit. *Ann Otol Rhinol Laryngol.* 2005; 114: 439-442.
- [14] DelGaudio JM. Endoscopic transnasal approach to the pterygopalatine fossa. *Arch Otolaryngol Head Neck Surg.* 2003; 129: 441-446.
- [15] Mathew R, Omami G, Hand A, Fellows D, Lurie A. Cone beam CT analysis of Haller cells: prevalence and clinical significance. *Dentomaxillofac Radiol.* 2013; 42: 20130055.
- [16] Choi JH. Hypoesthesia of midface by isolated Haller's cell. *Mucocele Braz J Otorhinolaryngol.* 2016. Available at: <http://dx.doi.org/10.1016/j.bjorl.2016.06.009>
- [17] Zaizen T, Sato I. A morphological study of the multi infraorbital canals of the maxilla in the Japanese macaque by cone-beam computed tomography. *Anat Sci Int.* 2014; 89: 171-182.
- [18] Shahidi S, Zamiri B, Momeni Danaei S, Salehi S, Hamedani S. Evaluation of Anatomic Variations in Maxillary Sinus with the Aid of Cone Beam Computed Tomography (CBCT) in a Population in South of Iran. *J Dent (Shiraz).* 2016; 17: 7-15.
- [19] Yenigun A, Gun C, Uysal II, Nayman A. Radiological classification of the infraorbital canal and correlation with variants of neighboring structures. *Eur Arch Otorhinolaryngol.* 2016; 273: 139-144.
- [20] Lantos JE, Pearlman AN, Gupta A, Chazen JL, Zimmerman RD, Shatzkes DR, et al. Protrusion of the Infraorbital Nerve into the Maxillary Sinus on CT: Prevalence, Proposed Grading Method, and Suggested Clinical Implications. *AJNR Am J Neuroradiol.* 2016; 37: 349-353.
- [21] Khojastepour L, Mirhadi S, Mesbahi SA. Anatomical Variations of Ostiomeatal Complex in CBCT of Patients Seeking Rhinoplasty. *J Dent (Shiraz).* 2015; 16: 42-48.
- [22] Lee JC, Kao CH, Hsu CH, Lin YS. Endoscopic transsphenoidal vidian neurectomy. *Eur Arch Otorhinolaryngol.* 2011; 268: 851-856.
- [23] Gandhi KR, Wabale RN, Siddiqui AU, Farooqui MS. The incidence and morphology of maxillary sinus septa in dentate and edentulous maxillae: a cadaveric study with a brief review of the literature. *J Korean Assoc Oral Maxillofac Surg.* 2015; 41: 30-36.
- [24] Maillieux P, Desgain O, Ingabire MI. Ectopic infraorbital nerve in a maxillary sinus septum: another potentially dangerous variant for sinus surgery. *JBR-BTR.* 2010; 93: 308-309.
- [25] Earwaker J. Anatomic variants in sinonasal CT. *Radiographics.* 1993; 13: 381-415.
- [26] Satwik A, Kumar S. Anatomical Variations of Supraorbital, Infraorbital and Mental Foramen based on Gender and Side- A Review. *J Pharm Sci & Res.* 2014; 6: 60-62.
- [27] Berry AC. Factors affecting the incidence of non-metric skeletal variants. *J Anat.* 1975; 120(Pt 3): 519-535.
- [28] Aziz SR, Marchena JM, Puran A. Anatomic characteristics of the infraorbital foramen: a cadaver study. *J Oral Maxillofac Surg.* 2000; 58: 992-996.
- [29] DeFreitas J, Lucente FE. The Caldwell-Luc procedure: institutional review of 670 cases: 1975-1985. *Laryngoscope.* 1988; 98: 1297-1300.
- [30] Al-Mujaini A, Wali U, Alkhabori M. Functional endoscopic sinus surgery: indications and complications in the ophthalmic field. *Oman Med J.* 2009; 24: 70-80.
- [31] May M, Levine HL, Mester SJ, Schaitkin B. Complications of endoscopic sinus surgery: analysis of 2108 patients--incidence and prevention. *Laryngoscope.* 1994; 104: 1080-1083.