

Case Report**Gummy Smile Correction Using Botulinum Toxin With Respective Gingival Surgery**Irineu Gregnanin Pedron¹, Alessandro Mangano²¹ Dept. of Stomatology, College of Dentistry, University of São Paulo, Brazil.² Private Practice in Gravedona ed Uniti, Como, Italy.**KEY WORDS**Gingival overgrowth;
Botulinum toxins type A;
Gummy smile;
Gingivectomy;
Dental esthetics;Received February 2017;
Received in Revised form March 2017;
Accepted July 2018;**ABSTRACT**

The pursuit of esthetic excellence has become a major goal in the dental treatment and orthodontic treatment. The beauty of the smile is not only constituted by the shape, position, and size of the teeth, but also based on the characteristics of the gingival tissue and conformation of the lips, which should be as harmonious as teeth. Gummy smile is one of the complaints of the patients, since such a situation can influence self-esteem and social relationships. The development of new more conservative techniques may provide a better therapeutic option than surgical procedures, such as the application of botulinum toxin, in the treatment of gummy smile. The purpose of this article is to present the case of a patient who presented denotogingival discrepancy and gummy smile, treated by resective gingival surgery and by application of botulinum toxin, optimizing smile harmony, and achieving improved self-esteem and quality of life. The application of botulinum toxin is an alternative less invasive, faster, safer, and more effective. Moreover, it produces harmonics and pleasing results when applied in target muscles, respecting the appropriate dose and type of smile. Therefore, the technique is a useful adjunct in the esthetic improvement of the smile and provides better results when combined with resective gingival surgery.

Corresponding Author: Irineu Gregnanin Pedron. Rua Flores do Piauí, 508- São Paulo- Brazil.
Zip Code: 08210-200 Tel: +55-11-2944-4067 Email: igpedron@alumni.usp.brCite this article as: Pedron IG., Mangano A. Gummy Smile Correction Using Botulinum Toxin With Respective Gingival Surgery. *J Dent Shiraz Univ Med Sci.*, 2018 September; 19(3): 248-252.**Introduction**

Currently, the demand for cosmetic procedures has grown exponentially. Dental procedures, as well as medical ones, besides working to obtain the principle of health promotion, seek smile esthetics, as the smile is a form of communication and socialization that expresses many feelings. [1-2]

Facial esthetic harmony correlates directly with the smile and this, in turn, is formed by the union of three components: teeth, gum, and lips. [1-3] The smile becomes esthetically pleasing when these elements are disposed in suitable proportion, and exposure of the gingival tissue is limited to 3 mm. When the gingival exposure is greater than 3 mm, it is characterized the non-esthetic condition called gummy smile, which affects some patients psychologically. [1, 4-7]

Several therapeutic modalities have been proposed for the correction of gummy smile including gingivectomy or gingivoplasty, [1, 2, 4-5, 7] myectomy, [5, 7] and orthognathic surgery. [5, 7-8] While the last two procedures are more invasive and associated with high morbidity, [6] in contrast, the use of botulinum toxin resulted to be more conservative, more effective, faster, and safer, as compared to surgical procedures. [4, 9] Thus, the application of botulinum toxin can be considered as a therapeutic option to a surgical approach. [4, 6]

Botulinum toxin is synthesized by gram-positive anaerobic bacterium *Clostridium botulinum*. [5, 7-8] It inhibits the release of acetylcholine at the neuromuscular junction, which prevents muscle contraction. There are seven distinct serotypes of toxins (A, B, C1, D, E, F and G). However, the subtype A is the most frequently

used clinically and the most powerful. [5] Currently, botulinum toxin has been shown effective in the treatment of gummy smile in patients with hyperfunction of the muscles involved in smiling, as well as in patients with other disorders such as temporomandibular disorders (hypertrophy of the masseter muscle, bruxism, clenching) and myofascial pain. [5, 8] The purpose of this paper was to report a case of a patient who presented gummy smile and was treated by associating resective gingival surgery (gingivectomy) and application of botulinum toxin.

Case Report

An 18-years-old Caucasian female referred to the practice with complaint of excessive gum display while smiling (Figures 1 and 2).

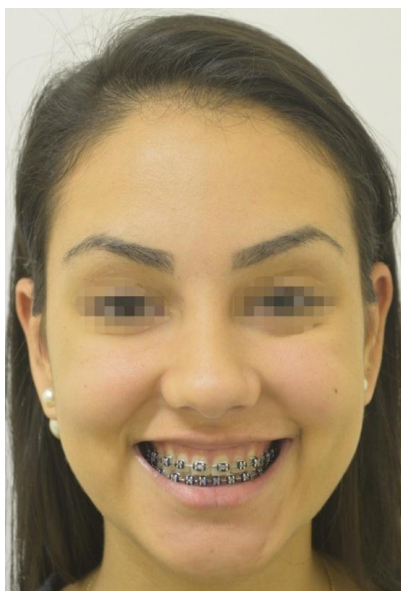


Figure 1: Exposure of evident gum, featuring the gummy smile

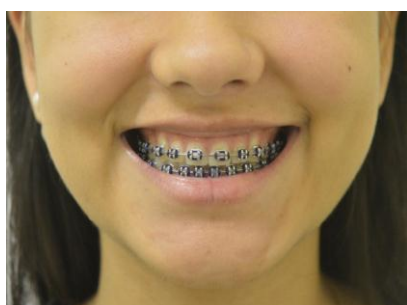

Figure 2: Gummy smile: closer view

The patient presented a good general health and absence of active periodontal disease. Clinically, the patient had short clinical crowns and a gummy smile sh-

owing gingival exposure greater than 3mm (Figure 3).

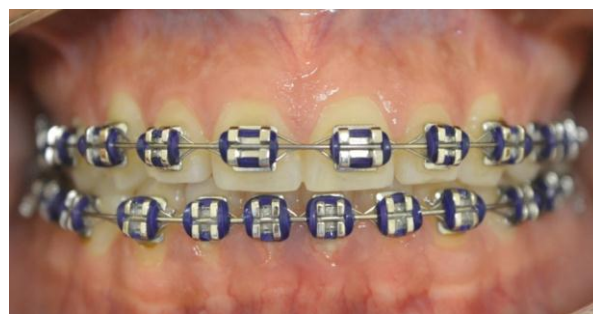

Figure 3: Initial clinical appearance showing an anatomical discrepancy between the lengths of teeth

No periapical radiolucency at radiographic examination was detected, the periodontal ligament was within normal limit, and the crown-to-root ratio was about 1:3. At clinical examination, attached gingiva band was 6 to 7mm in width, and periodontal pocket depth was 3mm or less.

The primary treatment plan proposed was a combined orthodontic-surgical approach by mean of LeFort I osteotomy in order to affect the maxilla and reduce the gingival exposure. The patient refused the surgical approach. A second treatment plan was developed and proposed consisting of a preliminary gingival surgery (gingivectomy) followed by injection of botulinum toxin type A. The patient was informed about the recurrence of gummy smile after 6 months of application because of temporary results of the botulinum toxin. The patient read and signed a written consent form prior to treatment. Under local infiltrative anesthesia, bleeding points were determined with the aid of a millimetered- probe and the union of these points were performed with the electrocautery. [2] The length of the teeth was increased, characterizing the dental zenith. Subsequently, the scraping was performed, resembling the technique of external bevel, in order to enhance issue healing (Figures 4 and 5).

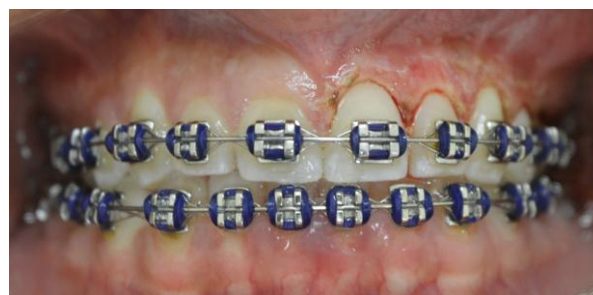

Figure 4: Post-surgical: upper left side

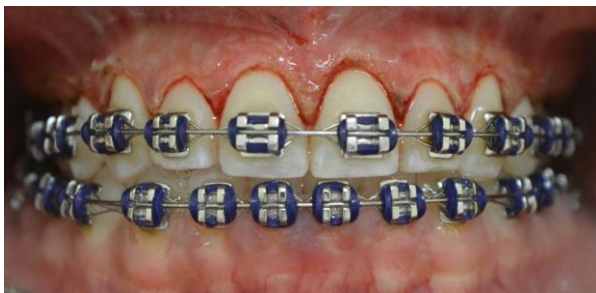

Figure 5: Post-surgical: upper right side

There was no need of the use of surgical cement, given that the process of the wound occurs by secondary intention. The patient reported no complaints or complications after surgery.

After 30 days, at the subsequent consultation, satisfactory tissue repair was observed (Figure 6), and no changes or complaints were reported by the patient. However, the persistence of complaint of gummy smile was reported by the patient (Figures 7 and 8).

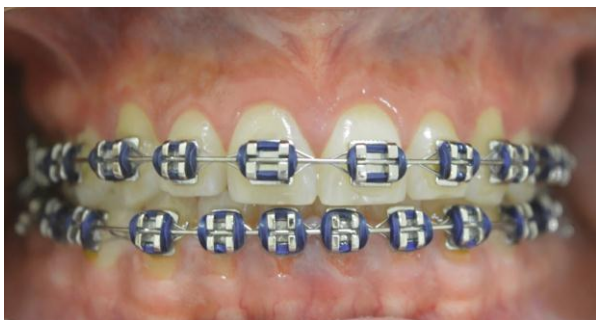

Figure 6: Post-surgical (30 days): observed satisfactory tissue repair

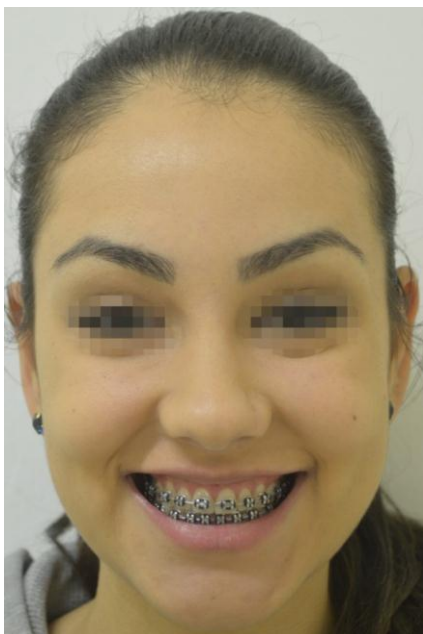

Figure 7: Post-surgical (30 days): persistence of gummy smile complaint.

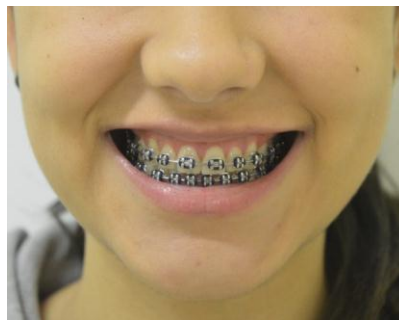


Figure 8: Persistence of gummy smile complaint: closer view

In the same consultation, botulinum toxin was applied. Prior to application of botulinum toxin, the surface of the skin was disinfected with ethyl alcohol 70% and the oils from the area were removed, in order to avoid local infection. The points of application were marked, beside each nostril. Then, local anesthetic (Emla™, Astra, São Paulo, Brazil) was applied with the aim of promoting comfort during the procedure. Botulinum toxin type A (Dysport™, Ipsen Biopharm Ltd, Wrexham, UK) was diluted in 1.7ml of saline according to the manufacturer's instructions, and two units was injected in the recommended site, laterally to each nostril. After application, the patient was advised not to bow their head during the first four hours and not engage in physical activity during the first 24 hours after the procedure.

After 10 days, the patient was examined. She presented a uniform dehiscence of the upper lip and reduction and attenuation of gummy smile (Figures 9 and 10). Side effects or complaints were not reported.

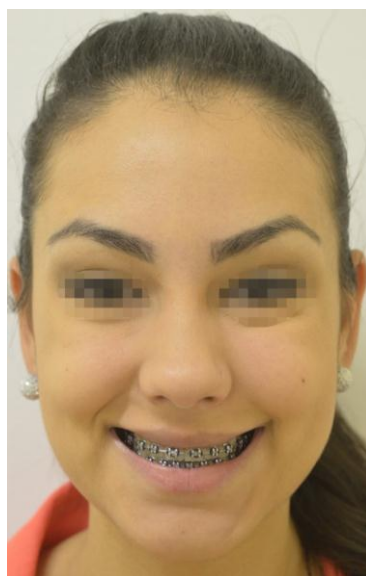

Figure 9: Aesthetic results after 10 days of application of botulinum toxin.

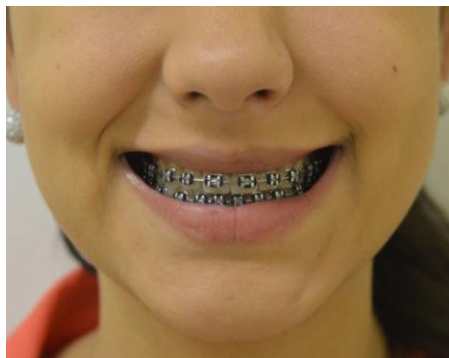

Figure 10: Aesthetic results: closer view

Discussion

The gummy smile is conceptualized by the exposure of more than 3 mm of gingival tissue during smiling, [1, 4, 6] and it is often found in women. [9] The predominance of females can be explained by the fact that male patients present lower smile line. [3-4]

Several etiologies have been suggested to gummy smile, as vertical maxillary excess, [3-5, 7-8] delayed passive eruption, [3, 5-6, 8] hyperfunction of the muscles involved in smiling [5-6, 8] and reduced length of the clinical crown of the teeth, [1-2, 6] which can occur separately or together, and determine the type of treatment to be used.

In gummy smile caused by overactive muscle, botulinum toxin was indicated. It is the treatment of first choice for the ease and security of applications, fast effect, besides being a more conservative approach when compared to surgical procedures (myectomy or Le Fort I osteotomy). [3-10]

The activity of the smile is determined by several facial muscles, like the elevator of the upper lip and wing of the nose, the zygomatic major and minor, the angle of the mouth, orbicularis oris, and risorius. [3-5, 7-9] Among them, the first three ones play higher function and determine the amount of lip elevation and, therefore, should be the muscles affected by the injection of the toxin. The fibers of these muscles converge to the same area, and they form a triangle, what suggests that the point of adequate election comprehend the three muscles in a single injection. The toxin, when injected, can spread in an area of 10 to 30 mm, what allows the effective extent. [3-4] The site indicated for the application of botulinum toxin was laterally to the wing of the nose. [3, 7-9] After application, the reduction of contraction of the muscles responsible for upper lip lift is expected, subsequently reducing the gingival exposure.

[3-10]

The elevation of the upper lip is determined by a group of muscles that have specific functions during the activity of the smile. The gummy smile can be classified in anterior, posterior, mixed and asymmetrical, involving different muscle groups. [3, 9] The anterior gummy smile is treated with the conventional technique, by the application laterally to the wing of the nose. In the posterior gummy smile, the applications should be made at the conventional point with half of the dose and the second point 2 cm laterally to the first, at the level of the tragus line. In the mixed gummy smile, the application should be performed by associating the previous two. However, the dose should be reduced to 50% in the lateral to the wing of the nose point. [4] In cases of labial asymmetry, that occurs due to differences in muscle activity, [3] the patients receive injections of different doses on either side of the face. [4, 9]

Botulinum toxin type A is a hydrophilic powder, stored under vacuum, sterile and stable. [5, 7] The reconstitution occurs from the smooth injection of the diluent (sodium chloride 0.9%) inside the bottle. The solution should be stored at 2 to 8°C and used within 4 to 8 hours, in order to ensure its effectiveness. [8]

At the beginning of the treatment, extraoral photographs, including the close-up of the smile, were performed. Some authors mentioned the importance of taking the picture of the smile before and after the application of the toxin. [5, 9-10] It has been suggested that the picture of the smile should be performed stimulating individually the muscles with electrical current, in order to ensure that muscle contraction be controlled, precise and repeatable, as the spontaneous smile is extremely difficult to be replicated. Patients understand that the treatment is carried out to produce a different smile, and, from this perspective, unconsciously, there is a tendency to smile differently in photographs after the treatment. [10]

The clinical effects show up in 2-10 days after the injection, and the most visible effect occurs 14 days after the injection. [3, 5] This first effect, scheduled to be progressive, is also reversible, lasting about 3 to 6 months. [4-5, 8]

The injection of botulinum toxin, despite being a simple and safe procedure, may be associated with some adverse events such as pain at the injection site, bruising

ing, infection, edema, dysphonia, dysphagia, ptosis, or lengthening of the upper lip and asymmetry of the smile. The dentist should be attentive in relation to dosage, precision of technique and location of the puncture. [4-5, 8, 10] In this report, claims or changes arising from the application were not reported.

Contraindications to the use of botulinum toxin are pregnancy; lactation; hypersensitivity (allergy) to botulinum toxin itself; lactose and albumin; muscle and neurodegenerative diseases (myasthenia gravis and Charcot's disease), and concurrent use of aminoglycoside antibiotic that enhances the action of the toxin. [8]

In this report, the result was satisfactory to the harmony of the smile of the patient by association of treatments - resective gingival surgery and application of botulinum toxin type A. The institution of isolated treatments could not culminate in the excellence of the earned results. Initially, the creation of the new dental zenith during the course of resective gingival surgery promoted the new dental architecture, favoring harmony gingival-dental-facial for the patient. Subsequently, the application of botulinum toxin type A softened the gummy smile, by the uniform dehiscence itself of the upper lip, still promoting smoothness to facial lines of the smile, as can be seen in the nasolabial folds, adjacent to the nostrils, comparing Figures 1 and 9.

Conclusion

In summary, the application of botulinum toxin is an alternative less invasive, faster, safer, and more effective. Moreover, it produces harmonics and pleasing results when applied in target muscles, respecting the appropriate dose and type of smile. Therefore, the technique is a useful adjunct in the esthetic improvement of the smile and provides better results when combined with resective gingival surgery.

Conflict of Interest

The authors declare that they have no conflict of interest.

References

- [1] Bashetty K, Nadig G, Kapoor S. Electrosurgery in aesthetic and restorative dentistry: A literature review and case reports. *J Conserv Dent*. 2009; 12: 139-144.
- [2] Narayan S, Narayan TV, Jacob PC. Correction of gummy smile: A report of two cases. *J Indian Soc Periodontol*. 2011; 15: 421-424.
- [3] Hwang WS, Hur MS, Hu KS, Song WC, Koh KS, Baik HS, et al. Surface anatomy of the lip elevator muscles for the treatment of gummy smile using botulinum toxin. *Angle Orthod*. 2009; 79: 70-77.
- [4] Mazzuco R, Hexsel D. Gummy smile and botulinum toxin: a new approach based on the gingival exposure area. *J Am Acad Dermatol*. 2010; 63: 1042-10451.
- [5] Polo M. Botulinum toxin type A in the treatment of excessive gingivaldisplay. *Am J Orthod Dentofacial Orthop*. 2005; 127: 214-218.
- [6] Mangano A, Mangano A. Current strategies in the treatment of gummy smile using botulinum toxin type A. *Plast Reconstr Surg*. 2012; 129: 1015e.
- [7] Indra AS, Biswas PP, Vineet VT, Yeshaswini T. Botox as an adjunct to orthognathic surgery for a case of severevertical maxillary excess. *J Maxillofac Oral Surg*. 2011; 10: 266-270.
- [8] Jaspers GW, Pijpe J, Jansma J. The use of botulinum toxin type A in cosmetic facial procedures. *Int J Oral Maxillofac Surg*. 2011; 40: 127-133.
- [9] Sucupira E, Abramovitz A. A simplified method for smile enhancement: botulinum toxininjection for gummy smile. *Plast Reconstr Surg*. 2012; 130: 726-728.
- [10] Niamtu J. Botox injections for gummy smiles. *Am J Orthod Dentofacial Orthop*. 2008; 133: 782-783.