

Original Article

Oro-Antral Fistula Repair With Different Surgical Methods: a Retrospective Analysis of 147 Cases

Rasoul Gheisari ¹, Hesam Hosein Zadeh ², Saeid Tavanafar ³¹ Dept. of Oral and Maxillofacial Surgery, School of Dentistry, Shiraz University of Medical Sciences, Shiraz, Iran.² Dental Student, School of Dentistry, Shiraz University of Medical Sciences, Shiraz, Iran.³ Postgraduate Student, Dept. of Oral and Maxillofacial Surgery, School of Dentistry, Shiraz University of Medical Sciences, Shiraz, Iran.

KEY WORDS

Fat Pad;
Maxillary Sinus;
Oroantral Fistula;
Surgical Flaps;Received October 2017;
Received in Revised Form January 2018;
Accepted April 2018;

ABSTRACT

Statement of the Problem: An oro-antral fistula (OAF) creates a passage for oral microbes into maxillary sinus with numerous possible complications.**Purpose:** This retrospective study evaluates the success of three different surgical techniques of OAF repair.**Materials and Method:** Records of patients that were treated for OAF repair were retrieved and reviewed. Data recorded were patients' age, gender, etiology, size, location, duration, and method of repair. According to the surgical technique used to repair the OAF, patients were divided into three groups including buccal flap, palatal flap, and buccal fat pad. All of the patients were locally anesthetized with 2% lidocaine and 1/100000 or 1/80000 epinephrine. Then the edges of the fistula were excised and fistula wall was dissected in a stitched layer by three surgical methods. The three groups were compared concerning the success or failure of surgical technique based on complete closure of OAF after three months postoperatively.**Results:** 147 patients (116 males and 31 females) with adequate records were included in the study. The surgical methods used in patients were, buccal flap in 59 (40.1%), buccal fat pad in 42 (40.8%), and palatal flap in 28 (19%) individuals. Success rates of these techniques were significantly different. Buccal fat pad was the most successful flap (98.3%), followed by buccal flap (89.8%), and palatal flap (85.7%). The most common cause of OAF in this group of patients was dental extraction.**Conclusion:** Buccal fat pad flap seems to be one of the best treatments for the closure of OAF larger than 5 mm.**Corresponding Author:** Tavanafar S., Dept. of Oral and Maxillofacial Surgery, School of Dentistry, Shiraz University of Medical Sciences, Shiraz, Iran. Email: s.tavanafar@gmail.com, tavanafar@sums.ac.ir Tel. +98-7132334481Cite this article as: Gheisari R., Hosein Zadeh H., Tavanafar S. Oro-Antral Fistula Repair With Different Surgical Methods: a Retrospective Analysis of 147 Cases. *J Dent Shiraz Univ Med Sci.*, June 2019; 20(2): 107-112.

Introduction

The maxillary sinus is the largest paranasal sinus and in adults contains roughly 12-15 ml of air. It is a pyramidal structure with its base close to the nasal cavity, the superior portion forms the floor of the orbit, and the apex is towards the zygomatic bone [1]. In some circumstances, it connects to oral cavity through a pathologic path between the two spaces. This communicating path is called oro-antral fistula (OAF) which could be created

by odontogenic inflammatory processes (causing progressive destruction of either the floor or side of the maxillary sinus), or by iatrogenic maneuvers such as dental extractions, or even avascular necrosis (bisphosphonate-related osteonecrosis of the jaw, Figure 1) [2]. However, mostly it occurs as a complication of oral and maxillofacial surgical procedures such as maxillary posterior teeth extractions, implant surgery, cyst and tumor enucleation, orthognathic surgery

(LeFort osteotomies), osteomyelitis, trauma, and pathologic lesions [3]. The most common etiology of OAF is the extraction of posterior maxillary teeth because of their roots proximity to the maxillary sinus and thin antral floor in this area [3].

OAF is a complex defect that involves the soft and hard tissue layers. In the absence of sinus infection, most of the small acute OAF with a diameter of 1 to 2mm will heal spontaneously by the formation of a blood clot and secondary healing [4]. However, larger oro-antral defects that are not diagnosed or are left untreated would rarely heal and subsequent formation of an OAF becomes inevitable. When an OAF is developed, the presence of maxillary sinusitis, epithelialization of the fistula tract, dental apical abscess, osteitis, or osteomyelitis on the communication's margins, dental cysts, foreign bodies, or tumors will prevent spontaneous healing and results in chronic fistula formation. Thus, elimination of the maxillary sinus pathologic conditions is essential for successful treatment of OAF [4]. Drainage and adequate aeration of the sinus should be achieved. In addition, foreign bodies, infected and degenerated polypoid mucosa, and infected bone should be immediately removed, and the defect should be surgically closed [4].

The choice of the appropriate treatment must be according to the width, epithelialization, and presence of infections. In the absence of infection, defects that are less than 3mm in width and without epithelialization might heal spontaneously. Otherwise, infection must be cured before surgery to avoid impaired drainage. Communications wider than 5 mm require the use of rotating and sliding flaps to provide closure [5].

The buccal flap, described in 1930 by Axhausen, uses buccally placed vertical incisions with a thin layer of buccinators muscle to close an OAF [6]. It is a modification of vestibular flap, and it can even be used in cases of severe alveolar resorption. A problem with this technique is a loss of vestibular sulcus [7]. The palatal flap is created by incising the palatal fibro-mucosa with its posterior base supplying the flap blood circulation [8]. This technique is further improved by adding a mucosal flap to the denuded palatal bone [9]. It has the advantage of using palatal mucosa and patients can use their dentures shortly after healing, though it only can be used in premolar region. Excessive rotation to repair

the OAF in the molar region can endanger blood supply of the flap. Another technique for OAF repair is buccal fat pad flap which is one of the most commonly used methods due to the location of the buccal fat pad, ease of access, adequate mobility, and rapid epithelialization of the uncovered fat. The buccal fat pad is located along the posterior of the maxilla and superior to buccinators muscle fiber and can be easily dissected and mobilized to cover OAF [10].

This study aimed to compare three most commonly used techniques in the surgical closure of OAF and assess their success in the repair of OAFs.

Materials and Method

The Ethical Committee approved this research and written informed consent was obtained from all subjects in the study. The records of the patients who had undergone surgery during the past ten years by an experienced surgeon to repair communication of maxillary sinus with oral cavity were retrieved. The complete and reliable files were evaluated. The data records included patient age, gender, etiology, size, location, duration, and the method of surgical treatment. The same experienced surgeon recorded the size and location of all cases. The technique was considered successful when a complete closure of the OAF has occurred after three months. Patients were evaluated before surgery for presence of any pathologic lesion of the maxillary sinus using a panoramic radiograph as the routine procedure of the department (Figure 1).

Three groups of patients according to the surgical

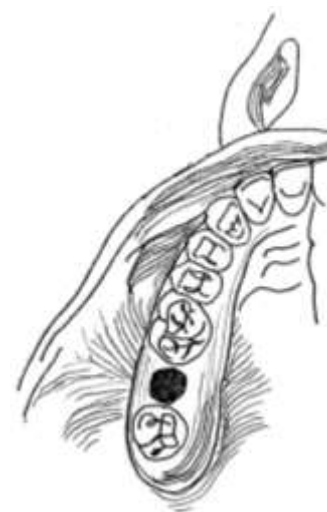

Figure 1: Oroantral Fistula

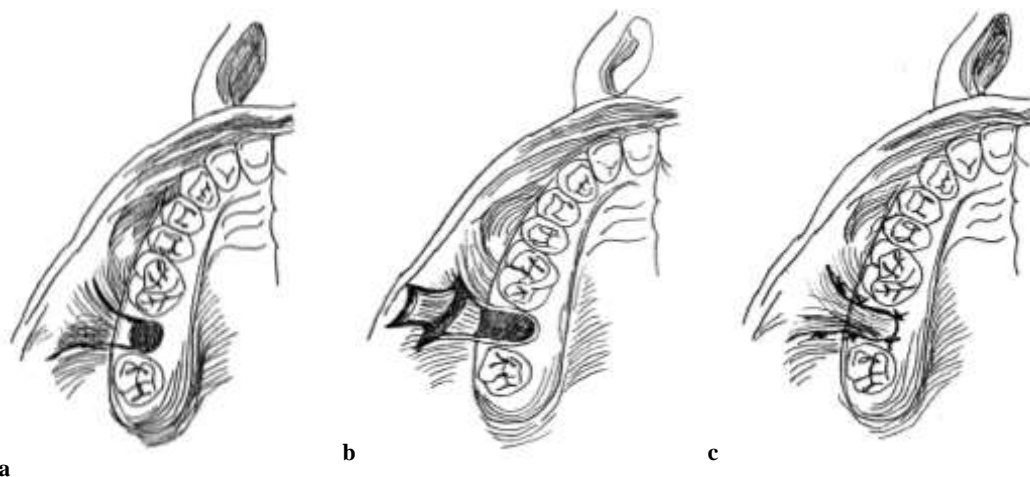


Figure 2a: Outline of buccal flap incision, **b:** Reflection of buccal flap, **c:** Closure of oroantral fistula with buccal flap

method used for the OAF repair were assigned including buccal flaps (Rehrmann's technique) (Figure 2), palatal flaps (rotational advancement) (Figure 3), and buccal fat pad flap (Figure 4) [11-13]. The appropriate surgical method for each patient was selected principally based on location of OAF. OAF in lateral aspect of maxillary ridge were preferably repaired with buccal flap, those located in center of alveolar crest with buccal fat pad flap, and those palatal to alveolar crest were repaired with palatal flap. Other patient's conditions such as vestibular depth, suspected injury to greater palatine artery, and patient's previous medical history were also considered in selecting each surgical method. Following standard protocol, all patients are advised to use a mouthwash of chlorhexidine 0.2%, 2g amoxicillin, and 400 mg ibuprofen as prophylaxis before surgery and continued to take for a week. The area was locally anesthetized using 2% lidocaine with 1/100000 epinephrine. The edges of the fistula wall were prepared,

dissected, and sutured in a single layer by one of the three surgical methods.

Essential advices such as taking medication at the exact time, preventing oral suction, cleaning the area of surgery was given to patients. Patients were advised to return according to the follow up schedules of the department. Those who did not return for follow up were excluded from the study. The size of OAF was measured intra-orally by a periodontal probe.

Incomplete closure of OAF after three months was considered as the failure of surgical technique. The surgery was regarded successful when complete soft tissue coverage of OAF was observed. Data analysis was done using Fishers Exact Test based on Monte Carlo Sig. ($p < 0.05$).

Results

A total of 147 patients with reliable records were included in the study. The mean age of the patients was

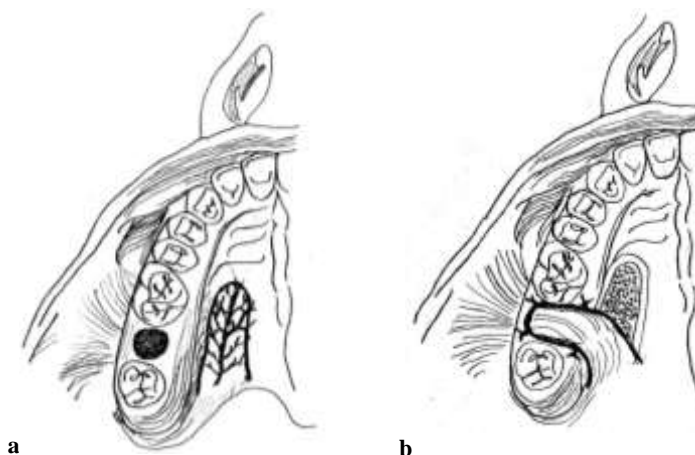


Figure 3a: Outline of palatal flap, **b:** Closure of oroantral fistula with palatal flap

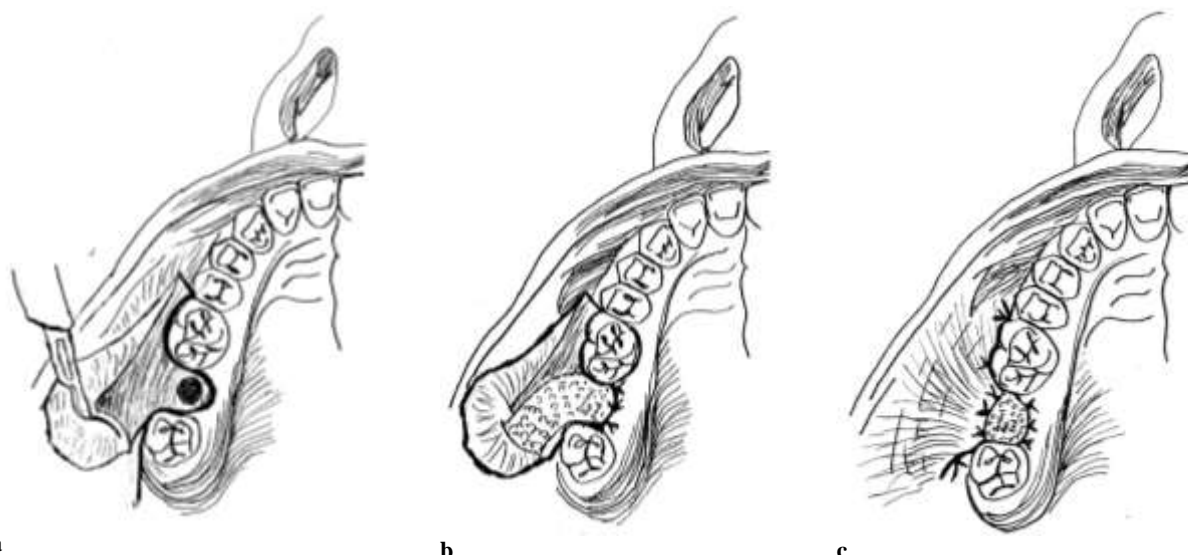


Figure 4a: Outline of initial incision for exposure and traction of buccal fat pad, **b:** Exposure, traction, and securing buccal fat pad flap over the oroantral fistula, **c:** Flap repositioning and partial coverage of buccal fat pad flap

41 with a range from 17 to 75. The number of male and female participants was 116 and 31, respectively. Complicated tooth extraction was the most common cause of the OAF. The size of the OAF ranged from 5 to 10mm. The first maxillary molar area was the most common site, and the duration of OAF was more than one month. Buccal flap was used in 59 patients (55 males and 4 females), palatal flap in 28 patients (19 males and 9 females), and buccal fat pad flap (42 males and 18 females).

Table 1 shows a significant difference in the rate of success among three surgical techniques ($p= 0.033$). The most successful method was buccal fat pad flap (98.3%) followed by buccal flap (89.8%), and palatal flap (85.7%). There were no significant differences between buccal flap and palatal flap regarding success in treatment ($p= 0.721$). Moreover, buccal flap and buccal fat pad flap had no significant difference ($p= 0.061$). However, buccal fat pad flap was more successful than palatal flap ($p= 0.034$).

Table 1: Success rate of different oro-antral closure techniques

Surgical method	Total number of patients	Success(%)*
Buccal flaps	59	89.8 ^{a,b}
Palatal flaps	28	85.7 ^a
Buccal Fat Pad	60	98.3 ^b

* Values with the same superscript letters were not statistically different ($p < .05$).

Discussion

Absolute and long-term closure of the OAF is a challen-

ging task for all maxillofacial surgeons. Several factors should be considered when choosing the most appropriate technique to close OAF such as defect size, anatomic area, time elapsed from its creation, infection, inflammation of sinus, and the presence of foreign bodies. Usually, surgical techniques for OAF repair include open local soft tissue flaps, with or without autonomous alloplastic grafts or implants. Conventional techniques such as a buccal flap, palatal flap, and buccal fat pad flap are assessed in this study to evaluate their effectiveness and safety for the treatment of OAF created during dental procedures. The literature is controversial in determining the most appropriate approach to the treatment of this condition [1-2, 4, 19, 22].

Anatomically, buccal fat pad, also called Bichat’s fat pad, is one of the several encapsulated fat masses which is located on either side of the face between the buccinator muscle and more superficial muscles such as masseter, the zygomaticus major, and the zygomaticus minor [13]. Deep buccal and temporal branches of the maxillary artery and smaller branches of the facial arteries supply buccal fat pad central part and guarantee their successful application in the reconstruction of oral defects [14]. Since its first utilization of buccal fat pad flap, several studies used this technique owing to its success rate and efficiency for OAF treatment. Abuabara *et al.* [15] studied 112 patients with OAF, and they showed that the success rate of this technique is very high and recommended that small defects up to 4mm are better to be repaired by

simple wound stitch but defects larger than 5 mm are treated more successfully using pedicle buccal fat pad flap. Dolanmaz *et al.* [16] successfully used this technique on 75 patients with acute and chronic OAF. Baumann and Ewers [17] successfully used buccal fat pad flap in the reconstruction of multiple defects of the soft and hard palate and for covering the grafted bone without the need for additional coverage. In another study, Poeschl *et al.* [18] reported a success rate of 98% which is similar to our study. Others compared buccal fat pad flap with palatal flap and found that buccal fat pad flap is an appropriate technique for OAF closure and it is a good source when other methods or approaches are failed [19]. Some authors recommended buccal fat pad flap to close small to medium defects [17, 20], while other researchers reported successful repair of defects sized 60×50 mm [13].

The limitation of mouth opening following the surgery is reported when buccal fat pad flap is used [21]. The reason might be the use of this technique to restore defects caused by malignant tumors of the oral cavity, and limitation in mouth opening may be due to the extent of the incision to masticatory muscles. Our study also confirms the excellent capabilities of pedicle fat pad flap. Gentle manipulation, atraumatic procedure, avoiding the severe tension of fat flap, and fat removal, if needed, would minimize the occurrence of complications [15]. Krishanappa *et al.* [22] reviewed various databases for randomized clinical trials assessing the effectiveness and safety of different surgical methods for the treatment of OAFs due to dental procedures. Only one study compared buccal fat pad flap with a buccal flap in 20 patients (25-56 y/o) with OAF that were followed up for two years. The authors did not report any adverse events, and there was no difference for the successful closure of OAF. It is concluded that Bichat's fat pad grafts show excellent results for the closure of OAF and presents low rate of failure and excellent patient satisfaction postoperatively [22].

According to our evaluation in the present study, the success and efficiency rate in buccal flap and buccal fat pad flap was more than palatal flap. The palatal flap would be appropriate for small and medium fistulas in premolar region. The advantage of this technique is the use of the mucous membrane of the hard palate, short recovery after wounds healing, good vascularization,

sufficient thickness, and maintaining texture quality. The buccal fat pad flap is better to be used for large posterior OAFs because of the physical and biological properties of this technique. On the other hand, because of palatal surgical procedures, pain from surgery would be present for two or three months because of secondary epithelial tissue. According to present and previous studies, pedicle fat pad flap due to adequate blood feeding, the ease with surgical technique and the least side effects can be used as a safe approach in OAF closure and oral cavity defects repair. However, this technique has its own complications such as pain more than two weeks, hematoma, and partial loss of flap, scar formation, and infection [19-20]. In addition, graft contraction can cause limitation in mouth opening, which is one of the main disadvantages of buccal fat pad flaps [23].

Conclusion

This retrospective study shows that buccal fat pad flap is a feasible treatment option for closure of OAF larger than 5mm.

Conflict of Interest

None declared.

References

- [1] Killey HC, Kay LW. An analysis of 250 cases of oro-antral fistula treated by the buccal flap operation. *Oral Surg Oral Med Oral Pathol.* 1967; 24: 726-739.
- [2] Anavi Y, Gal G, Silfen R, Calderon S. Palatal rotation-advancement flap for delayed repair of oroantral fistula: a retrospective evaluation of 63 cases. *Oral Surg Oral Med Oral Pathol Oral Radiol Endod.* 2003; 96: 527-534.
- [3] Thoma K, Pajarola GF, Grätz KW, Schmidlin PR. Bioabsorbable root analogue for closure of oroantral communications after tooth extraction: a prospective case-cohort study. *Oral Surg Oral Med Oral Pathol Oral Radiol Endod.* 2006;101: 558-564.
- [4] Yalçın S, Oncü B, Emes Y, Atalay B, Aktaş I. Surgical treatment of oroantral fistulas: a clinical study of 23 cases. *J Oral Maxillofac Surg.* 2011; 69: 333-339.
- [5] Kirmeier R, Arnetzl C, Robl T, Payer M, Lorenzoni M, Jakse N. Reproducibility of volumetric measurements on maxillary sinuses. *Int J Oral Maxillofac Surg.* 2011; 40: 195-199.
- [6] Axhausen G. Zur methodic des verschlusses von defekte-

- nim alveolarforsat oberkiefer. Deutsche Monatschrift fur Zahnheilkunde. 1930; 48: 193-196.
- [7] Killey HC, Kay LW. An analysis of 250 cases of oro-antral fistula treated by the buccal flap operation. *Oral Surg Oral Med Oral Pathol.* 1967; 24: 726-739.
- [8] McGregor IA, McGregor FM. Reconstructive techniques in intraoral surgery. In: McGregor FM (Ed). *Cancer of the face and mouth.* 1th ed. London: Churchill Livingstone; 1986. p. 412-419.
- [9] Yamazaki Y, Yamaoka M, Hirayama M, Shimada H. The submucosal island flap in the closure of oro-antral fistula. *Br J Oral Maxillofac Surg.* 1985; 23: 259-263.
- [10] Ferrari S, Ferri A, Bianchi B, Copelli C, Magri AS, Sesenna E. A novel technique for cheek mucosa defect reconstruction using a pedicled buccal fatpad and buccinator myomucosal island flap. *Oral Oncol.* 2009; 45: 59-62.
- [11] Rehrmann A. Eine Methode zur Schliessung von Kieferhöhlenperforationen. *Dtsch Zahnärztl Wschr.* 1936; 39: 1136-1138.
- [12] Kruger GO. *Textbook of oral and maxillofacial surgery.* 6th ed. Mosby: St Louis; 1984. p.226.
- [13] Hanazawa Y, Itoh K, Mabashi T, Sato K. Closure of oroantral communications using a pedicled buccal fat pad graft. *J Oral Maxillofac Surg.* 1995; 53: 771-775.
- [14] Nezafati S, Vafaii A, Ghojzadeh M. Comparison of pedicled buccal fat pad flap with buccal flap for closure of oro-antralcommunication. *Int J Oral Maxillofac Surg.* 2012; 41: 624-628.
- [15] Abuabara A, Cortez AL, Passeri LA, de Moraes M, Moreira RW. Evaluation of different treatments for oro-antral/oronasal communications: experience of 112 cases. *Int J Oral Maxillofac Surg.* 2006; 35: 155-158.
- [16] Dolanmaz D, Tuz H, Bayraktar S, Metin M, Erdem E, Baykul T. Use of pedicled buccal fat pad in the closure of oroantral communication: analysis of 75 cases. *Quintessence Int.* 2004; 35: 241-246.
- [17] Baumann A, Ewers R. Application of the buccal fat pad in oral reconstruction. *J Oral Maxillofac Surg.* 2000; 58: 389-392.
- [18] Poeschl PW, Baumann A, Russmueller G, Poeschl E, Klug C, Ewers R. Closure of oroantral communications with Bichat's buccal fat pad. *J Oral Maxillofac Surg.* 2009; 67: 1460-1466.
- [19] el-Hakim IE, el-Fakharany AM. The use of the pedicled buccal fat pad (BFP) and palatal rotating flaps in closure of oroantral communication and palatal defects. *J Laryngol Otol.* 1999; 113: 834-838.
- [20] Rapidis AD, Alexandridis CA, Eleftheriadis E, Angelopoulos AP. The use of the buccal fat pad for reconstruction of oral defects: review of the literature and report of 15 cases. *J Oral Maxillofac Surg.* 2000; 58: 158-163.
- [21] Abad-Gallegos M, Figueiredo R, Rodríguez-Baeza A, Gay-Escoda C. Use of Bichat's buccal fat pad for the sealing of orosinus communications. A presentation of 8 cases. *Med Oral Patol Oral Cir Bucal.* 2011; 16: e215-e219.
- [22] Kiran Kumar Krishanappa S, Eachempati P, Kumbargere Nagraj S, Shetty NY, Moe S, Aggarwal H, et al. Interventions for treating oro-antral communications and fistulae due to dental procedures. *Cochrane Database Syst Rev.* 2018; 8: CD011784.
- [23] Chien CY, Hwang CF, Chuang HC, Jeng SF, Su CY. Comparison of radial forearm free flap, pedicled buccal fat pad flap and split-thickness skin graft in reconstruction of buccal mucosal defect. *Oral Oncol.* 2005; 41: 694-697.