

Original Article

## Evaluation of the Effect of a Topical Gel Form of *Pistacia Atlantica* and *Trachyspermum Ammi* on Induced Oral Mucositis in Male Golden Hamsters by Bio-Marker Indices and Stereological Assessment

Nader Tanideh, PhD<sup>1</sup>; Abbas Ali Zareh, DMD<sup>2</sup>; Mohammad Mehdi Fani, DMD, MScD<sup>3</sup>; Maryam Mardani, DMD, MScD<sup>4</sup>; Farnaz Farrokhi, DMD<sup>5</sup>; Ali Talati, MS<sup>6</sup>; Omid Koochi Hosseinabadi, BS<sup>7</sup>; Mahsa Kamali, MS<sup>1</sup>

<sup>1</sup> Stem Cell Technology Research Center, Shiraz University of Medical Sciences, Shiraz, Iran.

<sup>2</sup> School of Dental, Shiraz University of Medical Sciences, Shiraz, Iran.

<sup>3</sup> Dept. of Oral and Maxillofacial Medicine, School of Dentistry, Shiraz University of Medical Sciences, Shiraz, Iran.

<sup>4</sup> Dept. of Oral Medicine, School of Dentistry, Shiraz University of Medical Sciences, Shiraz, Iran.

<sup>5</sup> Student Research Committee, School of Dentistry, Shiraz University of Medical Sciences, Shiraz, Iran.

<sup>6</sup> Young Researchers and Elite Club, Shiraz Branch, Islamic Azad University, Shiraz, Iran.

<sup>7</sup> Laboratory Animals Center, Shiraz University of Medical Sciences, Shiraz, Iran.

### KEY WORDS

Oral Mucositis;

Animal Model;

*Pistacia atlantica*;

*Trachyspermum Ammi*;

Chemotherapy;

### ABSTRACT

**Statement of the Problem:** Oral mucositis (OM) is a common inflammatory complication consequent to chemotherapy or radiotherapy in cancer patients that affects their quality of life. Therefore, finding an effective treatment for OM is always imperative.

**Purpose:** The purpose of this experimental study was to measure the stereological, anti-inflammatory and antioxidant markers of hydro-alcoholic extract of *Pistacia Atlantica* (*P. atlantica*) leaves, *Trachyspermum Ammi* (*T. ammi*) fruits and their mixture on induced OM in hamsters.

**Materials and Method:** In Experimental study, OM was generated by the method employed by Tanideh *et al.*, in 90 hamsters, by 5-FU (5-fluorouracil 65 mg/kg, IP). All the animals were divided into 5 groups: control, topical gel base, hydro-alcoholic extract 3% of *P. atlantica*, hydro-alcoholic extract 1% of *T. ammi*, and a mixture of the extracts of the two plants. On days 13, 15, and 17, the cheek pouch samples were harvested. Stereological scores and the levels of malondialdehyde (MDA), Superoxide dismutase (SOD), myeloperoxidase (MPO), and interleukin-1B (IL-1B) in the pouch tissue were measured.

**Results:** Lower levels of MPO, MDA, and IL-1B and an increase of SOD level were discovered in the mixture-treated group in comparison with other groups. As an aspect of MDA, no significant differences were detected between the topical gel form of *P. atlantica* and *T. ammi* groups on days 13 ( $p=0.648$ ), 15 ( $p=0.981$ ) and 17 ( $p=0.540$ ). No variations of MPO were detected among *P. atlantica* and *T. ammi* groups on days 13 ( $p=0.159$ ) and 15 ( $p=0.694$ ); however, the MPO activity of the *T. ammi* group was significantly lower than the *P. atlantica* group on day 17 ( $5.57\pm0.56$  vs.  $6.48\pm0.35$  U/ml,  $p<.001$ ). The volume density of the epithelium increased in the mixture- treated group ( $p<0.05$ ).

**Conclusion:** The results of this study indicated that the mixture of *P. atlantica* leaves and *T. Ammi* fruits might be effective in the treatment of OM.

**Corresponding Author:** Farrokhi F, School of Dentistry, Shiraz University of Medical Sciences, Shiraz, Iran. Tel: +98-9176889819 Email: ffrkhi@ymail.com

Received: July 2018;

Revised: September 2018;

Accepted: December 2018;

**Cite this article as:** Tanideh N, Zareh Aa, Fani MM, Mardani M, Farrokhi F, Talati A, Koochi Hosseinabadi O, Kamali M. Evaluation of the Effect of a Topical Gel Form of *Pistacia Atlantica* and *Trachyspermum Ammi* on Induced Oral Mucositis in Male Golden Hamsters by Bio-Marker Indices and Stereological Assessment. *J Dent Shiraz Univ Med Sci*. December. 2019; 20(4): 240-248.

### Introduction

Oral mucositis (OM) is one of the side effects of chemotherapy or radiotherapy treatment in patients who suffer

from head and neck cancer. Oral complications, which arise from chemotherapy or radiation therapy, include xerostomia (dry mouth), bacterial, fungal, or viral infec-

tion, dental caries, loss of taste, and osteoradionecrosis. OM manifests as erythematous and ulceration lesions of the oral mucosa that can harmfully affect the patient's treatment diet, and quality of life [1]. In fact, mucositis initiates when the gastrointestinal mucosa is exposed to cytotoxic agents, such as fluorouracil, methotrexate, and cytarabine, causing cellular DNA damage and cell death. This mostly occurs through the formation of reactive oxygen species (ROS) and oxidative stress generation. ROS directly induces tissue injury and triggers a cascade of inflammatory trails [2]. Antioxidants are intimately elaborated in the prevention of cellular injury. Catalase, SOD, and glutathione peroxidase are some of the natural antioxidants established in the body. They deactivate free radicals as a natural by-product of normal cell processes [3]. It is reported the compounds that have antioxidant activity could inhibit the occurrence of diseases, because they can hunt the free radicals or induce antioxidant enzymes [4].

The current clinical management of oral mucositis is largely focused on pain management, nutritional support, and maintenance of good oral hygiene, cryotherapy, growth factors (Palifermin, Amgen), anti-inflammatory agents (Benzzydamine hydrochloride), anti-oxidant agents (Amifostine) and low-level laser therapy, which is now being developed. Since some of the therapeutic strategies have more toxicity and are extremely costly, the trend to use cheaper compounds that have fewer side effects as well as potential therapeutic effects have become more and more popular [5].

*Trachyspermum Ammi* (*T. ammi*) is an annual herb in the Apiaceae family that is growing in Iran. Several biological effects of *T. ammi* such as anti-inflammatory [6], antiviral [7], antifungal [8], and analgesic [9], and antioxidant activity [10] were reported. *Pistacia Atlantica* (*P. atlantica*) has different species, which are used as an antibacterial, antifungal, antiviral, anti-atherogenic, hypoglycemia, antitumor and hepatic protective [11]. Both, Pistachio leaves [12] and *T. ammi* fruits [13], have phenolic compounds and antioxidant properties, which act as a scavenger of the 1-diphenyl-2-picrylhydrazyl (DPPH). DPPH is a stable, light sensitive, nitrogen-centered free radical, which produces violet color in methanol solution [13].

The aim of this study was to evaluate the effect of topical gel form of the hydroalcoholic extracts of *P.*

*atlantica* leaves, *T. ammi* fruits and their mixture on induced OM by 5-FU in the male golden hamsters.

## Materials and Method

### Study protocol

Ninety male Syrian hamsters (10±10g, 8-10 weeks old) were kept in the standard condition, 12-hours light, and 12-hours dark at the temperature of 23±1°C and 55±5% humidity. The ethics committee of Shiraz University of Medical Sciences approved this research (# 95-13011-0301). The hamsters were randomly divided into 5 groups (18 animals in each group). Oral mucositis was induced by 5-FU on days 0, 5, and 10 (65 mg/kg, IP). The cheek pouch mucosa was scratched with an 18-gauge sterile needle on days three and four [1]. The first group of the hamsters was served as the control (without treatment), the second group received topical base gel, and the third and fourth groups were treated with the hydroalcoholic extracts of *P. atlantica* leaves 3% and *T. ammi* fruits 1% as a gel form on the cheek pouch mucosa, respectively. The fifth group was treated with a mixture of these two plant extracts. To ensure that it was not swallowed, all the animals were forbidden to have any food or water for 60 minutes after the drug applications. From each group, six hamsters were selected randomly and sacrificed on days 13, 15 and 17 respectively.

### Preparation of hydroalcoholic extracts

The leaves of *P. atlantica* and fruits of *T. ammi* were collected from Fars province, Iran. A grinder was used to powder the dried plants. Then 500 g of the powdered materials were mixed with ethanol (80%) and were stirred together for one hour. Afterwards, the extract was dried at the oven temperature of 50°C. Finally, the extracts of *T. ammi* 1% and *P. atlantica* 3% were prepared.

### Stereological study

The oral mucosa was sectioned axially and ten 4-µm and ten 26-µm sections per animal were sampled in a systematic uniform random pattern. The sections were stained with both Heidenhain's AZAN trichrome, and hematoxylin-eosin (H&E). Oral mucosa microscopic analyses were applied using a video microscopy system (E-200; Nikon™; Tokyo, Japan). The sections of 4-µm were used to measure the volume density of the oral epithelium. Briefly, a point grid was overlaid on the monitor and the following formula was used to measure

the volume density ( $V_v$ ) of the favored structure:  $V_v = \Sigma P$  (structure) /  $\Sigma P$  (reference).

In this equation,  $\Sigma P$  (structure) and  $\Sigma P$  (reference) are the total points, hitting of the favored structure and reference tissue. To estimate the mean height of the layers (epithelium, whole mucosa), the isotropic lines were imposed on the images of the 4- $\mu$ m sections of the mucosa.

#### Measurement of malondialdehyde (MDA)

We accomplished the tissue MDA assessment by measuring the thiobarbituric acid reactive substances in the PBS tissue homogenate. Since MDA is one of the end products of lipid peroxidation [14], by evaluating the MDA level, we can measure and scale the extent of lipid peroxidation.

#### Superoxide dismutase (SOD) assay

SOD detection kit (Biorex Fars, Iran) was used to determine the sum of SOD activity. To form a red formazan dye, firstly, we needed to generate superoxide radicals, which required xanthine and xanthine oxidase to show reaction with 2-(4-iodophenyl)-3-(4-nitrophenol)-5-phenyltetrazolium chloride. A Standard curve was used for SOD levels docketed at 505 nm and represented as U/g wet tissue.

#### Myeloperoxidase (MPO) assay

Hydrogen peroxide and o-dianisidine dihydrochloride are the substrates, which can be used to measure the MPO activity in the tissues [15]. In short form, the collected check pouch tissues were scaled and then mixed well in a solution containing 0.5% (w/v) hexadecyl-

trimethylammonium bromide dissolved in 10 mmol/L potassium phosphate buffer (pH 7.4) to be fully homogenized. Afterwards, it was centrifuged for 30 minutes at the speed of 20,000 rpm at 4°C. Subsequently, an aliquot of supernatant was removed and 1.6 mmol/L tetramethylbenzidine and 0.1 mmol/L hydrogen peroxide ( $H_2O_2$ ) were added to the reaction mixture. Next, in order to evaluate the rate of change in absorbance, a spectrophotometer at 650 nm was used. MPO activity was specified as the quantity of the enzyme required to degrade 1 mmol of  $H_2O_2$  at 37°C and represented in U/g wet tissue.

#### Interleukin-1B (IL-1B) level assay

Commercial quantities of enzyme-linked immunosorbent assay (ELISA) kit were used to specify the tissue content of IL-1B (Biosource, USA).

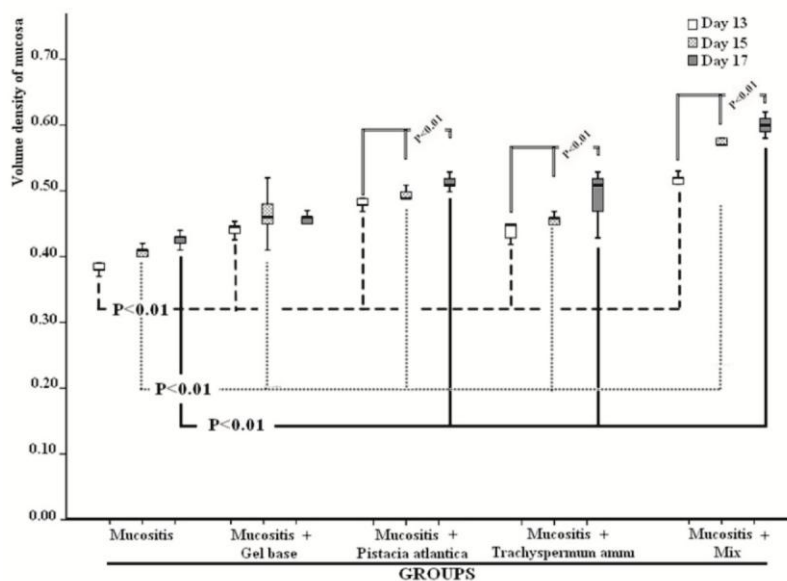
#### Statistical analyses

All statistical analyses were performed using SPSS® statistical software, version 21 (SPSS Inc., Chicago, IL, USA). In order to assess the normal distribution of the collected data, one-sample-Kolmogorov-Smirnov test was used. All data were analyzed using one-way ANOVA and completed by post-hoc Tukey test.  $p < 0.05$  was considered statistically significant.

## Results

#### Stereology assessment

Figure 1 shows the mean volume density of the epithelium on days 13, 15 and 17 within all 5 different groups, respectively.

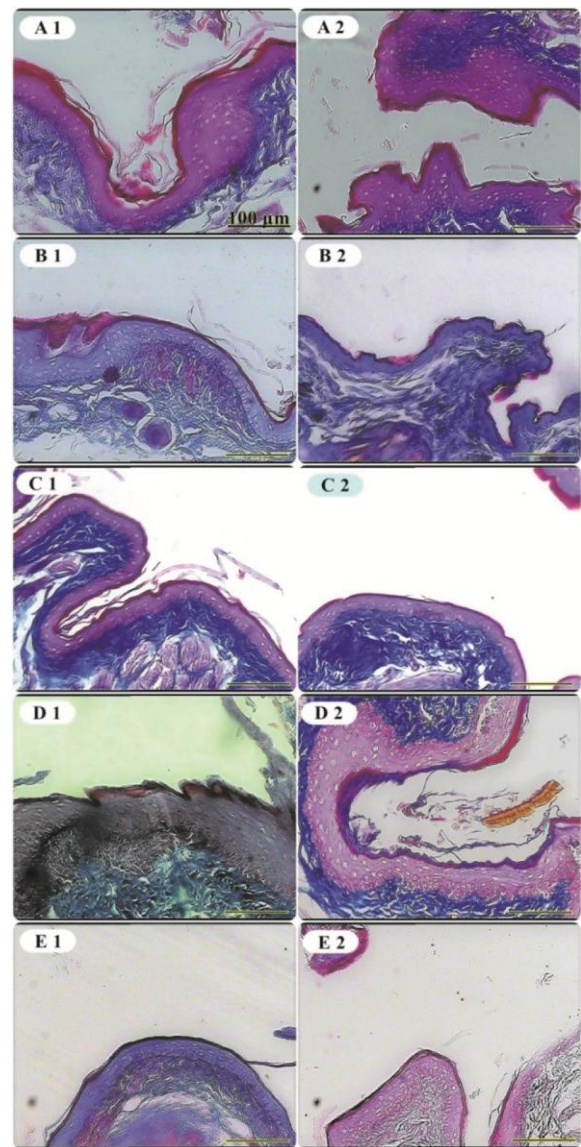


**Figure 1:** The mean  $\pm$  SD comparison of volume density between five different groups in 3 days of sampling. Significant differences ( $p < 0.05$ ) between 3 days were indicated by an asterisk.

As shown, on day 13, the mean volume density of the epithelium in the mixed group was significantly higher compared to other groups ( $p < 0.001$ ). This included 3.4%, 3.6%, 7.2%, and 13.6% increase against the *P. atlantica*, *T. ammi* gel base, and the control groups, respectively. In addition, *P. atlantica* and *T. ammi* separately had a higher mean volume of the density of the epithelium in comparison to both control and gel base groups ( $p < 0.001$ ). Nevertheless, no notable difference existed between *P. atlantica* and *T. ammi* separately ( $p = 0.998$ ). The difference between the gel base and control group was also significant ( $p < 0.001$ ). Moreover, on day 15, there was a significantly higher mean volume density of the epithelium in the mixed group compared to the all other groups as 7.4%, 8.0%, 10.7%, and 16.2% increase against *P. atlantica*, *T. ammi*, gel base and control groups, respectively ( $p < 0.001$ ). The *P. atlantica* and *T. ammi* separately had a higher mean volume of the density of the epithelium in comparison to the control group ( $p < 0.001$ ), and the gel base groups ( $p = 0.098$  and  $p = 0.233$ , respectively). Although no significant difference were found between *P. atlantica* and *T. ammi* separately ( $p = 0.990$ ), the difference between the gel base and control groups was significant ( $p = 0.002$ ). On day 17, the mean volume density of the epithelium in the mixed group was outstandingly higher than all other groups as 8.6%, 10.8%, 14.2% and 17.4% increase against *P. atlantica*, *T. ammi*, gel base and control groups, respectively ( $p < 0.001$ ). *P. atlantica* had a higher mean volume of the density of the epithelium in comparison to both control and gel base groups ( $p < 0.001$  and  $p = 0.004$ , respectively). Besides, *T. ammi* had only a higher mean volume of the density of the epithelium in comparison to the control group ( $p = 0.001$ ). No significant difference was between *P. atlantica* and *T. ammi* separately ( $p = 0.501$ ) and between gel base and control groups ( $p = 0.168$ ). The micrograph of the thickness of the epithelium and the connective tissue of the cheek pouch mucosa of different groups, on days 13 and 17, are illustrated in Figure 2.

#### Tissue MDA level assessment

Based on the groups of this study, on days 13, 15 and 17, the tissue MDA concentrations are shown in Figure 3, respectively. Based on the results, the MDA concentration in the gel base and control groups had no signifi-

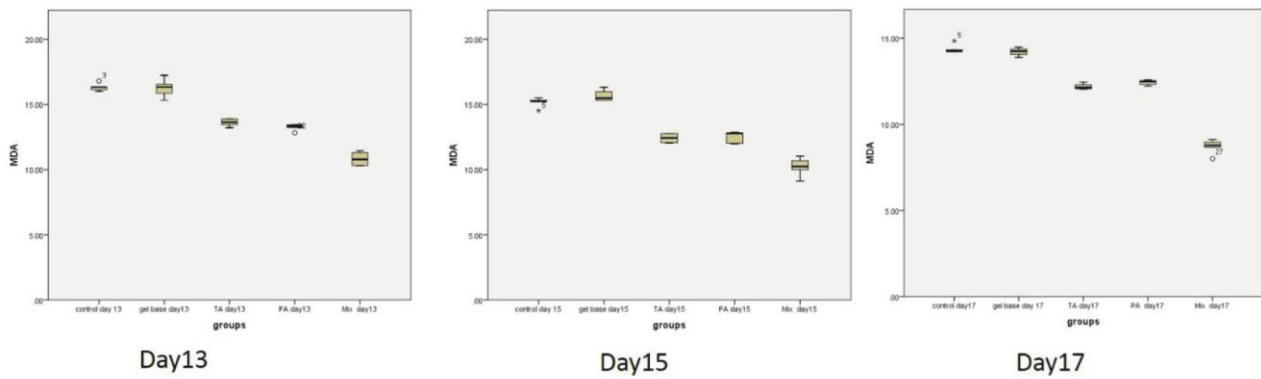


**Figure 2:** The micrograph of the thickness of the epithelium and connective tissue of the mucosa of different groups. A1) *P. atlantica* on day 13<sup>th</sup>, A2) *P. atlantica* on day 17<sup>th</sup> B1) Control group on day 13<sup>th</sup>, B2) Control group on day 17<sup>th</sup> C1) Gel base group on day 13<sup>th</sup>, C2) Gel base group on day 17<sup>th</sup> D1) Mixed group on day 13<sup>th</sup>, D2) Mixed group on day 17<sup>th</sup> E1) *T. ammi* on day 13<sup>th</sup>, E2) *T. ammi* on day 17<sup>th</sup>

cant changes on days 13 ( $p = 1.000$ ), 15 ( $p = 0.215$ ) and 17 ( $p = 0.750$ ). However, the MDA concentration was higher in the control and gel base groups compared to all the three treatment groups within all the three days ( $p < 0.05$ ), indicating more oxidative stress in the gel base and control groups which were relieved using these treatments. Additionally, the effectiveness of mixed treatment was higher than *P. atlantica* and *T. ammi* separately on days 13, 15, and 17 ( $p < 0.001$ ).

No significant differences were found between *P. atlantica* and *T. ammi* groups on days 13 ( $p = 0.648$ ), 15 ( $p = 0.981$ ) and 17 ( $p = 0.540$ ).





**Figure 3:** The mean  $\pm$  SD comparison of MDA concentration between five different groups in 3 days of sampling. Significant differences ( $p < 0.05$ ) between 3 days were indicated by an asterisk.

**Tissue MPO activity**

The MPO activity of the tissues on days 13, 15 and 17 is shown in Figure 4, respectively. As the figure illustrated, among all the three treatment groups, MPO activity was higher in the control and gel base groups within the three days ( $p < 0.05$ ). Nevertheless, there were no significant variations in MPO activity between the gel base and control groups on day 13 ( $p = 0.912$ ), 15 ( $p = 0.994$ ) and 17 ( $p = 0.703$ ). Furthermore, the effectiveness of the mixed treatment was more than that of *P. atlantica* and *T. ammi* separately on days 13 ( $p < 0.001$  and  $p = 0.019$ ), 15 ( $p < 0.001$  and  $p = 0.001$ ) and 17 (both  $p < 0.001$ ). Although no significant differences were observed between the *P. atlantica* and *T. ammi* groups on days 13 ( $p = 0.159$ ) and 15 ( $p = 0.694$ ), the MPO activity of *T. ammi* was significantly lower than *P. atlantica* on day 17 ( $5.57 \pm 0.56$  vs.  $6.48 \pm 0.35$  U/ml,  $p < 0.001$ ).

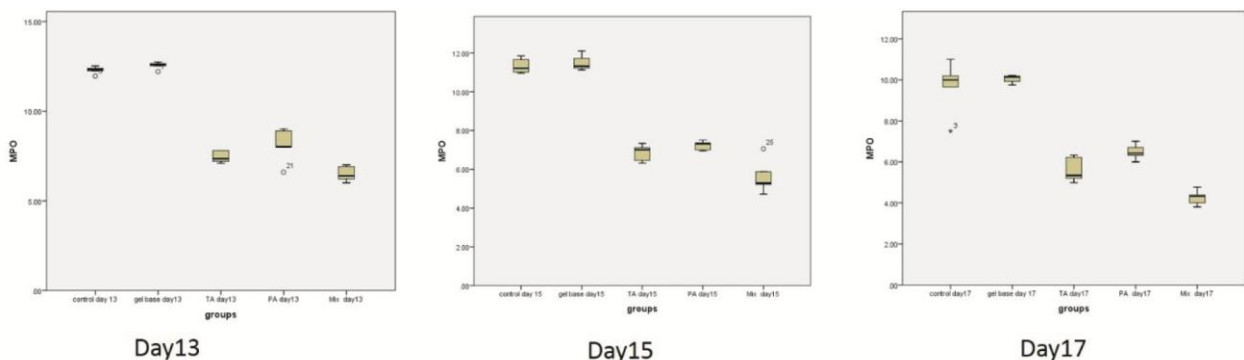
**Tissue SOD activity**

In the treatment groups, the SOD activity of the tissue on days 13, 15 and 17 is shown in Figure 5, respectively. Among the gel base and control groups, there were no significant variations in SOD activity on days 13 ( $p = 0.534$ ), 15 ( $p = 0.814$ ) and 17 ( $p = 0.433$ ). The SOD ac-

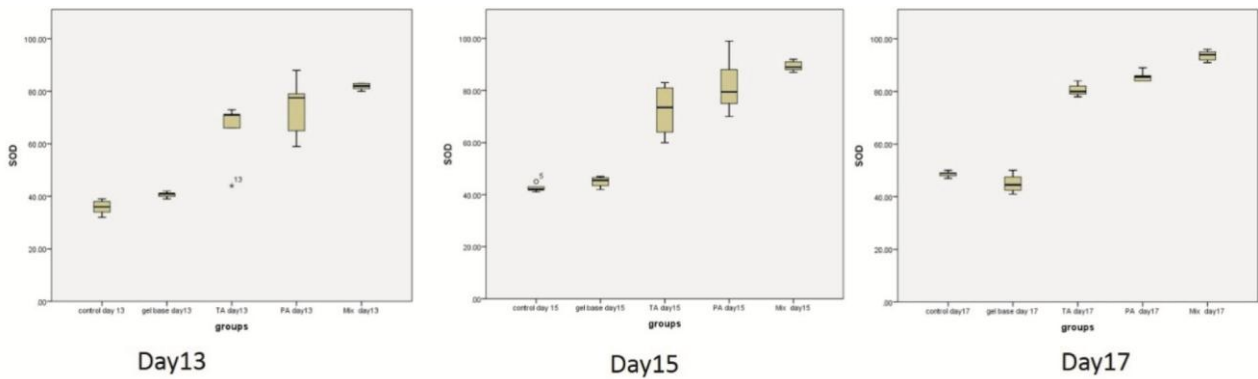
tivity was lower in the control and gel base groups compared to the rest of the treatment groups within these three days ( $p < 0.05$ ), revealing more oxidative stress and inflammation in the gel base and control groups. In addition, the effectiveness of the mixed treatment was higher than *P. atlantica* and *T. ammi* independently on days 15 (both  $p < 0.001$ ), and 17 ( $p < 0.001$ ). Although no significant differences were detected between *P. atlantica* and *T. ammi* groups on day 13 ( $p = 0.833$ ), still the SOD activity was significantly lower than *T. ammi* in comparison to *P. atlantica* on days 15 ( $p < 0.001$ ) and 17 ( $p = 0.004$ ).

**IL-1B measurement**

The tissue IL-1B level in the treatment groups on days 13, 15 and 17 days is illustrated in Figure 6, respectively. There were no significant difference in the IL-1B level among the gel base and control groups on days 13 ( $p = 0.931$ ) and 17 ( $p = 0.842$ ); nevertheless, this difference was significant on day 15 ( $p = 0.016$ ). The IL-1B level was more in the control and gel base groups than the other groups within all three days ( $p < 0.05$ ), except for day 13 between the gel base and *T. ammi* groups ( $p = 0.129$ ).



**Figure 4:** The mean  $\pm$  SD comparison of MPO activity among five different groups in 3 days of sampling. Significant differences ( $p < 0.05$ ) between 3 days were indicated by an asterisk.



**Figure 5:** The mean  $\pm$  SD comparison of SOD activity among five different groups in 3 days of sampling. Significant differences ( $p < 0.05$ ) between 3 days were indicated by an asterisk.

The effectiveness of the mixed treatment was higher than *P. atlantica* and *T. ammi* independently on days 15 ( $p < 0.001$ ), and 17 ( $p < 0.001$ ) and against *T. ammi* treatment group on day 13 ( $p < 0.001$ ). Although no significant differences were found between the *P. atlantica* and *T. ammi* groups on days 13 ( $p = 0.063$ ) and 17 ( $p = 0.131$ ), the IL-1B level was significantly higher than *T. ammi* in comparison to *P. atlantica* on day 15 ( $19.23 \pm 0.37$  vs.  $17.84 \pm 0.40$  mmol/l,  $p < 0.001$ ).

### Discussion

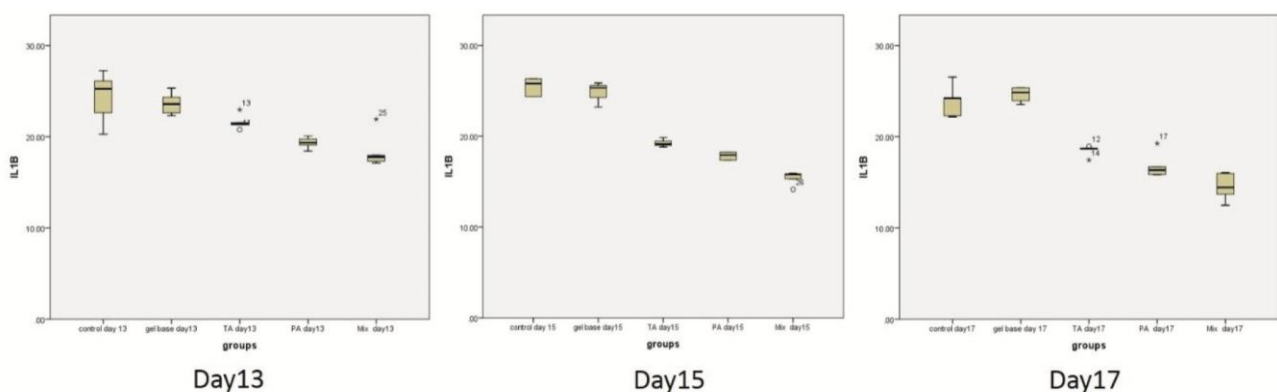
This study was performed to evaluate the stereological, antioxidant and anti-inflammatory markers of *P. atlantica*, *T. ammi* independently and the combination of the two plants on induced OM in the male golden hamsters. In our study, we measured MDA, MPO, SOD, and IL-1B concentrations in all groups on days 13, 15 and 17, respectively. Based on our results, there were no significant changes in MDA, MPO, and SOD level of concentrations among the gel base and control groups on days 13, 15 and 17. Lower MPO, MDA, and IL-1B levels and superior activities of SOD were dis-

covered in the mixed treatment group compared to the other groups.

Currently, there is more evidence based on the experimental researches, suggesting that both *P. atlantica* and *T. ammi* are antioxidant, anti-inflammatory, and cryo-protective agents, which are beneficial in the protection against cancer treatment-related normal tissue injury [16-20].

The major components of *P. atlantica* leaves are  $\alpha$ -tocopherols and some important sterols that have antioxidant properties and health benefits such as being precursors of vitamin D and lowering blood cholesterol [20]. Their antioxidant activities are carried to the attendance of tocopherols and tocotrienols and are as active as vitamin E [21-22]. Tanideh *et al.* [23] showed the use of *P. atlantica* essential oil accelerates the healing of OM lesions in hamsters due to its major component, unsaponifiable matter.

The two major constituents of unsaponifiable matter, which are known as natural antioxidants, are triterpenic compounds or phytosterols and vitamin E (in the forms of tocopherols and tocotrienols) and triterpenic compou-



**Figure 6:** The mean  $\pm$  SD comparison of IL-1B activity among five different groups in 3 days of sampling. Significant differences ( $p < 0.05$ ) between 3 days were indicated by an asterisk.

nds or phytosterols [24].

El-Housseiny *et al.* [25] found that a vitamin E enriched diet could be beneficial in the treatment of patients with oral mucositis. The therapeutic role of *P.atlantica* leaves for oral mucositis in golden hamsters may be similar to vitamin E, which is in consistent with the findings of El-Housseiny *et al.* [25] Uçüncü *et al.* [26] found that vitamin E and L-carnitine remarkably reduce both the severity of oral mucositis and the level of MDA. The researchers offered antioxidants and some micronutrients as therapeutic agents. In another study, it was shown that vitamin E might be an effective therapy in patients with chemotherapy-induced mucositis [27]. Mutlu-Turkoglu *et al.* [28] reported that vitamin E was effective in the prevention of radiation-induced intestinal injury in rats by ameliorating disturbances in pro-oxidant-antioxidant balance.

Consistently, in our study, MDA and MPO levels decreased in the treatment groups, and this reduction may be attributed to the protective effect of *P. atlantica* leaves, which might in turn be due to the presence of tocopherols and tocotrienols.

The other plant used in this study was *T. ammi*, also known as Ajowan caraway. *T. ammi* methanol fruit extract contains potent antioxidant activity against DPPH [29]. Khan *et al.* [30] found out that *T. ammi* seed had a novel compound with activity against cariogenic properties of streptococcus mutans. It reduced both streptococcus mutans adherence as well as the biofilm establishment significantly.

During granuloma tissue formation, the number of fibroblasts and synthesis of collagen and mucopolysaccharides may increase, causing anti-inflammatory activity [31]. The phytochemical analysis of *T. ammi* aqueous extract and *T. ammi* ethanol extract revealed components like terpenes, glycosides, and sterols, which exerted active anti-inflammatory effects. Besides, the fruit extract had an anti-inflammatory activity due to the presence of certain polar constituents such as flavonoids and glycosides [23]. Our data indicated that the combination of *P. atlantica* and *T. ammi* had a protective role of anti-oxidative enzymes including, MDA, MPO, and SOD in the pathogenesis of OM. In this study, we have demonstrated that the combination of *P. atlantica* and *T. ammi* could decrease MDA and MPO concentration and increase SOD activity compared to the other groups.

The stereological results of our current study indicated that the mixture of *P. atlantica* and *T. ammi* extracts promotes the epithelium tissue regeneration compared to the control and gel base groups. These findings were in agreement with those obtained in the previous studies, demonstrating that *P. atlantica* had some healing effects, especially in histopathological findings [32]. Our findings are in the same line with those of the study conducted to investigate the wound healing potential of the leaves of eucalyptus citriodoral in golden hamsters. It was shown that tannins promote wound healing through several cellular mechanisms such as scavenging of free radicals and ROS, promoting contraction of the wound, and increasing the formation of capillary vessels and fibroblasts [33]. During the re-epithelialization of the wound, the keratinocyte migrates from the edge of the wound, and the proliferation depends on the interaction of the keratinocytes with dermal fibroblasts and the extracellular matrix, specifying the role of the fibroblasts on the reconstitution of the dermal-epidermal junction [34].

### Conclusion

The use of the topical gel form of hydroalcoholic extracts of *P. atlantica* leave, *T. ammi* fruit, and their mixture might be associated with the repair of OM by reducing the levels of MPO and MDA,IL-1B, increasing the activity of SOD and the volume of the epithelium. This study indicated that the mixture of *P. atlantica* and *T. ammi* might be effective in the treatment of OM.

### Acknowledgment

The authors thank the Vice-Chancellery of Shiraz University of Medical Sciences for supporting this research (Grant #93-01-67-9004). This manuscript is based on the thesis of Abbas Ali Zareh for partial fulfillment of DDS degree.

### Conflict of Interest

There is no conflict of interest to declare.

### References

- [1] Tanideh N, Tavakoli P, Saghiri MA, Garcia-Godoy F, Amanat D, Tadbir AA, et al. Healing acceleration in hamsters of oral mucositis induced by 5-fluorouracil

- with topical *Calendula officinalis*. *Oral Surg Oral Med Oral Pathol Oral Radiol*. 2013; 115: 332-338.
- [2] Lee CS, Ryan EJ, Doherty GA. Gastro-intestinal toxicity of chemotherapeutics in colorectal cancer: the role of inflammation. *World J Gastroenterol*. 2014; 20: 3751-361.
- [3] Halliwell B. The antioxidant paradox. *Lancet*. 2000; 355: 1179-1180.
- [4] Chatterjee S, Goswami N, Bhatnagar P. Estimation of Phenolic Components and in vitro Antioxidant Activity of Fennel (*Foeniculum vulgare*) and Ajwain (*Trachyspermum ammi*) seeds. *Advances in Bioresearch*. 2012; 3: 109-118.
- [5] Stone R, Fliedner MC, Smiet AC. Management of oral mucositis in patients with cancer. *Eur J Oncol Nurs*. 2005; 9 Suppl 1: S24-S32.
- [6] Thangam C, Dhananjayan R. Antiinflammatory potential of the seeds of *Carum copticum* Linn. *Indian Journal of Pharmacology*. 2003; 35: 388-391.
- [7] Hussein G, Miyashiro H, Nakamura N, Hattori M, Kakiuchi N, Shimotohno K. Inhibitory effects of sudanese medicinal plant extracts on hepatitis C virus (HCV) protease. *Phytother Res*. 2000; 14: 510-516.
- [8] Rasooli I, Fakoor MH, Yadegarinia D, Gachkar L, Alalameh A, Rezaei MB. Antimycotoxigenic characteristics of *Rosmarinus officinalis* and *Trachyspermum copticum* L. essential oils. *Int J Food Microbiol*. 2008; 122: 135-139.
- [9] Dashti-Rahmatabadi MH, Hejazian SH, Morshedi A, Rafati A. The analgesic effect of *Carum copticum* extract and morphine on phasic pain in mice. *J Ethnopharmacol*. 2007; 109: 226-228.
- [10] Bera D, Lahiri D, Nag A. Novel natural antioxidant for stabilization of edible oil: the ajowan (*Carum copticum*) extract case. *Journal of the American Oil Chemists' Society*. 2004; 81: 169-172.
- [11] Peksel A, Arisan-Atac I, Yanardag R. Evaluation of antioxidant and antiacetylcholinesterase activities of the extracts of *Pistacia atlantica* Desf. Leaves. *Journal of food biochemistry*. 2010; 34: 451-476.
- [12] Benhammou N, Bekkara FA, Panovska TK. Antioxidant and antimicrobial activities of the *Pistacia lentiscus* and *Pistacia atlantica* extracts. *African Journal of Pharmacy and Pharmacology*. 2008; 2: 022-028.
- [13] Goswami N, Chatterjee S. Assessment of free radical scavenging potential and oxidative DNA damage preventive activity of *Trachyspermum ammi* L. (carom) and *Foeniculum vulgare* Mill. (fennel) seed extracts. *Biomed Res Int*. 2014; 2014: 582767.
- [14] Janero DR. Malondialdehyde and thiobarbituric acid-reactivity as diagnostic indices of lipid peroxidation and peroxidative tissue injury. *Free Radic Biol Med*. 1990; 9: 515-540.
- [15] Pulli B, Ali M, Forghani R, Schob S, Hsieh KL, Wojtkiewicz G, et al. Measuring myeloperoxidase activity in biological samples. *PLoS One*. 2013; 8: e67976.
- [16] Ghalem BR. Bactericidal activity of *Pistacia atlantica* Desf mastic gum against certain pathogens. *Afr J Plant Sci*. 2009; 3: 13-15.
- [17] Ghalem BR. Essential oil from gum of *Pistacia atlantica* Desf. Screening of antimicrobial activity. *Afr J Pharm Pharmacol*. 2009; 3: 87-91.
- [18] Rhouma A BDH, Ghanmi S, Ben Salah H, Romdhane M, Demak M. Antimicrobial activities of leaf extracts of *Pistacia* and *Schinus* species against some plant pathogenic fungi and bacteria. *J Plant Pathol*. 2009; 91: 339-345.
- [19] Singh I, Singh VP. Antifungal properties of aqueous and organic extracts of seed plants against *Aspergillus flavus* and *A. niger*. *Phytomorphology*. 2000; 20: 151-157.
- [20] Benhassaini H, Bendahmane M, Benchalga N. The chemical composition of fruits of *Pistacia atlantica* Desf. Subsp. *atlantica* from Algeria. *Chemistry of Natural Compounds*. 2007; 43: 121-124.
- [21] Rahimi R, Mozaffari S, Abdollahi M. On the use of herbal medicines in management of inflammatory bowel diseases: a systematic re-view of animal and human studies. *Dig Dis Sci*. 2009; 54: 471-480.
- [22] Yang SK, Loftus EV Jr, Sandborn WJ. Epidemiology of inflammatory bowel disease in Asia. *Inflamm Bowel Dis*. 2001; 7: 260-270.
- [23] Tanideh N, Davarmanesh M, Andisheh-Tadbir A, Ranjbar Z, Mehriar P, Koochi-Hosseiniabadi O. Healing acceleration of oral mucositis induced by 5-fluorouracil with *Pistacia atlantica* (bene) essential oil in hamsters. *J Oral Pathol Med*. 2017; 46: 725-730.
- [24] Farhoosh R, Tavassoli-Kafrani MH, Sharif A. Antioxidant activity of the fractions separated from the unsaponifiable matter of bene hull oil. *Food Chemistry*. 2011; 126: 583-589.



- [25] El-Housseiny AA, SS, El-Masry AA, Allam AA. The effectiveness of vitamin "E" in the treatment of oral mucositis in children receiving chemotherapy. *J Clin Pediatr Dent.* 2007; 31: 167-170.
- [26] Üçüncü H, Ertekin MV, Yörük Ö, Sezen O, Özkan A, Erdoğan F, et al. Vitamin E and L-carnitine, separately or in combination, in the prevention of radiation-induced oral mucositis and myelosuppression: a controlled study in a rat model. *Journal of radiation research.* 2006; 47: 91-102.
- [27] Wadleigh RG, Redman RS, Graham ML, Krasnow SH, Anderson A, Cohen MH. Vitamin E in the treatment of chemotherapy-induced mucositis. *Am J Med.* 1992; 92: 481-484.
- [28] Mutlu-Türkoğlu U, Erbil Y, Oztezcan S, Olgaç V, Toker G, Uysal M. The effect of selenium and/or vitamin E treatments on radiation-induced intestinal injury in rats. *Life Sci.* 2000; 66: 1905-1913.
- [29] Aftab K, Atta-Ur-Rahman, Usmanghani K. pressure lowering action of active principle from *Trachyspermum ammi* (L.) sprague. *Phytomedicine.* 1995; 2: 35-40.
- [30] Khan R, Zakir M, Khanam Z, Shakil S, Khan AU. Novel compound from *Trachyspermum ammi* (Ajowan caraway) seeds with antibiofilm and antiadherence activities against *Streptococcus mutans*: a potential chemotherapeutic agent against dental caries. *J Appl Microbiol.* 2010; 109: 2151-2159.
- [31] Srivastava KC. Extract of a spice--omum (*Trachyspermum ammi*)-shows antiaggregatory effects and alters arachidonic acid metabolism in human platelets. *Prostaglandins Leukot Essent Fatty Acids.* 1988; 33: 1-6.
- [32] Velmurugan C, Geetha C, Shajahan S, Vijayakumar S, Kumar PL. Wound healing potential of leaves of *eucalyptus citriodoralin* rats. *World J Pharm Sci.* 2014; 2: 62-71.
- [33] Choudhary G. Wound healing activity of the ethanol extract of *Terminalia bellirica* Roxb. *Fruits Nat Prod Rad.* 2008; 7:19-21.
- [34] El Ghalbzouri A, Hensbergen P, Gibbs S, Kempenaar J, van der Schors R, Ponc M. Fibroblasts facilitate re-epithelialization in wounded human skin equivalents. *Lab Invest.* 2004; 84: 102-112.