

CASE REPORT

Angelman Syndrome: A Case Report

How to Cite This Article: Ashrafzadeh F, Sadrnabavi A, Akhondian J, Beiraghi Toosi M, Mohammadi MH, Hassanpour K. Angelman Syndrome: A Case Report. *Iran J Child Neurol*. Spring 2016; 10(2):86-89.

Farah ASHRAFZADEH MD¹,
Arianeh SADRABAVI MD²,
Javad AKHONDIAN MD¹,
Mehran BEIRAGHI TOOSI MD¹,
Mohammadhassan MOHAMMADI MD³,
Kazem HASSANPOUR MD³

1. Department of Pediatric Neurology, Ghaem Medical Center, Mashhad University of Medical Sciences, Mashhad, Iran
2. Dept. of Human Genetics, School of Medicine, Mashhad University of Medical Sciences, Mashhad, Iran
3. Department of Pediatric, School of Medicine, Sabzevar University of Medical Sciences, Sabzevar, Iran

Corresponding Author:
Hassanpour K. MD
Ghaem Medical Center, Mashhad University of Medical Sciences, Mashhad, Iran
Email: rahmanish3@mums.ac.ir, drhassanpour@yahoo.com

Received: 3-May-2015
Last Revised: 27-Jul-2015
Accepted: 28-Jul-2015

Abstract

Objective

Angelman syndrome (AS) is a neurodevelopmental disorder presented by jerky movement, speech delay and cognitive disability epilepsy as well as dysmorphic features. It occurs due to an expression deletion in 15q11-q13 chromosome. In this article, we present an eight yr boy referred to Pediatrics Neurologic Clinic Mashhad, Iran for speech delay. He had abnormal behavior ataxia unusual laughing facial expression intellectual disability and mandibular prognathism. Metabolic screening tests and brain MRI were normal. Genetic analysis was pathognomonic for AS.

Keywords: Angelman syndrome; Child; Developmental delay; Iran

Introduction

Angelman syndrome (AS) was first described in 1965 by Harry Angelman (1). He reported 3 children of healthy parents with neurologic syndrome of mental retardation, seizure, facial abnormalities, ataxia, speech disorders and unprovoked laugh pattern. He named them happy puppet. The name of this syndrome changed into AS in 1987 (2). Its genetic base was identified in 1987 (2).

AS is originated from dysfunction in expression of ubiquitin protein ligase E3A (UBE3A) gene in chromosome 15 (3). In 75% of cases a deletion happens in this chromosome, other changes such as translocation, mutation and micro-deletion are seen as well (4). These changes lead to malfunction of neurons. AS incidence is estimated 1 in 15000 live births, and recently nearly 450 cases of AS have been reported (5).

This neurodevelopmental syndrome occurs because of maternally inherited genes. Disease manifestations are language deficit, laughing facial expression, autistic or stereotyped behavior, jerky ataxia and severe mental retardation. Patients have communicative disability with or without seizure (3). These children also have cognitive disorders.

Here we describe a child with AS.

Case report

An 8 yr old boy was referred to Pediatrics Neurologic Clinic Mashhad, Iran; due to developmental delay and seizure attacks from 6 yr ago. He was the second child of non relative healthy parents; there was no evidence of seizure or mental retardation in his family. He was born at term by a vaginal delivery with normal APGAR score

and birth weight. He had a history of neonatal icterus and phototherapy.

He had a happy face and the parents noticed developmental delay at 2 yr old. He was admitted in a hospital because of tonic-clonic seizures and valproate sodium was administered for him. He was able to walk independently at 4 yr old. At the age of 6 yr, he was referred to Children Neurology Department in Mashhad due to hyperactivity, where received risperidone.

On physical examination, he had mandibular prognathism, strabismus and unusual laughing facial expression (Figure1). His head circumference was 51 cm.

Written informed consent was obtained from his parents.

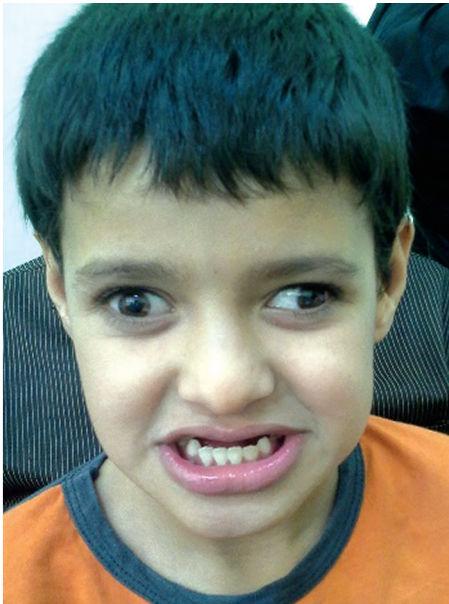

Fig 1: facial expression of Angelman syndrome

His walking was unsteady, but muscles tone, force and deep tendon reflexes were normal. Joints range of motion was normal. Besides, he had speech disability and could walk independently, but could not run. He had restricted communicative abilities and suffered from severe mental retardation.

Laboratory findings were normal. Brain MRI and CBC test were normal. Thyroid function test showed hypothyroidism, controlled by levothyroxine since 2 yr old.

In our patient, seizure attacks have been continued from the age of 2 yr, despite various pharmacologic

treatments.

Genetic findings

After genomic DNA extraction, the DNAs were treated by bisulfide method and methylation specific PCR for the SRNP region were used. Genomic DNA was extracted from leukocytes collected in EDTA tubes (5PRIME kit GmbH, D-22767 Hamburg). The genomic DNA was treated by the Na bisulfite (So₂) (Sigma) method. After treatment the methylation specific PCR was used.

The previously described primers, MAT: 5'-tat tgc ggt aaa taa gta cgt ttg cgc ggt c-3'

PAT: 5'-gtg agt ttg gtg tag agt gga gtg gtt gtt g-3'

COM: 5'-ctc caa aac aaa aaa ctt taa aac cca aat tcc-3' were used to amplify the region.

Genomic treated DNA (300 ng) was used as template in a reaction volume of 23 µL, containing 10.8 µl ddH₂O, 2.5 µl 10X reaction buffer, 25 mM MgCl₂, and 10 mM dNTP, 5mM of each primer and 5U of Taq DNA polymerase (Genet Bio). Cycling conditions were 94 °C for 5 min, followed by 35 cycles of 25 sec at 94 °C, 25 sec at 60 °C and 25 sec at 72 °C, and 5 min at 72 °C as the final extension step. For the positive controlled of methylation test, we used the p16 gene.

For this patient abnormal methylation pattern of the SRNP region (Maternal imprinting defects or deletion) was detected. Therefore, an AS caused by micro deletion, uniparental disomie or imprinting defect (ID) was included. ID defect account for approximately 3% of affected individual. ID have abnormal DNA methylation and 10-20% of the ID are caused by micro deletion (6-200kb) that include the imprinting Center (Figure 2).

Discussion

Many cases of AS have impaired communication, which might occur due to language deficit and mental retardation (9). Our patient had this problem.

Delayed motor development is common in AS, jerky movements are the first manifestation of AS, recognize by parents (10). In our reported case, developmental delayed was identified by parents at the age of 2 yr.

Several facial abnormalities were reported in AS patients such as wide mouth, abnormal teeth, tongue protrusion and mandibular prognathism. There are some evidence

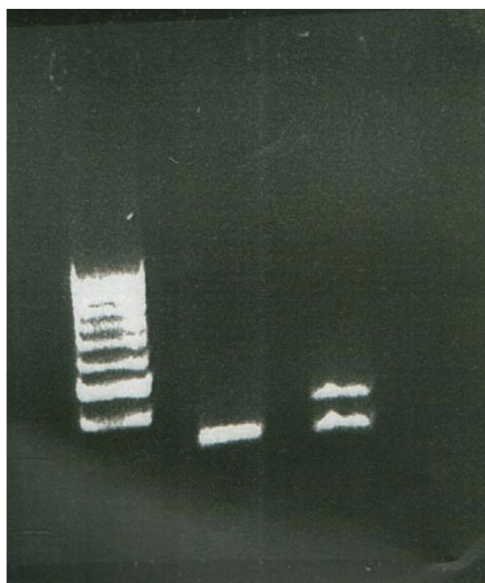


Fig 2: Agarose gel (2.5%) electrophoresis of BST PCR. 100 bp DNA ladder (Fermentas) was used as marker of DNA fragment sizes. Line 1. BST PCR from Engelmann Syndrome Patient. Line 2 BST PCR from Normal Person.

on poor sucking and chewing in infancy (11). Our case had a wide mouth with unusual laughing lips, which is common in AS.

Around 70% of AS children could walk at 3 yr old (12), our caes could walk independently when he was 4 yr, but he still cannot run at 8.

Electroencephalography findings were abnormal in AS patient and EEG showed generalized spike and wave pattern (6). Over 85% of AS patients develop seizure in the first 3 yr of life. Its onset varies from 1 month to 20 years (7). Epilepsy is severe in AS cases and is hard to control as our case. It seems that valproic acid is the therapeutic choice in AS epilepsy (8).

Genetic tests for diagnosing AS are complex analysis. A small proportion of patients with AS may have a small deletion or other mutations that leads to aberrant imprinting of the region (13). These findings have led to major advances in genetic diagnosis of AS. Chromosome 15 deletions usually are submicroscopic but are easily detected by FISH and/or array CGH. Defects in imprinting or uniparental disomy can be identified by studies of patterns of DNA methylation in the region. Failure to identify the methylated or

nonmethylated copy of the sequence is indicative of deletion, uniparental disomy, or a mutation that alters the imprinting mechanism. Genomic imprints are reversible and lead to differential expression in the course of development. Genomic imprinting is an epigenetic process that involves methylation and histone modifications in order to achieve monoallelic gene expression without altering the genetic sequence (14).

In conclusion, all physicians should consider rare syndromes such as AS in children or adults with neurodevelopmental delay. Noting clinical presentation is very important, because clinical suspicions play a crucial role to choose the required laboratory tests. On the other hand, multidiscipline approach is necessary for genetic syndromes like AS because they influence all aspects of patients' life.

Acknowledgements

Authors would like to gratitude to genetic department staff and all the people who provide me with the facilitations for writing this article.

Authors' Contribution

Kazem Hassanpour wrote the draft of the manuscript. Mehran Beiraghi Toosi and Mohammadhassan Mohammadi managed the literature searches. Arianeh Sadrnabavi performed the genetic analyses. Farah Ashrafzadeh designed the figures, managed literature searches and contributed to the correction of the draft. Author CM provided the case, the figures and supervised the work.

All authors agreed to be accountable for all aspects of the work in ensuring that questions related to the accuracy or integrity of any part of the work are appropriately investigated and resolved.

Conflict of Interest

The authors declare that there is no conflict of interests.

References

1. Jolleff N, Ryan MM. Communication development in Angelman's syndrome. *Arch Dis Child* 1993;69(1):148-50.

2. Landsman IS, Mitzel HM, Peters SU, Bichell TJ. Are children with Angelman syndrome at high risk for anesthetic complications? *Paediatr Anaesth* 2012;22(3):263-7. doi: 10.1111/j.1460-9592.2011.03661.x.
3. Bai JL, Qu YJ, Zou LP, Yang XY, Liu LJ, Song F. A novel missense mutation of the ubiquitin protein ligase E3A gene in a patient with Angelman syndrome. *Chin Med J (Engl)* 2011;124(1):84-8.
4. Cobben JM, van Hal A, van den Puttelaar-van Hal N, van Dijk FS. [A girl with Angelman syndrome]. *Ned Tijdschr Geneesk* 2014;158(0):A8092. [In Dutch]
5. Fiumara A, Pittalà A, Cocuzza M, Sorge G. Epilepsy in patients with Angelman syndrome. *Ital J Pediatr* 2010 16;36:31. doi: 10.1186/1824-7288-36-31.
6. Giroud M, Daubail B, Khayat N, Chouchane M, Berger E, Muzard E. Angelman Syndrome: A Case Series Assessing Neurological Issues in Adulthood. *Eur Neurol* 2014 29;73(1-2):119-125. [Epub ahead of print]
7. Larson AM, Shinnick JE, Shaaya EA, Thiele EA, Thibert RL. Angelman syndrome in adulthood. *Am J Med Genet A* 2014 26. doi: 10.1002/ajmg.a.36864. [Epub ahead of print]
8. Lewis MW, Brant JO, Kramer JM, Moss JI, Yang TP, Hansen P. Angelman syndrome imprinting center encodes a transcriptional promoter. *Proc Natl Acad Sci USA* 2014; 5. pii: 201411261. [Epub ahead of print]
9. Mertz LG, Christensen R, Vogel I, Hertz JM, Nielsen KB, Grønskov K. Angelman syndrome in Denmark. Birth incidence, genetic findings, and age at diagnosis. *Am J Med Genet A* 2013;161A(9):2197-203. doi: 10.1002/ajmg.a.36058. Epub 2013 Aug 2.
10. Veiga MF, Toralles MB. [Neurological manifestation and genetic diagnosis of Angelman, Rett and Fragile-X syndromes]. *J Pediatr (Rio J)* 2002;78 Suppl 1:S55-62. [Article in Portuguese]
11. Clayton-Smith J, Laan L. Angelman syndrome: a review of the clinical and genetic aspects. *J Med Genet* 2003;40: 87-95.
12. Thibert RL, Conant KD, Braun EK, Bruno P, Said RR, Nespeca MP, Thiele EA. Epilepsy in Angelman syndrome: a questionnaire-based assessment of the natural history and current treatment options. *Epilepsia* 2009;50(11):2369-76. doi: 10.1111/j.1528-1167.2009.02108.x. Epub 2009 May 12.
13. Buiting K, Saitoh S, Gross S, Dittrich B, Schwartz S, Nicholls RD, Horsthemke B. Inherited microdeletions in the Angelman and Prader-Willi syndromes define an imprinting centre on human chromosome 15. *Nat Genet* 1995;9(4):395-400.
14. Luedi PP, Dietrich FS, Weidman JR, Bosko JM, Jirtle RL, Hartemink A. Computational and experimental identification of novel human imprinted genes. *Genome Res* 2007;17:1723-1730.