



Coronary Artery Fistula from Left Circumflex to Coronary

Saeed Davoodi, MD^{1,2*}, Yaddollah Dadashi, MD¹, Manouchehr Madani Civi, MD¹
Seyed Hesameddin Abbasi, MD^{1,2}, Amir Hossien Sami, MD¹, Kyomars Majdi, MD¹

¹ National Iranian Oil Company Central Hospital, Tehran, Iran.

² Tehran Heart Center, Medical Sciences/University of Tehran, Tehran, Iran.

Received 25 June 2007; Accepted 15 September 2007

Abstract

In this paper, we describe a case of an aneurysmal circumflex artery connected to the coronary sinus through a fistula in a 40-year-old man with a two-year history of palpitation and chest pain. We discussed surgical management for patients with coronary artery fistula (CAF), particularly for asymptomatic patients with a small left-to-right shunt.

J Teh Univ Heart Ctr 4 (2007) 43-45

Keywords: Coronary sinus • Fistula • Coronary vessel anomalies

Introduction

A coronary artery fistula (CAF) is a rare congenital anomaly with a reported incidence of 0.1% to 0.2% in the adult population referred for cardiac catheterization.¹ A fistulous connection into a cardiac chamber or major vessel often causes a marked dilation of the donor coronary artery leading to aneurysm formation.²

Among various coronary artery anomalies, the fistulous connection of the aneurysmal circumflex coronary artery to the coronary sinus has been previously reported as an extremely uncommon form.³⁻⁸

Case report

A 40-year-old man with a two-year history of palpitation and chest pain referred to us. He had no history of myocardial infarction, CCU admission, and smoking. Chest X-rays showed no cardiomegaly or pulmonary congestion. Electrocardiography showed normal sinus rhythm and no specific changes in the ST segment and T wave. But an exertion tolerance test was positive after 8 minutes with ST-segment changes. Transesophageal echocardiography confirmed a huge and tortuous left circumflex coronary artery (LCX) with a detectable flow pattern. There was a large-

*Corresponding Author: Saeed Davoodi, Cardiac Surgery Ward, National Iranian Oil Company Central Hospital, Hafez Avenue, Tehran, Iran. Tel: +98 21 66706520. Fax: +98 21 66704011. Email: sdavoodi@yahoo.com.

sized LMA (9.4 mm), but there was no obvious evidence of an abnormal LCX drainage.

Coronary angiography revealed normal right coronary and left anterior descending arteries. The markedly dilated and tortuous LCX, which was aneurysmal and connected to the coronary sinus through a fistula, was delineated. On C.T. coronary angiography, LCX was patent, ectatic with the fistula to the coronary sinus (Fig. 1).

Based on these findings, a diagnosis of CAF from LCX to the coronary sinus was made and the surgical closure of the CAF with cardiopulmonary bypass (CPB) was recommended.

of cases and drained into the pulmonary artery in 17% of cases.^{9,10}

Clinically ,patients with coronary fistulae may present with palpitations or with symptoms of angina ,heart failure ,or bacterial endocarditis ;or they may be totally asymptomatic. Two-dimensional echocardiography is important in the diagnosis of fistulae ,and transesophageal echocardiography is superior to transthoracic echocardiography in delineating their characteristics¹¹.

Definitive diagnosis and planning for treatment can be done with the aid of cardiac catheterization.^{12,13} There has been general consensus that all symptomatic patients with

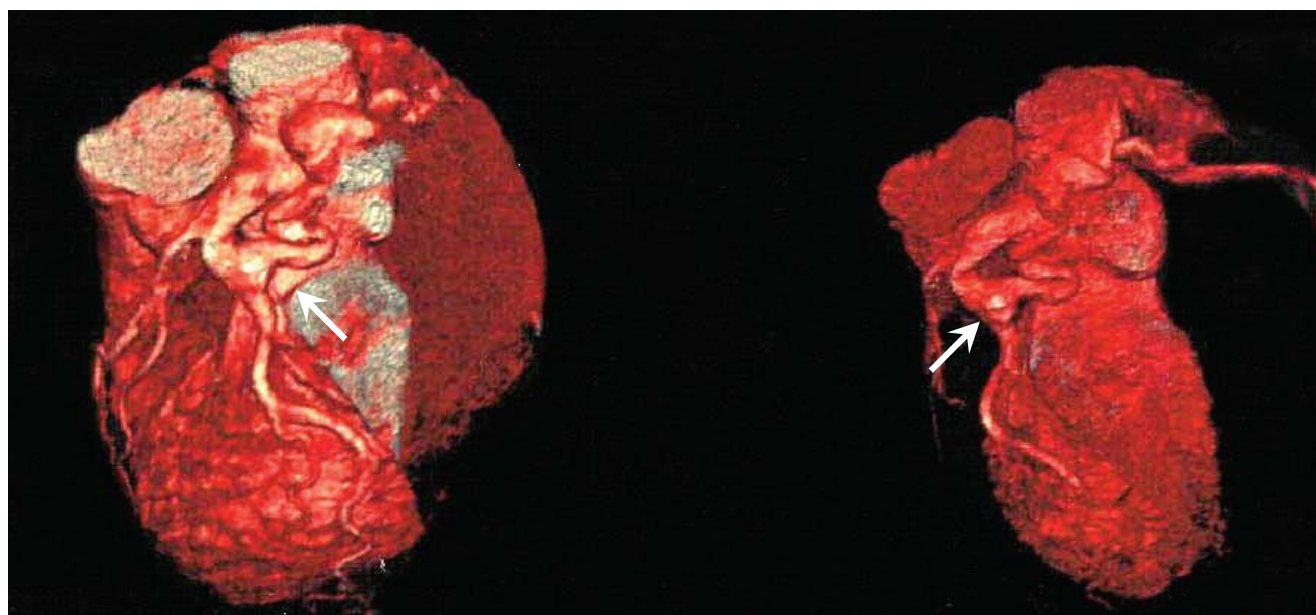


Figure 1. Preoperative CT coronary angiography showed that left circumflex coronary artery was dilated, ectatic with the fistula to the coronary sinus (arrows)

Discussion

This case demonstrates a very rare pathology of an aneurysmal circumflex coronary artery connected to the coronary sinus through a fistula .CAF is the most common coronary arterial malformation but is a rare cardiac anomaly. Similarly ,a coronary artery aneurysm is also a rare form of coronary artery disease ,and is characterized by an abnormal dilatation to a diameter of more than 1.5 fold that of the adjacent normal coronary artery.⁵

In the general population, coronary artery abnormalities occur in 1% to 2% of people. They are classified into 3 categories: abnormalities of origin, distribution, and termination. CAF, considered to be a termination abnormality,⁹ is uncommon and is seen in only 0.1% to 0.2% of coronary angiograms. In the majority of reported cases, coronary fistulae were found to originate from the right coronary artery (52% of cases) and to drain into the right ventricle (40% of cases); and fistulae were found to originate from the circumflex artery in 18%

coronary fistulae should undergo closure of the fistulae as soon as the diagnosis is made given the increased morbidity and mortality associated with delay.

Our patient presented with chest pain, and the discovery of the fistula was purely incidental during our 2-dimensional echocardiographic investigation. Confirmation was made by cardiac catheterization and transesophageal echocardiography. We believe that most of our patient's symptoms were caused by steal of blood along the circumflex artery, in spite of the large fistulous tract seen during cardiac catheterization.

Closure of congenital fistulae can be managed by either operative or nonoperative techniques. Nonoperative closure has been accomplished by transcatheter embolization of detachable balloons, platinum microcoils, and steel coils.^{12,13}

Surgical ligation of the fistula should be done at its entrance within the recipient cavity ,whether that cavity is a cardiac chamber or a vessel .It is generally agreed that bypass



is indicated when the fistula is relatively inaccessible) such as in the distribution of the circumflex or distal right coronary artery, (when the fistula is in the course of the coronary artery rather than at its termination, and when an aneurysm requires excision.^{12,14}

As a result of our findings, we decided to perform surgery using CPB. We believe that congenital coronary fistulae can be corrected easily with surgery, especially when they are associated with concomitant disease affecting other vessels. This should be done using CPB because it confers excellent results with no apparent mortality or morbidity.

References

1. Vavuranakis M, Bush CA, Boudoulas H. Coronary artery fistulas in adults; incidence, angiographic characteristics, natural history. *Cathet Cardiovasc Diagn* 1995;35:116-120.
2. Said SA, Gamal MI. Coronary angiographic morphology of congenital coronary arteriovenous fistulas in adults: report of four new cases and review of angiograms of fifteen reported cases. *Cathet Cardiovasc Diagn* 1995;35:29-35.
3. Keane JF, Baim DS, Lock JE. Transcatheter closure of coronary artery fistulas. *J Am Coll Cardiol* 1992;20:205-209.
4. Rajs J, Brodin LA, Hertzfeld I, Larsen FF. Death related to coronary artery fistula after rupture of an aneurysm to the coronary sinus. *Am J Forensic Med Pathol* 2001;22:58-61.
5. Chamberlain MH, Henry R, Brann S, Angelini GD. Surgical management of a gigantic circumflex coronary artery aneurysm with fistulous connection to the coronary sinus. *Eur J Cardiothorac Surg* 2001;20:1255-1257.
6. Dogan A, Ozaydin M, Altinbas A, Gedikli O. A giant aneurysm of the circumflex coronary artery with fistulous connection to the coronary sinus: a case report. *Int J Cardiovasc Imaging* 2003;19:5-8.
7. Phillips WS, Cooley DA. Successful repair of a massive coronary arteriovenous fistula in a 68-year-old man. *Ann Thorac Surg* 1996;61:984-986.
8. Kasravi B, Reid CL, Allen BJ. Coronary artery fistula presenting as bacterial endocarditis. *J Am Soc Echocardiogr* 2004;17:1315-1316.
9. Fernandes ED, Kadivar H, Hallman GL, Reul GJ, Ott D, Cooley DA. Congenital malformations of the coronary arteries: the Texas Heart Institute experience. *Ann Thorac Surg* 1992;54:732-740.
10. Athanasias DA, Van Ommen V, Bar F. Coronary artery-pulmonary artery fistula originating from the left anterior descending artery: a case report and literature review. *Hellenic J Cardiol* 2002;43:78-81.
11. Prewitt KC, Smolin MR, Coster TS, Vernalis MN, Bunda M, Wortham DC. Coronary artery fistula diagnosed by transesophageal echocardiography. *Chest* 1994;105:959-961.
12. Kirklin JW, Barratt-Boyes BG. Congenital anomalies of the coronary arteries. In: Kirklin JW, Barratt-Boyes BG, eds. *Cardiac surgery: morphology, diagnostic criteria, natural history, techniques, results, and indications*. 3rd ed. New York: Churchill-Livingstone; 2003. p. 1240-1264.
13. Glenn WW, Baue A. Anomalies of the coronary vessels. In: Glenn WW, Baue A. *Glenn's thoracic and cardiovascular surgery*. Vol 3. 6th ed. Stamford (CT): Appleton & Lange; 1996. p. 1521-1531.
14. Krishnamoorthy KM, Rao S. Saccular aneurysm of congenital coronary arteriovenous fistula. *Interact Cardiovasc Thorac Surg* 2003;2:295-297.