

Evaluation of Exercise-Induced Hypertension Post Endovascular Stenting of Coarctation of Aorta

Hojat Mortazaeian, MD, Mohammad Yoosef Aarabi Moghadam, MD, Mehdi Ghaderian, MD*, Paridokht Nakhostin Davary, MD, Mohmood Meraji, MD, Akbar Shah Mohammadi, MD

Shaheed Rajaei Cardiovascular Medical and Research Center, Iran University of Medical Sciences, Tehran, Iran.

Received 21 February 2010; Accepted 10 May 2010

Abstract

Background: Coarctation of the aorta (COA) is a defect that accounts for 5-8% of all congenital heart diseases. Balloon angioplasty as a treatment for COA is increasingly performed, with endovascular stents having been proposed as a means of improving the efficacy and safety of the procedure. The aim of this study was to evaluate the systolic blood pressure gradient at rest and during maximal exercise at follow-up in patients post endovascular stenting of COA.

Methods: Thirteen patients (4 native and 9 re-coarctation cases of COA after surgery or balloon angioplasty) with a mean age of 11.1 ± 4.7 years underwent endovascular stenting between November 2007 and December 2009 via standard techniques for native COA as an alternative to surgical repair. Doppler echocardiography was performed pre and post stenting. Resting and exercise assessment of blood pressure was performed at follow-up.

Results: Post stent implantation, no angiographic major complications were evident. Systolic blood pressure gradient decreased from 42 ± 8.8 mm Hg before stent placement to 7 ± 10 mm Hg at follow-up (p value < 0.001). Peak Doppler pressure gradient decreased from 30 ± 14 mm Hg to 14 ± 10 mm Hg at follow-up (p value < 0.007). One case of exercise-induced hypertension was seen in patients.

Conclusion: Endovascular stenting for native COA in older children and post-surgical COA repair in patients with residual COA and re-coarctation is a reasonable alternative to surgical correction. During early follow-up, stenting effectively alleviates the aortic arch obstruction with normalization of the systemic blood pressure both at rest and during maximal exercise.

J Teh Univ Heart Ctr 3 (2010) 137-140

Keywords: Heart defects, congenital • Aortic coarctation • Stents • Hypertension

Introduction

Coarctation of the aorta (COA) is a defect that accounts for 5-8% of all congenital heart diseases and may occur as in isolation or in association with other diseases, most commonly bicuspid aortic valve and ventricular septal defect. The diagnosis of COA may be missed unless an index of

suspicion is maintained and is often delayed until the patient has developed congestive heart failure, which is common in infants, or hypertension, which is common in adults. Two types of COA have been described in the literature: preductal (or infantile) and postductal (or adult), depending on whether the coarctation segment is proximal or distal to the ductus arteriosus, respectively.

*Corresponding Author: Mehdi Ghaderian, Shaheed Rajaei Cardiovascular Medical and Research Center, Vali-Asr Ave, Adjacent to Mellat Park. 1996911151. Tehran, Iran. Tel: +98 21 23922524. Fax: +98 21 22055594. E-mail: ghader_45@yahoo.com.

Balloon angioplasty is widely accepted to be the treatment of choice for re-coarctation after previous surgical repair in as much as its morbidity is lower and its success rate is higher in comparison with repeat surgery.¹ Native coarctation is also successfully treated with balloon dilation, but it is generally avoided in the first 6 to 12 months of life.² For all the merits of the balloon angioplasty of COA, however, there are such complications as the tearing of the aortic intima, formation of aneurysms, and restenosis.

Balloon-expandable endovascular stents have been used with desirable outcome in the treatment of stenotic large vessels in various locations in humans.³⁻⁹ Stent placement at the time of balloon dilation could prevent restenosis and could also prevent the progression of aneurysms formation; the use of these stents in COA can, therefore, be an alternative to surgery or balloon angioplasty. Initially, stent implantation was used only for cases where surgery and balloon angioplasty had failed.⁷ Nevertheless, increase in collective experience has gradually led to stenting becoming the treatment of choice in COA,¹⁰ so much so that stenting is now regarded as the treatment of choice in any variant of COA in adult patients.¹⁰ Be that as it may, in children less than 10 years of age, it is preferable to avoid stenting because several redilations may be required until the child is fully grown.¹⁰ It is also deserving of note that patients with COA are prone to develop arterial hypertension at various stages throughout life.¹⁰⁻¹³

The aim of this study was to evaluate the systolic blood pressure gradient at rest and during maximal exercise at follow-up in patients post endovascular stenting of COA.

Methods

Thirteen patients with COA (4 native and 9 re-coarctation cases after surgery or balloon angioplasty) between the ages of 5 and 20 (mean: 11.8 ± 4.7 years) underwent successful transcatheter intervention of COA between November 2007 and December 2009. All of the procedures were performed under deep sedation, and endovascular stenting was performed via a retrograde femoral artery approach and standard catheterization technique. Anticoagulation with heparin (50-100 U/kg, to a maximum 5000 U) was maintained throughout the procedure. A long trans-septal sheath was advanced over a guide wire across the coarctation site so as to position the tip of the wire in the left ventricle. Coarctation of the aorta was defined as systolic arm-to-leg blood pressure gradient ≥ 20 mm Hg or echocardiographic or angiographic evidence of COA. Successful outcome was defined as peak systolic pressure gradient after stent implantation < 20 mm Hg. The patients were placed on antiplatelet therapy with ASA or Clopidogrel for three to six months after the procedure unless they were already on anticoagulation for other reasons. Follow-up duration was 10 ± 3 months (1-24 months).

Follow-up comprised cardiological examination with special attention to blood pressure, systolic blood pressure gradient, echocardiogram, and exercise test. Statistical significance was evaluated utilizing the paired t-test for paired data. A p value < 0.05 was considered statistically significant. The interval data are expressed as mean \pm standard deviation. All the data analyses were conducted using SPSS version 15.0.

Results

The stents were implanted in the stenotic area in all the patients (Figure 1 & 2). Nine Patients had re-coarctation after previous surgical repair. Thirteen patients underwent the placement of 14 stents; two stents were placed for one patient. Two patients underwent repeat catheterization and stent redilation 16 and 21 months after the initial implantation. CP (NU MED inc., Nicholville, New York) and Genesis (Cordis Corp., Miami, FL, USA) stents were utilized in our patients. The balloons used had a mean diameter of 15 mm (range: 12 to 16 mm). There were no immediate complications during stent implantation and need for emergency surgery. Post stent implantation, no angiographic complications such as retroperitoneal hematoma secondary to bleeding from the external iliac artery, arterial dissection, aneurism formation, stents fracture, stents migration, and arteriovenous fistulas were evident by repeat echocardiography, catheterization, or CT-angiography. There were no deaths related to the procedure. The systolic blood pressure gradient decreased from 42 ± 8.8 mm Hg before stent placement to 7 ± 10 mm Hg at follow-up (p value < 0.001).

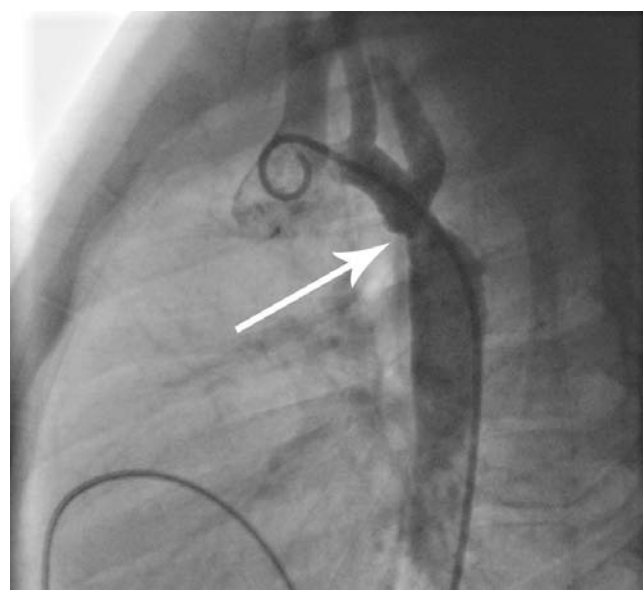


Figure 1. Initial implantation of the stent in a 7-year-old patient with re-coarctation of the aorta and mild hypoplasia transverse aortic arch with a previous history of coarctation of the aorta (COA) repair. Initial lateral angiography showed COA with a 40 mm Hg pressure gradient (arrow)



The echocardiographically predicted peak instantaneous pressure gradient across the coarctation site was 31 ± 14 mm Hg with continuous diastolic run-off in all the patients. The peak Doppler pressure gradient decreased by 14 ± 10 mm Hg at follow-up (p value < 0.001). At follow-up, all the patients underwent exercise treadmill stress testing using the modified Bruce protocol, and exercise-induced hypertension was demonstrated in one patient, who subsequently underwent CT-angiography and was referred for stent redilation. Before stenting, all the patients received antihypertensive medications. The mean of blood pressure was 136 ± 21 mm Hg before stent implantation and 115 ± 15 mm Hg at follow-up. After stenting, all 13 patients had continued antihypertensive medications consisting of Captopril. Twelve patients were weaned off antihypertensive medications with the final resting normal blood pressure and right arm-leg blood pressure gradient measuring 10 mm Hg (p value < 0.001). Only one patient continued his antihypertensive medications.

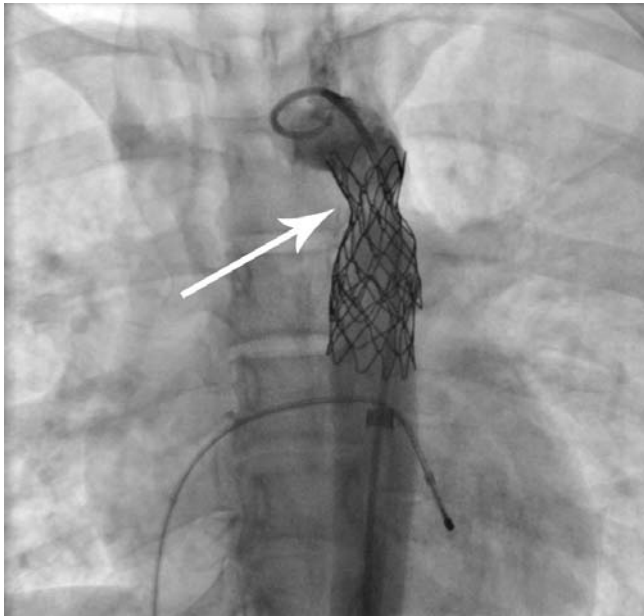


Figure 2. After implantation of the stent, the diameter of aorta increased (arrow) and the pressure gradient across the coarctation decreased to 0 mm Hg

Discussion

Balloon-expandable endovascular stents have been used in various locations as an alternative to surgery.^{3-9, 13-19} Stents provide a homogenous framework for smooth endothelial growth along the aortic wall that reduces the risk of thrombosis, neointimal hyperplasia, and subsequent restenosis.¹⁷ The theoretical advantage of stenting is to create a uniform appearance of the coarctation region and protect against aneurysm formation.¹⁹ Stents support the integrity of the vessel wall after balloon dilation by opposing the recoil

of the elastic vascular stenosis and reapplying the torn intima to the media.¹⁷⁻¹⁹ This minimizes the extension of wall tears and subsequent dissection or aneurysm formation that could occur after balloon angiography alone. The literature shows that despite a successful surgical correction of COA (normal resting blood pressure and an aortic arch gradient < 20 mm Hg), a subset of patients will develop exercise-induced systolic hypertension and a significant arm to leg blood pressure gradient.²⁰⁻²³ This is felt to be secondary to either abnormal aortic arch growth proximal to the coarctation repair or abnormal arterial compliance. Conversely, the presence of a rigid stent within the aorta may also lead to impaired elasticity and distensibility of the aortic wall and, therefore, result in exercise-induced hypertension.¹⁹ Anywhere from 15% to 40% of patients continued to demonstrate exercise-induced hypertension at intermediate follow-up.¹⁹ Bulbuz et al. demonstrated that the stenting of COA in older patients could not lead to the normalization of blood pressure at short-time follow-up.⁵ Srinath et al. reported that there was no change in the number of patients who still required antihypertensive medications post intervention. Weber and Cyran showed that successful endovascular stenting of native COA in younger patients led to the normalization of resting and exercise-related systemic blood pressure. In the Srinath report, the patient population was significantly older than that of the Weber report (median 17-21 years vs. 7-13 years). Our results demonstrated that successful endovascular stenting of COA in younger patients led to the normalization of resting and exercise-related systemic blood pressure, systolic pressure gradient, and being taken off antihypertensive medications within a short period of time. Ebeid et al. stated that one patient required stenting redilation because of an exercise-induced gradient.⁹ One patient in our study population underwent successful stent redilation because of an exercise-induced gradient. Doppler studies across the stenting sites continue to demonstrate an elevated peak instantaneous velocity at rest and after exercise. Doppler velocity was lower than the pre-intervention values and without diastolic run-off. These findings suggest that although there may be an element of diminished arterial compliance post stenting, the decrease in compliance is not clinically relevant. Our data suggest that repeat assessment of blood pressure and exercise test can lead to need for future intervention or medical therapy.

The use of stents in COA remains limited to older children and adults because of the large delivery systems required and multiple dilations. A limitation of our study is its small size.

Conclusion

Endovascular stent implantation is now increasingly used in place of balloon dilation for both native coarctation and re-coarctation in older children and adults as an acceptable

alternative to surgical correction. Effective relief of the aortic arch obstruction and normalization of the systemic blood pressure at rest were supported by our study. Some patients may require further stent dilation in the future following a significant increase in growth. Continued follow-up in order to assess long-term blood pressure control is warranted.

Acknowledgment

We wish to thank Dr. Bakhshandeh for statistical consultation. Thanks are also due to Miss A. Shakery, Mrs. N. Alaei, and Mrs. Z. Akbarzade for their excellent cooperation. This study was supported by Iran University of Medical Sciences.

References

- Hellenbrand WE, Allen HD, Golinko RJ, Hagler DJ, Lutin W, Kan J. Balloon angioplasty for aortic recoarctation: results of the valvuloplasty and angioplasty of congenital anomalies registry. *Am J Cardiol* 1990;65:793-797.
- Redington AN, Booth P, Shore DF, Rigby ML. Primary balloon dilatation of coarctation of the aorta in neonates. *Br Heart J* 1990;64:277-281.
- Suárez de Lezo J, Pan M, Romero M, Medina A, Segura J, Pavlovic D, Martinez C, Tejero I, Perez Navero J, Torres F. Balloon-expandable stent repair of severe coarctation of the aorta. *Am Heart J* 1995;129:1002-1008.
- O'Laughlin MP, Slack MC, Grifka RG, Perry SB, Lock JE, Mullins CE. Implantation and intermediate-term follow-up of stents in congenital heart disease. *Circulation* 1993;88:605-614.
- Bulbul ZR, Bruckheimer E, Love JC, Fahey JT, Hellenbrand WE. Implantation of balloon-expandable stents for coarctation of the aorta: implantation data and short-term results. *Cathet Cardiovasc Diagn* 1996;39:36-42.
- Thanopoulos BV, Triposkiadis F, Margetakis A, Mullins CE. Long segment coarctation of the thoracic aorta: treatment with multiple balloon-expandable stent implantation. *Am Heart J* 1997;133:470-473.
- Rosenthal E, Qureshi SA, Tynan M. Stent implantation for aortic re-coarctation. *Am Heart J* 1995;129:1220-1221.
- Suárez de Lezo J, Pan M, Romero M, Medina A, Segura J, Lafuente M, Pavlovic D, Hernández E, Melián F, Espada J. Immediate and follow-up findings after stent treatment for severe coarctation of aorta. *Am J Cardiol* 1999;83:400-406.
- Ebeid MR, Prieto LR, Latson LA. Use of balloon-expandable stents for coarctation of the aorta: initial results and intermediate-term follow-up. *J Am Coll Cardiol* 1997;30:1847-1852.
- Qureshi SA. Stenting in aortic coarctation and transverse arch/isthmus hypoplasia. In: Sievert H, Qureshi SA, Wilson N, Hijazi ZM, eds. *Percutaneous Interventions for Congenital Heart Disease*. London: Informa Healthcare; 2007. p. 475-486.
- Musto C, Cifarelli A, Pucci E, Paladini S, De Felice F, Fiorilli R, Violini R. Endovascular treatment of aortic coarctation: long-term effects on hypertension. *Int J Cardiol* 2008;130:420-425.
- Shaddy RE, Boucek MM, Sturtevant JE, Ruttenberg HD, Jaffe RB, Tani LY, Judd VE, Veasy LG, McGough EC, Orsmond GS. Comparison of angioplasty and surgery for unoperated coarctation of the aorta. *Circulation* 1993;87:793-799.
- Rao PS, Thapar MK, Kutayli F, Carey P. Causes of re-coarctation after balloon angioplasty of unoperated aortic coarctation. *J Am Coll Cardiol* 1989;13:109-115.
- Ray DG, Subramanyan R, Titus T, Tharakan J, Joy J, Venkitachalam CG, Balakrishnan KG. Balloon angioplasty for native coarctation of the aorta in children and adults: factors determining the outcome. *Int J Cardiol* 1992;36:273-281.
- Ovaert C, Benson LN, Nykanen D, Freedom RM. Transcatheter treatment of coarctation of the aorta: a review. *Pediatr Cardiol* 1998;19:27-44.
- Morrow WR, Smith VC, Ehler WJ, VanDellen AF, Mullins CE. Balloon angioplasty with stent implantation in experimental coarctation of the aorta. *Circulation* 1994;89:2677-2683.
- Fletcher SE, Cheatham JP, Froeming S. Aortic aneurysm following primary balloon angioplasty and secondary endovascular stent placement in the treatment of native coarctation of the aorta. *Cathet Cardiovasc Diagn* 1998;44:40-44.
- Hamdan MA, Maheshwari S, Fahey JT, Hellenbrand WE. Endovascular stents for coarctation of the aorta: initial results and intermediate-term follow-up. *J Am Coll Cardiol* 2001;38:1518-1523.
- Rosenthal E. Stent implantation for aortic coarctation: the treatment of choice in adults? *J Am Coll Cardiol* 200;38:1524-1527.
- Weber HS, Cyran SE. Endovascular stenting for native coarctation of the aorta is an effective alternative to surgical intervention in older children. *Congenit Heart Dis* 2008;3:54-59.
- Weber HS, Cyran SE, Grzeszczak M, Myers JL, Gleason MM, Baylen BG. Discrepancies in aortic growth explain aortic arch gradients during exercise. *J Am Coll Cardiol* 1993;21:1002-1007.
- Markham LW, Knecht SK, Daniels SR, Mays WA, Khoury PR, Knilans TK. Development of exercise-induced arm-leg blood pressure gradient and abnormal arterial compliance in patients with repaired coarctation of the aorta. *Am J Cardiol* 2004;94:1200-1202.
- Cyran SE, Grzeszczak M, Kaufman K, Weber HS, Myers JL, Gleason MM, Baylen BG. Aortic "recoarctation" at rest versus at exercise in children as evaluated by stress Doppler echocardiography after a "good" operative result. *Am J Cardiol* 1993;71:963-970.