

Balloon Angioplasty versus Surgical Repair of Coarctation of Aorta in Infants

Fariba Alaei, MD*, Mohammad Yousef Arabi Moghadam, MD, Hojat Mortaezaian, MD, Mastaneh Alaei, MD, Hooman Bakhshandeh, MD

Shaheed Rajaei Cardiovascular, Medical and Research Center, Tehran, Iran.

Received 09 November 2010; Accepted 17 May 2011

Abstract

Background: Coarctation of the aorta is a discrete stenosis of the proximal thoracic aorta. The common clinical pattern is congestive heart failure in infancy. Treatment methods include balloon angioplasty and surgical repair in this age group. Percutaneous balloon angioplasty is a less invasive method for the repair of discrete coarctation but remains controversial as a primary treatment strategy for a native coarctation. This study aimed to compare the effectiveness and outcome of balloon angioplasty and surgical repair in coarctation infants younger than 1 year old.

Methods: This retrospective study evaluated the results of the two methods in 167 patients younger than one year old admitted into a tertiary heart center pediatric ward with the diagnosis of coarctation of the aorta: Balloon angioplasty was done for 55 and surgical repair for 112 infants. Patients with previous interventions were not included in this study.

Results: Primary results revealed no significant difference in the effectiveness of the two methods (p value = 0.0601). While the rate of recurrent coarctation was significantly lower in the surgery group [19 (17%) vs. 11 (20%), p value = 0.0470], the mortality rate was lower in the balloon angioplasty method [5 (5.5%) vs. 13 (11.6%), p value = 0.039]. Our multivariate logistic regression model, however, showed no statistically significant difference (p value = 0.120).

Conclusion: Because of the incidence of re-coarctation, balloon angioplasty compared with surgical repair did not confer an improved outcome for our infants' coarctation.

J Teh Univ Heart Ctr 2011;6(3):134-137

This paper should be cited as: Alaei F, Arabi Moghadam MY, Mortaezaian H, Alaei M, Bakhshandeh H. Balloon Angioplasty versus Surgical Repair of Coarctation of Aorta in Infants. *J Teh Univ Heart Ctr 2011;6(3):134-137.*

Keywords: Aortic coarctation • Angioplasty, Balloon • Surgical procedure • Treatment outcome

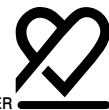Introduction

Coarctation of the aorta occurs in 6 to 8% of patients with congenital heart disease, with males being more frequently affected than females. This condition is commonly associated with intracardiac pathology. Complex coarctation is much more likely in infants than in older children. Coarctation in infancy is usually a catastrophic illness and is associated

with congestive heart failure, demanding immediate and aggressive treatment because of its poor natural history.¹

There is a wide divergence of opinion on the efficacy of balloon angioplasty for the treatment of coarctation of the aorta. Some experts consider balloon angioplasty a treatment option,²⁻⁵ not least in older infants,^{3,4} and whereas some deem balloon angioplasty an acceptable alternative for surgical repair,^{6,7} others prefer this procedure as a palliative option.⁸

*Corresponding Author: Fariba Alaei, Pediatric Cardiologist, Shaheed Rajaei Cardiovascular, Medical and Research Center, Tehran, Iran. 1996911151. Tel: + 98 21 22663212. Fax: +98 21 22663212. E-mail: alaeifariba@yahoo.com.



Complex coarctation with congestive heart failure in infants carries high surgical risk. Angioplasty is not widely accepted because of the possibility of residual or recurrent stenosis and aneurysm formation at the dilation site. Residual or recurrent coarctation occurs most commonly after repair in infancy, regardless of whether primary treatment is surgery or balloon angioplasty.¹ There is a dearth of relevant information in this age group in Iran; we, therefore, sought to compare the effectiveness of balloon angioplasty and surgical repair in infants with coarctation.

Methods

This observational study recruited 167 infants with coarctation of the aorta admitted into our tertiary heart center pediatric ward between April 2006 and August 2009. All of these patients were younger than 1 year old with a diagnosis of coarctation of the aorta, with or without co-associated lesions. Patients with a previous history of any intervention or those older than 1 year were excluded from our study. Balloon angioplasty was performed on 55 patients and surgical repair on 112 patients; the choice was made according to the pediatric cardiology interventionist's discretion and the associated heart lesions.

Balloon dilatation of the coarctation was performed using the standard retrograde femoral arterial approach in all the patients. The balloon devices utilized were Tyshak-2 (Numed Company), miniTyshak (Numed Company), Ever Cross (ev3 Company), and Optapro (Cordis Company). The balloon diameter was selected to be not two times greater than the diameter of the stenotic area at the coarctation site and not to exceed the diameter of the aorta at the level of the diaphragm. The length of the balloon was 2-3 cm. The balloon was inflated one to three times to the pressure level recommended by the manufacturer until relief of waist was seen. Balloon angioplasty was considered successful when the waist disappeared and the post-procedure pressure gradient reached ≤ 20 mmHg.

The peak pressure gradient was measured via transthoracic echocardiography using Vivid 3 General Electric system before and after the procedure. Additionally, alongside periodic clinical evaluations, echocardiographic Doppler-derived peak pressure gradients were obtained for all the patients initially on the first post-procedural day and thereafter at the 6th, 12th, 18th, and 24th post-procedural months routinely.

The data are presented as mean \pm standard deviation for the interval variables and frequency (%) for the categorical variables. The Student t-test, Pearson chi-square, or Fisher exact tests were used to compare the results between the study groups. Multiple linear and logistic regression models were applied to investigate the adjusted associations between the variables. The adjustment of the confounders and

comparisons of the changes in the peak pressure gradients at different follow-ups between the study groups were done using repeated measurement analysis of variance (ANOVA) models. A p value less than 0.05 was considered significant. The statistical analyses were conducted by SPSS 15 for Windows (SPSS Inc., Chicago, Illinois).

Results

A total of 167 children were recruited. The female/male ratio was 58/109, and the mean age \pm standard deviation was 139 ± 91.7 days (range = 22 to 365 days). The patients' mean weight was 5.4 ± 5.3 kg, mean height was 59.3 ± 7.8 cm, and hospital stay was 19 ± 17.8 days.

The patients' baseline characteristics in the surgery and angioplasty groups were compared and the results are presented in Table 1. Because of the differences in the children's clinical conditions and relative severity of the underlying diseases in the surgery group, the prevalence of the congenital anomalies was different between the study groups (p values < 0.05). On the other hand, cardiomyopathy was more prevalent in the angioplasty group (p value = 0.008).

Table 1. Patients' characteristics*

	Study Groups		p value
	Balloon angioplasty (n=55)	Surgery (n=112)	
Age (day)	153.0 \pm 95.6	132.0 \pm 89.4	0.171
Female/Male	17/42	38/70	0.402
Height (cm)	60.5 \pm 10.5	58.7 \pm 6.1	0.249
Weight (kg)	6.8 \pm 9	4.7 \pm 1.3	0.097
PPG (mmHg)	55.0 \pm 18.5	57.0 \pm 29.9	0.566
Congenital Anomalies			
MS	5 (9.1)	10 (8.9)	0.972
AS	10 (18.2)	8 (7.1)	0.031
PDA	23 (41.8)	99 (88.4)	< 0.001
ASD	7 (12.7)	28 (25.0)	0.067
VSD	15 (27.3)	62 (55.4)	0.001
TGA	0	13 (11.6)	0.004
CMP	14 (25.5)	11 (9.8)	0.008

*Data are presented as mean \pm SD or n (%)

PPG, Peak pressure gradient; MS, Mitral stenosis; AS, Aortic stenosis; PDA, Patent ductus arteriosus; ASD, Atrial septal defect; VSD, Ventricular septal defect; TGA, Transposition of great arteries; CMP, Cardiomyopathy

The comparisons of the study outcomes are presented in Table 2. The mean hospital stay was 6.5 ± 4.6 days in the balloon angioplasty group and 25.5 ± 18.6 days in the surgery group, which constitutes a significant statistical difference (p value < 0.001). After the potential confounders such as the underlying diseases and weight were adjusted,

the association between the type of intervention and hospital stay remained significant (p value < 0.001).

Table 2. Comparison of the study outcomes between the study groups*

	Study Groups		p value
	Balloon angioplasty (n=55)	Surgery (n=112)	
Hospital Stay (day)	6.5±4.6	25.5±18.6	< 0.001
PPG (mmHg)			
Immediately after procedure	28.9±11.1	25.4±12.1	0.601
After 6 months	34.5±14.1	27.6±16.0	< 0.001
After 12 months	34.6±18.7	25.7±16.0	0.004
Re-do Procedure	9 (16.4)	7 (6.3)	0.213
Re-Coarctation (1 st year)	11 (20)	19 (17)	0.047
Death	5 (5.5)	13 (11.6)	0.039

*Data are presented as mean±SD or n (%)

PPG, Peak pressure gradient

The peak pressure gradients across the coarctation sites, obtained before and immediately after angioplasty and during a twelve-month follow-up period, are shown in figure 1. The peak pressure gradient decreased from 55.0 ± 18.5 to 28.9 ± 11.1 mmHg in the balloon angioplasty group and from 57 ± 29.9 to 25.4 ± 12.1 mmHg in the surgery group, immediately after the procedure. No Significant pressure gradient reduction was observed in the two groups immediately after the procedure (p value = 0.771).

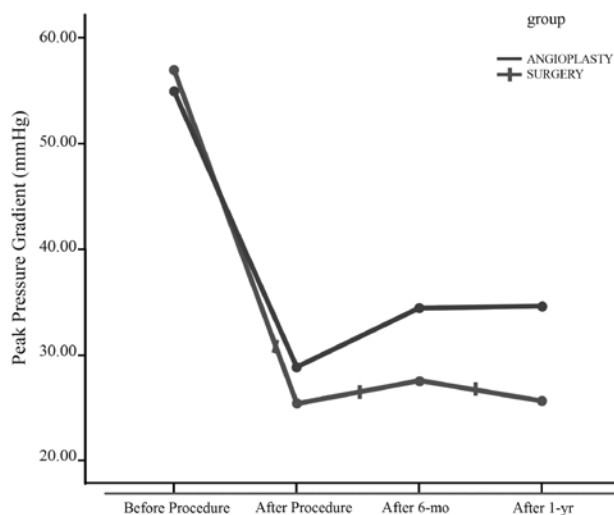


Figure 1. Peak pressure gradient changes in the study groups

The follow-up results are demonstrated in Table 2. Six months after balloon angioplasty/surgery, the mean peak pressure gradient reached 34.5 ± 14.1 mmHg in the balloon angioplasty group and 27.6 ± 16.0 mmHg in the surgery group (p value < 0.001). After twelve months, this finding was relatively unchanged. The trend of the peak pressure gradient changes was investigated using repeated measure

ANOVA models. The results showed that the main effect of the treatment to decrease the peak pressure gradient after twelve months was significant (p value < 0.001); however, neither the main effect of group nor treatment-group interaction was significant (p values were 0.265 and 0.468, respectively). The overall differences in the peak pressure gradient between the time periods after the procedures were not significant. The previously mentioned confounders were adjusted by the ANOVA model and the same findings were obtained. Descriptively, after eighteen months, the mean peak pressure gradient was 43.4 ± 15.8 mmHg in the balloon angioplasty group and 20.6 ± 13.8 mmHg in the surgery group. Also, after twenty-four months, the mean peak pressure gradient was 39.4 ± 12.5 mmHg in the balloon angioplasty group and 17.4 ± 9.0 mmHg in the surgery group. The p values for both of the findings were < 0.001 .

Nine (16.4%) patients from the balloon angioplasty group and 7 (6.3%) patients from the surgery group underwent repeated balloon angioplasty. There was no statistically significant difference in the re-do procedure between the two groups (p value = 0.231).

Complications included transient femoral artery spasm and thrombosis, minor linear dissection at the angioplasty site, and bleeding at the access site requiring blood transfusion for the balloon angioplasty group and transient postoperative arrhythmia and bleeding for the surgery group. Nevertheless, the retrospective design of our study precluded the registration of related data in the patients' files; it was, consequently, not feasible to perform statistical analysis on them.

Of the total study population, 18 infants died: three (5.5%) in the balloon angioplasty group and 15 (13.5%) in the surgery group. The 3 patients who died in the balloon angioplasty group were cardiomyopathic, and 1 of them died five months after the procedure because of associated heart lesions. Of the 15 patients who died in the surgery group, 2 expired after the second surgical procedure (corrective surgery of associated heart lesion), 1 sixteen months after the procedure due to severe complex cardiac lesion, and the remaining ones in the early postoperative period due to severe heart failure or sudden cardiac arrest. The difference in the mortality rate between the two groups was significant [5 (5.5% vs. 13 (11.6%), p value = 0.039]. However, after adjusting for such variables as cardiomyopathy and associated heart lesion via a logistic regression model, the association between the procedure type and mortality became non-significant (p value = 0.120).

Discussion

Coarctation of the aorta has the common clinical pattern of congestive heart failure in infants and has a poor prognosis if left untreated.¹



Balloon angioplasty is considered by some to be an acceptable treatment option for coarctation of the aorta,^{2,3,5} especially in older infants and children.^{3,4} Be that as it may, whereas some accept it as an alternative to surgery,⁶ others deem it palliative.⁸ It seems that balloon angioplasty is an acceptable treatment option for recurrent coarctation.¹

Our study describes the performance of balloon angioplasty for 55 and surgical repair for 112 infants with native coarctation of the aorta. The mean of the peak pressure gradients across the stenotic sites before and after the procedure revealed no significant difference between the two groups; it, therefore, seems that balloon angioplasty can be regarded as a palliative procedure conferring time to small infants to survive this critical situation, because of immediate relief of the pressure gradient.

Higher pressure gradients for the balloon angioplasty group at six months (p value < 0.001), one year (p value = 0.004), one and a half years (p value < 0.001), and two years (p value < 0.001) were observed.

Hospital stay was significantly longer in the surgery group (p value < 0.001), hinting at the more suitability of balloon angioplasty as a primary treatment option for critically ill infants.

Re-do procedure after balloon angioplasty was performed with a greater incidence compared with the surgery group, although this difference was not statistically significant (p value = 0.213).

There was a higher incidence of associated heart lesions in the surgery group (p value < 0.001) and cardiomyopathy in the balloon angioplasty group but with no statistically significant influence on the mortality rate.

Conclusion

Because of the incidence of re-coarctation, balloon angioplasty compared with surgical repair did not offer an improved outcome for our infants' coarctation. Balloon angioplasty can be considered particularly in critically ill infants with congestive heart failure and cardiomyopathy, although it may be a primary palliative procedure.

References

1. Beekman RH, III. Coarctation of the aorta. in: Allen HD, Driscoll DJ, Shaddy RE, Feltes TF, eds. Moss and Adams' Heart Disease in Infants, Children and Adolescents. 7th ed. Philadelphia: Lippincott William & Wilkins; 2008. p. 987-1004.
2. Massoud-Iel S, Farghly HE, Abdul-Monem A, Botros N, Kassem A, Magraby AE, Dawood A, Abdul-Hakam M. Balloon angioplasty for native aortic coarctation in different anatomic variants. *Pediatr Cardiol* 2008;29:521-529.

3. Patel HT, Madani A, Paris YM, Warner KG, Hijazi ZM. Balloon angioplasty of native coarctation of the aorta in infants and neonates: is it worth the hassle? *Pediatr Cardiol* 2001;22:53-57.
4. Lee CL, Lin JF, Hsieh KS, Lin CC, Huang TC. Balloon angioplasty of native coarctation and comparison of patients younger and older than 3 months. *Circ J* 2007;71:1781-1784.
5. Kalra GS, Arora R, Koshy G, Khanna R, Khalilullah M. Balloon dilatation of native coarctation of aorta in infancy: immediate and follow up results. *Indian Heart J* 1993;45:109-111.
6. Park Y, Lucas VW, Sklansky MS, Kashani IA, Rothman A. Balloon angioplasty of native coarctation in infants 3 months of age and younger. *Am Heart J* 1997;134:917-923.
7. Suárez de Lezo J, Pan M, Romero M, Segura J, Pavlovic D, Ojeda S, Algar J, Ribes R, Lafuente M, Lopez-Pujol J. Percutaneous interventions on severe coarctation of the aorta: a 21- year experience. *Pediatr Cardiol* 2005;26:176-189.
8. Bouzguenda I, Marini D, Ou P, Boudjemline Y, Bonnet D, Agnoletti G. Percutaneous treatment of neonatal aortic coarctation presenting with severe left ventricular dysfunction as a bridge to surgery. *Cardiol Young* 2009;19:244-251.