



Off-Pump CABG in a Patient with Dextrocardia Totalis: a Case Report

Ali Dabbagh, MD*, Ali Asghar Bolourian, MD

Shahid Beheshti University of Medicine, Tehran, Iran.

Received 12 June 2010; Accepted 27 September 2010

Abstract

Coronary revascularization in patients with dextrocardia is not a common clinical condition. There are very few cases of off-pump coronary artery bypass. A 64-year-old woman was admitted to a university hospital due to exertional chest pain. Her primary diagnosis was coronary artery disease superimposed on dextrocardia, which was first suspected on physical examination, with the patient having right-sided heart sounds on auscultation. It was corroborated by chest X-ray. After diagnostic evaluations, including coronary angiography, she underwent off-pump coronary artery bypass grafting due to a significant left main coronary artery stenosis associated with dextrocardia. Two years later, multi-slice CT angiography revealed patent grafts, demonstrating good clinical results.

J Teh Univ Heart Ctr 2011;6(3):155-157

This paper should be cited as: Dabbagh A, Bolourian A. Off-Pump CABG in a Patient with Dextrocardia Totalis: A Case Report. *J Teh Univ Heart Ctr 2011;6(3):155-157.*

Keywords: Dextrocardia • Coronary artery bypass, off-pump • Coronary artery disease

Introduction

Coronary revascularization in patients with dextrocardia is not a common clinical condition.¹⁻³ There are a few different tips in patients with this clinical state that are considered in part due to the anatomical malposition of the heart.^{2,3} Usually, these cases go for an on-pump technique and there are very few cases of off-pump coronary artery bypass grafting with mid-term follow-up.⁴⁻⁷

In this case report, an old woman with dextrocardia undergoing coronary revascularization is presented.

Case presentation

A 64-year-old woman was admitted to a university

hospital due to exertional chest pain with a functional class of II to III. Dextrocardia was suspected on physical examination, and it was corroborated by chest X-ray (Figure 1). She underwent selective coronary angiography, which documented dextrocardia, morphologic left main coronary artery disease with 90% narrowing, and morphologic left anterior descending artery disease with 70% narrowing. The morphologic right coronary artery was a dominant one and had some irregularities. She was, therefore, scheduled for elective coronary artery bypass. After installing the basic invasive and non-invasive monitoring devices, including left radial arterial cannulation for invasive arterial blood pressure line, twelve-lead electrocardiography, and pulse oximetry, anesthesia was induced after administering 500 mL of Ringer's solution over 15 minutes. Thereafter, a combination of sufentanil (0.7 mcg/Kg), midazolam (0.05 mg/Kg), and

*Corresponding Author: Ali Dabbagh, Associate Professor of Cardiac Anesthesia, Anesthesiology Research Center, Shahid Beheshti University of Medical Sciences, Tehran, Iran. 1998738341. Tel: +98 21 22074101. Fax: +98 21 22074100. E-mail: alidabbagh@yahoo.com.

atracurium (0.5 mg/Kg) was used for the induction of anesthesia and tracheal intubation. Afterwards, the central venous line was introduced through the left internal jugular vein in concordance with underlying dextrocardia; however, the patient had a large skin nevus on the left side of the neck and, as a result, a right central venous catheter was inserted.

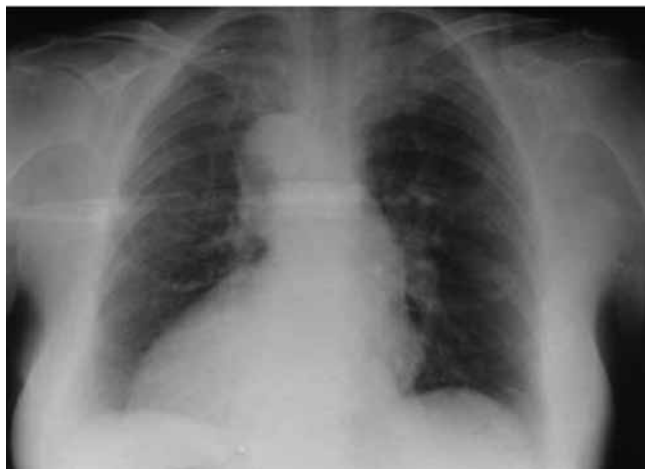

Figure 1. Preoperative chest X-ray, demonstrating dextrocardia as a right sided cardiac shadow

For the maintenance of anesthesia, 1 to 1.5% isoflurane was administered combined with an intravenous infusion of 100 mcg sufentanil, 150 mg atracurium, and 10 mg midazolam to keep the level of anesthesia depth between 40 to 60 according to the Bispectral index monitoring. After median sternotomy and longitudinal pericardiotomy, the surgical process was continued by harvesting the right internal mammary artery (RIMA) and a piece of the greater saphenous vein from the left leg. The RIMA was then anastomosed to the morphologic left anterior descending artery (LAD). Also, two saphenous vein grafts were anastomosed to the diagonal and obtuse marginal branches.

During the course of anesthesia, hemodynamic monitoring was continuously performed. Also, a combination of esmolol, intravenous nitrates, amiodarone, and other cardio-active drugs was used to keep the hemodynamic status stable and calm. Proximal anastomosis was done while the systolic blood pressure was kept constant between 85 to 90 mmHg.

The operation was done with the surgeon being positioned on the left side of the patient. After the termination of the surgery, the patient was transferred to the cardiac intensive care unit uneventfully while mechanically ventilated and monitored for hemodynamic parameters.

Inside the intensive care unit, the patient was fully awake after five hours from entry to the ward; she was extubated shortly afterwards. Minimal chest tube drainage was seen, which was acceptable. There was no major complication overnight, and the patient was transferred to the ward the day after surgery. She was discharged from the hospital

on the fifth postoperative day (Figure 2). She was on close observation in her follow-up visits without any angina. On multi-slice CT angiography, performed two years later, all of the grafts were patent and perfect (Figure 3).

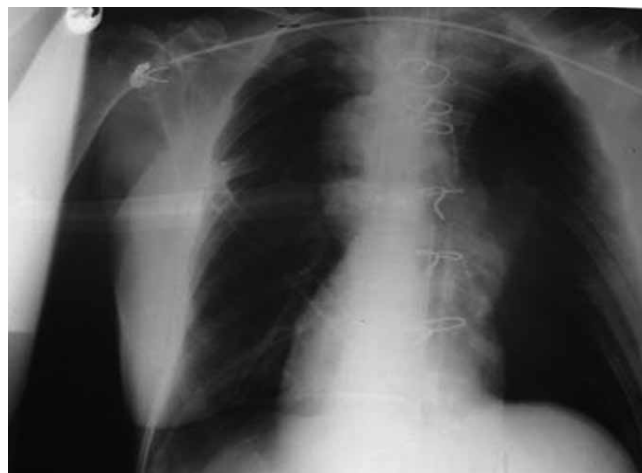

Figure 2. Early postoperative chest X-ray

Discussion

Dextrocardia, a congenital anomaly, is not clinically common.¹⁻³ In adult cases, it is a rare condition to see dextrocardia accompanied by atherosclerotic coronary disease needing surgical intervention because these cases usually do not have enough life span to present with atherosclerotic coronary artery disease processes, due to co-existing anomalies.²⁻⁵ The incidence of dextrocardia associated with situs inversus totalis is 1 to 10,000, and these patients usually continue their lives until they develop ischemic heart disease, which requires surgery.⁶⁻⁸

There are a number of differences in the management of the coronary revascularization procedure in these patients, and these differences are usually related to the anatomic malposition of the heart. Usually, central venous catheters are placed through the left side in such patients to have a straight course to the anatomically “left” atrium, which receives the blood from the systemic veins. However, in this case, a right central venous catheter was inserted because of the presence of a large skin nevus on the left side of the neck.

In this patient, myocardial revascularization was performed by harvesting the RIMA and anastomosing it to the morphologic LAD. Also, two pieces of the saphenous venous graft were anastomosed to the diagonal and obtuse marginal branches. The surgical technique was in many aspects the same as that for off-pump coronary artery bypass grafting for levocardia, although for a right-handed surgeon it would be much easier to stand on the left side of the patient. Of course, this is not always the rule and the surgeon may stand on the right or the left side of the patient, according to

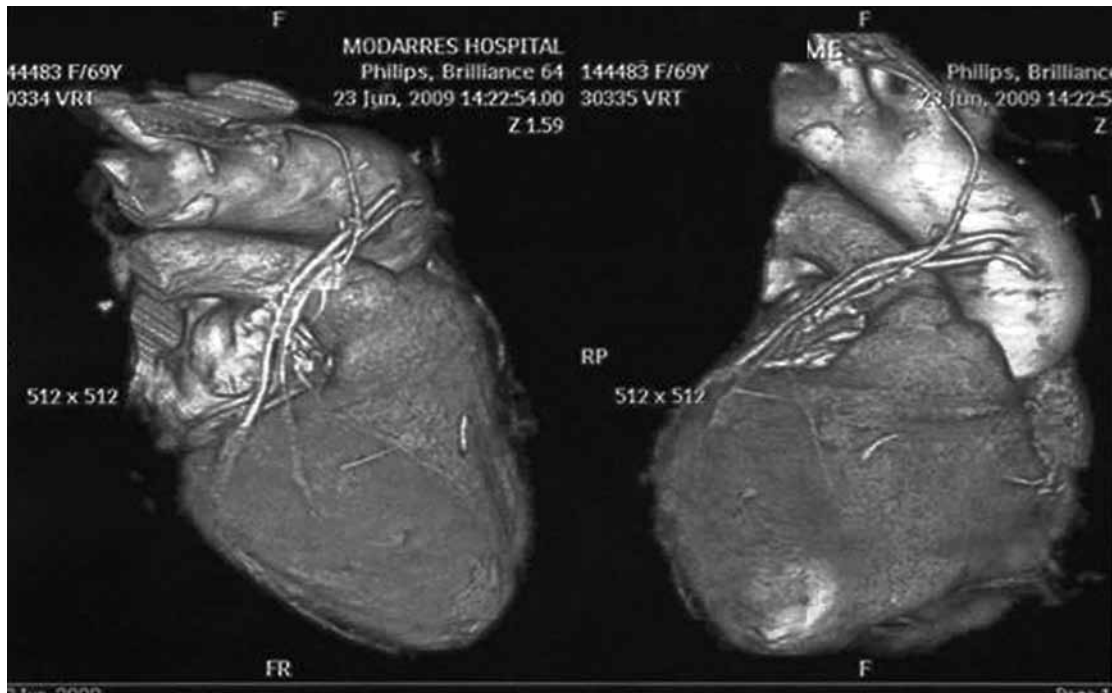
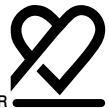

Figure 3. Follow-up multi-slice CT angiography, demonstrating patent coronary artery grafts after two years

his or her easiness.

To our knowledge, this is the first case report of off-pump coronary artery bypass grafting in a patient with dextrocardia and severe coronary artery disease with excellent mid-term follow-up.

Acknowledgement

The authors would like to acknowledge the kind efforts made by the operating room physicians and nurses at Shahid Modarres Hospital, Shahid Beheshti University of Medical Sciences, Sciences, Tehran, Iran.

References

1. Saadi EK, Dussin LH, Nicolao A, Zago AJ. Coronary artery bypass grafting in a patient with situs inversus totalis and dextrocardia. *Rev Bras Cir Cardiovasc* 2007;22:346-348.
2. Baltalarli A, Tanriverdi H, Gökşin I, Onem G, Rendeci O, Saçar M. Coronary arterial revascularization in an adult with congenitally corrected transposition of great arteries and dextrocardia. *J Card Surg* 2006;21:296-297.
3. Kuwata T, Kawata T, Ueda T, Sakaguchi H, Nagasaka S, Taniguchi S. Off-pump quintuple coronary artery bypass grafting for situs inversus totalis. *Jpn J Thorac Cardiovasc Surg* 2004;52:473-475.
4. Abdullah F, Mazalan SL. Off-pump coronary artery bypass grafting in a high-risk dextrocardia patient: a case report. *Heart Surg Forum* 2004;7:e186-188.
5. Burgess N, Isert P. Anaesthetic considerations for patients undergoing hypothermic cardiopulmonary bypass for complex neurovascular lesions: case presentation and review. *Anaesth Intensive Care* 2001;29:406-416.
6. Abensur H, Ramires JA, Dallan LA, Jatene A. Right mammary-coronary anastomosis in a patient with situs inversus Chest 1988;94:886-887.
7. Hynes KM, Gau GT, Titus JL. Coronary heart disease in situs inversus totalis. *Am J Cardiol* 1973;31:666-669.
8. Karimi A, Salehiomran A, Ahmadi H, Yazdanifard P, Karimi A, Salehiomran A, Ahmadi H, Yazdanifard P. Total myocardial revascularization for situs inversus totalis with dextrocardia: a case report. *J Med Case Reports* 2007;1:18.