



Aortic Arch Replacement with Moderate Hypothermia and a Modified Three-PUMP Circuit

Prashant Vaijyanath, MS, MCh*, Lavanya Sekar, BSc, Mary Smitha Thomas, MD

Frontier-lifeline, Dr. K. M. Cherian Heart Foundation, Chennai, India.

Received 04 August 2010; Accepted 13 December 2010

Abstract

A strategy employing moderate hypothermia for the replacement of the aortic arch is proposed to avoid the complications of profound hypothermic circulatory arrest. Two patients underwent the complete replacement of the aortic arch using three pumps - for the brain, thoracoabdominal aorta, and heart, respectively. There were no complications and the patients were extubated uneventfully. The method preserved the auto-regulation of the cerebral blood flow without high vascular resistance.

J Teh Univ Heart Ctr 2011;6(4):211-213

This paper should be cited as: Vaijyanath P, Sekar L, Thomas M. S. Aortic Arch Replacement with Moderate Hypothermia and a Modified Three-PUMP Circuit. *J Teh Univ Heart Ctr* 2011;6(4):211-213.

Keywords: Surgical procedures, operative • Aorta, thoracic • Cardiopulmonary bypass • Hypothermia • Cerebrovascular circulation

Introduction

Profound hypothermic total circulatory arrest and older age are usually associated with significant neuropsychological deficits. The morbidity of hypothermia and the mismatch between the cerebral oxygen demand and the supply with regards to temperature have encouraged the search for new cardiopulmonary bypass strategies.¹ Antegrade cerebral perfusion with moderate hypothermia or normothermia is now established as a safe and effective modality for total arch replacement.² Antegrade perfusion was popularized by

Bachet et al.,³ following the concern of converting a small cerebral infarct into a large one by retrograde cerebral perfusion.⁴ Herein, we describe two different perfusion and surgical strategies tailored specific to aortic pathology to replace the total arch without the need for deep hypothermic circulatory arrest.

Case Reports

Case 1

A 55-year-old male patient presented with aortic arch aneurysm and underwent aortic arch replacement under moderate hypothermia using three arterial pump heads (Figure 1) (one -antegrade perfusion to the arch vessels, second - retrograde perfusion through the femoral artery, and the third to perfuse the heart).

Technique

Cardiopulmonary bypass was established between the bicaval and right femoral artery return. A second arterial line geared by a separate roller pump was used via an 8-mm graft sutured to the right axillary artery. The left common carotid artery and left subclavian artery were selectively cannulated

*Corresponding Author: Prashant Vaijyanath, Professor of Cardiac Surgery, Frontier-lifeline, Dr. K. M. Cherian Heart Foundation, Chennai, India. 600101. Tel: +91 44 42017575. Fax: +91 44 42180066. E-mail: pvaijyanath@hotmail.com.

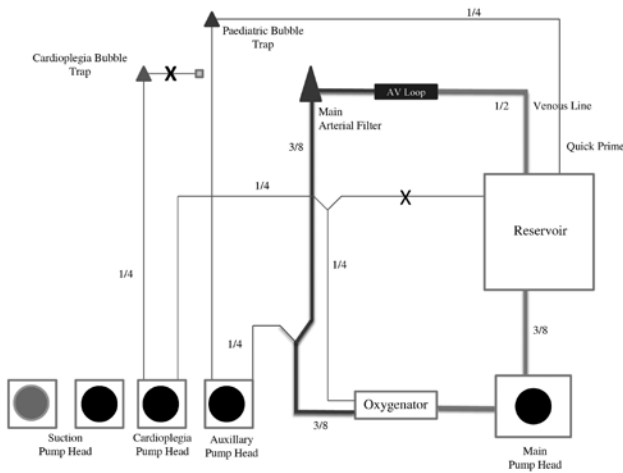


Figure 1. Circuit assembly showing lower body perfusion through the main pump head. A second pump head is used to perfuse the brain

to perfuse the supra aortic vessels. The rate of the flow was adjusted to the core temperature, maintaining the right radial artery pressure of 60-70 mmHg and the left femoral artery pressure of 50-70 mmHg (Table 1).

The aortic arch was replaced via the standard technique with distal anastomosis as a mini elephant trunk at T4 and T5 levels beyond the left subclavian artery and proximal aortic anastomosis on the ascending aorta before the innominate artery. Individual head vessels were implanted with a bovine arch anatomy dacron conduit of 12 mm for the innominate artery and 8 mm for the left common carotid artery and the left subclavian artery as previously described by Griep et al.⁵

Table 1. Flow rates for arch aneurysm repair

Core Temperature (°C)	Rate of Flow (ml/min/m ²)	Line Pressure (mmHg)
Cerebral Circuit		
28	650	110-120
32	750	110-120
37	900-1100	110-120
Femoral Circuit		
28	3000	175-200
32	3800-4200	100-150
37	4900-5200	175-200

Case 2

A 59-year-old male with the dissection of the aorta extending from the ascending aorta to the aortic bifurcation and into the brachiocephalic trunk underwent the arch replacement and the long elephant trunk procedure under

moderate hypothermia using three arterial pump heads (Figure 2) (one - antegrade bi-axillary perfusion to the arch vessels, second - antegrade distal aortic perfusion through the aortic graft, and the third one to perfuse the heart).

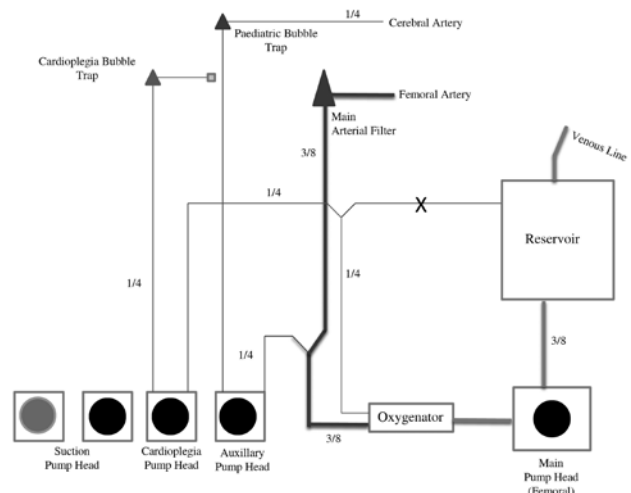


Figure 2. Circuit assembly showing cerebral perfusion through the main pump head. A second pump head is used to perfuse the lower body through a cuffed endotracheal tube introduced through the graft

Technique

Cardiopulmonary bypass was established between bicaval and bi-axillary 8-mm Dacron grafts. A second arterial line geared by a separate roller pump was used for modified distal aortic perfusion via a 7 Fr cuffed endotracheal tube, introduced into the long elephant trunk.⁶ Total arch was replaced via a technique described by Taniguchi et al.⁷

The rate of the flow was adjusted to the core temperature, maintaining the right radial artery pressure of 60-70mm Hg and left femoral artery pressure of 40-70mmHg (Table 2).

Table 2. Flow rates for aortic dissection repair

Core Temperature (°C)	Rate of Flow (ml/min/m ²)	Line Pressure (mmHg)
Axillary arteries		
25	1800-2300	110-120
28	3000-3500	110-120
34	4200-4500	110-120
37	4200-4500	110-120
Thoracoabdominal Aorta		
25	500-1000	40-50
28	500-1000	40-50
32	1500-2000	100-150
34	2000-2500	100-140
37	2000-2500	100-140



Discussion

In view of the limitations of circulatory arrest and the variety of surgical procedures described for replacing the total arch, we herein describe a surgical and perfusion strategy tailor-made to individual aortic pathology. This strategy is supported by two fundamental elements - the superiority of moderate or normothermia over deep hypothermia⁴ and the superiority of antegrade cerebral perfusion over retrograde perfusion. Our technique also eliminates the "time factor" in the aortic arch repair and allows a meticulous anastomosis. It not only protects the cerebral circulation but also obviates ischemic multi-organ injuries by effective distal aortic perfusion either antegrade as in long elephant trunk proximal to the innominate artery or retrograde perfusion via the femoral artery.

The technique described herein appears to be safe and easy to perform. An advantage of our method is that all the anastomoses can be performed without the limiting time factor of circulatory arrest. Technically, however, a close co-ordination between the surgical, anesthesiology and perfusion teams is required and the strategy needs to be planned for an optimal outcome.

References

1. Grigore AM, Mathew J, Grocott HP, Reves JG, Blumenthal JA, White WD, Smith PK, Jones RH, Kirchner JL, Mark DB, Newman MF; Neurological Outcome Research Group; CARE Investigators of the Duke Heart Center. Cardiothoracic Anesthesia Research Endeavors. Prospective randomized trial of normothermic versus hypothermic cardiopulmonary bypass on cognitive function after coronary artery bypass graft surgery. *Anesthesiology* 2001;95:1110-1119.
2. Touati GD, Roux N, Carmi D, Degandt A, Benamar A, Marticho P, Nzomvuama A, Poulain HJ. Totally normothermic aortic arch replacement without circulatory arrest. *Ann Thorac Surg* 2003;76:2115-2117.
3. Bachet J, Guilmet D, Goudot B, Termignon JL, Teodori G, Dreyfus G, Brodaty D, Dubois C, Delentdecker P. Cold cerebropoplegia. A new technique of cerebral protection during operations on the transverse aortic arch. *J Thorac Cardiovasc Surg* 1991;102:85-93.
4. Ehrlich MP, Hagl C, McCullough JN, Zhang N, Shiang H, Bodian C, Griep RB. Retrograde cerebral perfusion provides negligible flow through brain capillaries in the pig. *J Thorac Cardiovasc Surg* 2001;122:331-338.
5. Spielvogel D, Mathur MN, Lansman SL, Griep RB. Aortic arch reconstruction using a trifurcated graft. *Ann Thorac Surg* 2003;75:1034-1036.
6. Klodell CT, Hess PJ, Beaver TM, Clark D, Martin TD. Distal aortic perfusion during aortic arch reconstruction: another tool for the aortic surgeon. *Ann Thorac Surg* 2004;78:2196-2198.
7. Taniguchi K, Toda K, Hata H, Shudo Y, Matsue H, Takahashi T, Kuki S. Elephant trunk anastomosis proximal to origin of innominate artery in total arch replacement. *Ann Thorac Surg* 2007;84:1729-1734.