

Photo Clinic

Senile Calcification of the Trachea, Aortic Arch, and Mitral Annulus: An Incidental Finding on Chest X-Ray

Mahmood Hosseinzadeh Maleki, MD, Toba Kazemi, MD*, Navid Davoody, MD

Atherosclerosis and Coronary Artery Research Center, Birjand University of Medical Sciences, Birjand, Iran.

Abstract

A 94-year-old woman presented with dizziness and hypotension of 2 days' duration. She denied any syncope, presyncope, or angina. She had received a permanent pacemaker 12 years previously for the management of complete heart block (CHB), but she failed to program it. Twelve-lead electrocardiography revealed CHB with ventricular escape rhythm (40/min), so we inserted a temporary pacemaker. Anteroposterior chest X-ray showed trachea, aortic arch, and severe mitral valve calcification.

Tracheal calcification is usually seen after 40 years old without clinical importance. However, it is seen in patients with renal failure, metastases, and prolonged use of warfarin as well as in pregnancy.¹⁻³

J Teh Univ Heart Ctr 2015;10(4):219-220

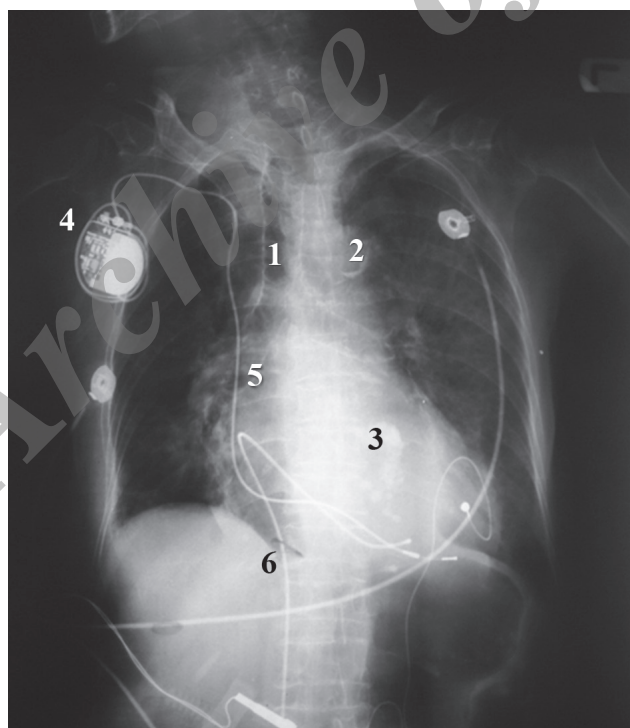


Figure 1. Chest X-ray shows calcification of the trachea (1), aortic arch (2), and mitral annulus (3). It also demonstrates the temporary pacemaker (4), and two leads from the permanent (5) and the temporary (6) pacemakers.

*Corresponding Author: **Toba Kazemi**, Professor of Cardiology, Birjand University of Medical Sciences, Ghaffari Avenue, Birjand, Southern Khorasan Province, Iran. Tel: +98 561 4443001. Fax: +98 915 5610860. Email: drtooba.kazemi@gmail.com.



Keywords: Calcification, physiologic • Trachea • Aorta • Mitral valve

This paper should be cited as: Hosseinzadeh Maleki M, Kazemi T, Davoody N. Senile Calcification of Trachea, Aortic Arch and Mitral Annulus: An Incidental Finding on Chest X Ray. J Teh Univ Heart Ctr 2015;10(4):219-220.

References

1. Alkan O, Tokmak N, Demir S, Yildirim T. Metastatic pulmonary calcification in a patient with chronic renal failure. J Radiol Case Rep 2009;3:14-17.
2. Miyahara Y, Takayanagi N, Yoneda K, Tsuchiya N, Morokawa N, Yamaguchi S, Tokunaga D, Saitoh H, Kurashima K, Ubukata M, Yanagisawa T, Sugita Y. A case of the metastatic calcification of trachea, bronchus, and lung. Nihon Kogyuki Gakkai Zasshi 2007;45:731-376.
3. Nour SA, Nour HA, Mehta J, Roy T, Byrd R. Tracheobronchial calcification due to warfarin therapy. Am J Respir Crit Care Med 2014;189:e73.

Archive of SID