



Accuracy of Cone-Beam Computed Tomography in Comparison with Standard Method in Evaluating Root Canal Morphology: An *In Vitro* Study

Zahra Dalili Kajan^{a*}, Mehran Taramsari^b, Negar Khosravi Fard^c, Mohsen Kanani^d

^a Dental Sciences Research Center, Department of Maxillofacial Radiology, Dental School, Guilan University of Medical Sciences, Rasht, Iran; ^b Dental Sciences Research Center, Department of Endodontics, Dental School, Guilan University of Medical Sciences, Rasht, Iran; ^c Department of Maxillofacial Radiology, Dental School, Guilan University of Medical Sciences, Rasht, Iran; ^d Dentist, Private Office, Dental School, Guilan University of Medical Sciences, Rasht, Iran

ARTICLE INFO

Article Type:

Original Article

Received: 20 Sep 2017

Revised: 04 Jan 2018

Accepted: 17 Jan 2018

Doi: 10.22037/iej.v13i2.18614

*Corresponding author: Zahra Dalili Kajan, Department of Maxillofacial Radiology, Dental School, Professor Samii Blvd. Rasht, Iran. Postal code: 41941- 73774

Tel: +98-13 3336 3622

E-mail: zahradalili@yahoo.com

ABSTRACT

Introduction: In order to successfully perform root canal treatment, thorough knowledge of the root canal anatomy is essential. Cone-beam computed tomography (CBCT) has the ability to improve our understanding of the root canal system. The goal of the present study was to compare the accuracy of CBCT in revealing the number and form of the root canals of different maxillary and mandibular teeth with clearing and staining method. **Methods and Materials:** CBCT images were taken from 80 extracted human teeth fixed in agar arch models. The number and configuration of the root canals of each tooth were determined by the two observers. Then the teeth were cleared and stained. Two endodontists evaluated the number and forms of the root canals. The accuracy of CBCT was determined and compared with clearing and staining by Fisher's exact test. The agreement of two methods in detection of the number and form of the root canals were evaluated by Kappa test, $P \leq 0.05$. **Results:** CBCT accurately detected the number of root canals in 129 (92.1%) of 140 roots and the form of the canals in 119 (85%) of the roots. There was no significant difference between the accuracy of CBCT in the detection of the number ($P=0.13$) and forms ($P=0.4$) of root canals of maxillary and mandibular teeth. The agreement between CBCT, and tooth clearing and staining in detection of the number of root canals was excellent in the maxilla ($\text{kappa}=0.88 \pm 0.05$) and good in the mandible ($\text{kappa}=0.720 \pm 0.097$). The agreement between the two methods in demonstration of the form of root canals was good in both maxillary ($\text{kappa}=0.73 \pm 0.07$) and mandibular ($\text{kappa}=0.67 \pm 0.09$) teeth. **Conclusion:** CBCT provides accurate information about root canal morphology. Application of this technique could result in more successful endodontic treatment.

Keywords: Anatomy; Cone-Beam Computed Tomography; Root Canals

Introduction

Successful completion of root canal treatment requires accurate knowledge of internal root morphology and its possible variations, which directly influence the quality of debridement, disinfection, and obturation of the root canal system [1-6]. The number and morphology of the root canals vary according to age, sex, and ethnicity [1, 7-10]. Furthermore, it has been postulated that the complexities of the root canal system are determined

genetically and therefore should be considered among different populations [2, 3].

Various methods have been applied for analysis of the root canal morphology, of which the most common are canal staining and tooth clearing [2, 3, 10-12], conventional radiography [13, 14], digital radiographic techniques [15-17], and radiographic assessment enhanced with contrast media [18, 19]. More recently, cone-beam computed tomography (CBCT) [20], modified canal staining and tooth clearing [21] and micro-computed tomography

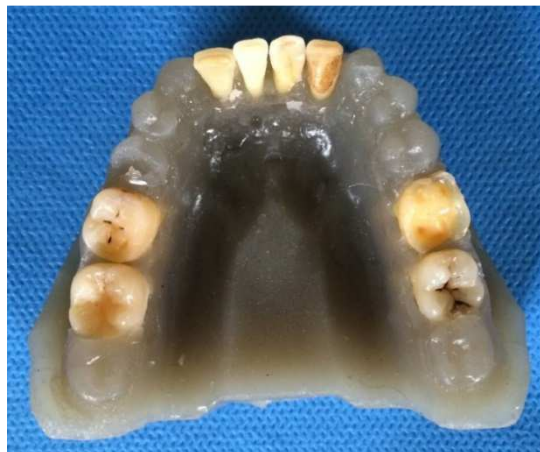

Figure 1. Agar model of mandible for CBCT evaluation

(micro-CT) [22-24] have been used. The most frequently used *in vivo* methods among the abovementioned techniques are periapical radiography and CBCT. Periapical radiographs can be misleading for the assessment of root anatomy due to the superimposition of the roots or their surrounding structures [1]. In contrast, numerous studies have used CBCT as an accurate method for evaluating the root canal system [25-27].

CBCT was introduced to the field of endodontics in 1990. The technique uses a cone-shaped source of radiation to acquire image data in a full or half arc of rotation, which displays the three-dimensional outline of an object, thereby enabling the clinician to achieve a more realistic representation of the structures being imaged. The ability of CBCT to reduce or eliminate the superimposition of the surrounding structures makes it superior to periapical radiographs [27]. Blattner *et al.* [25] evaluated the presence of second mesiobuccal (MB2) canal in maxillary first and second molar teeth using CBCT and concluded that this technique is a reliable method of detecting additional canals when compared with the gold standard of physical sectioning.

Oridenla-Zapata *et al.* [24] in a comparative study on accuracy of three different systems; micro-CT, CBCT and the clearing method reveals that CBCT and clearing method were not accurate method for evaluating the actual root anatomy but this study is only limited to mesial root of mandibular first molar.

To the best of our knowledge the accuracy of CBCT in comparing peripheral quantitative computed tomography, spiral computed tomography (SCT), plain, and contrast medium-enhanced digital radiographs in evaluating the root canal morphology was studied in one study [28] but it was used widespread in this kind of epidemiological evaluation.

The present study was designed to compare CBCT in revealing the number and form of the root canals of maxillary and mandibular teeth in comparison with the gold standard of tooth

clearing and staining. The most important questions are “what is the accuracy of CBCT for studying the root canal morphology?” and “is it comparable with reliable method of clearing and staining in this kind of endodontic evaluations?”

Materials and Methods

Sample preparation

Eighty extracted human teeth, including 20 first or second mandibular molars (8 mandibular first and 12 mandibular second molars), 20 mandibular central or lateral incisors (10 of each teeth), 20 first or second maxillary molars (13 maxillary first, 7 maxillary second molars), and 20 single-rooted maxillary premolars, were selected randomly from the collected samples in department of maxillofacial surgery, Guilan University of Medical Sciences. The teeth were stored in Savlon antiseptic solution. The Exclusion criteria for tooth selection were root caries, root crack and severe calcified canal. Calcification of the canals were evaluated in periapical radiographs by an endodontist that was not as invited as observers of CBCT or cleared and stained samples. The examiners were blinded to the anatomy of the pulp canals. The teeth were randomly arranged in 10 agar jaw models (Figure 1). Each jaw contained eight teeth that included either four mandibular molars and four mandibular incisors or four maxillary molars and four maxillary premolars. The teeth were fixed in place with wax. Agar was selected due to its ability to simulate soft tissues surrounding the teeth. This study was confirmed by Ethic committee of Guilan University of Medical Sciences; IR.GUMS.REC.1394.514. “All procedures followed were in accordance with the ethical standards of the responsible committee on human experimentation (Guilan University of Medical Sciences) and with the Helsinki Declaration of 1975, as revised in 2008”.

Imaging examinations

Each jaw model was imaged by a CBCT device (NewTom, Verona, Italy) with the exposure parameters of 110 kV, 0.5 mA and 2.04 mA. The 4-inch field of view (FOV) (0.200-0.240 mm voxel size) in standard scan mode was selected in imaging protocol. The volumetric data set of each imaging procedure was converted into study images *via* NNT software (NewTom, Verona, Italy). A maxillofacial radiologist and an endodontist both with over 10 years of professional experience evaluated the axial and cross-sectional image slices (1 mm thickness at 0.5 mm intervals). The observers of imaging examination section were different from the observers of tooth clearing and staining section. The observers' expertise were very important in each section. The number and configuration of the root

canals of each tooth were determined by the two observers. Canal types were determined according to Vertucci's classification. [29] CBCT images of 20 teeth were randomly selected and re-evaluated by the observers to evaluate the intra-examiner reliability or the inter-observer agreement.

Tooth clearing and staining

After imaging, the teeth were taken out of the agar models and prepared for clearing and staining. First, the root surfaces were debrided with a curette. The crowns of the teeth were cut at the level of the cemento-enamel junction. The teeth were placed in a 5.25% sodium hypochlorite solution for 24 h to eliminate any residual pulp tissue. The teeth were rinsed with water for 1 h and then dried. Then, the samples were placed in 5% nitric acid for 72 h. The solution was agitated every 8 h and renewed every 24 h. After 72 h, the samples were rinsed with water for 4 h. After rinsing, the teeth were dehydrated with 80% ethylic alcohol for 12 h, 90% ethylic alcohol for 1 h, and 100% ethylic alcohol for 1 h (in that order). Liquid ink (Pelikan, Iran) was injected into the canals with a 27-gauge needle and suctioned apically until seen throughout the apical foramen. Finally, the samples were placed in 99% methyl salicylate. Once the teeth were cleared and stained, two endodontists evaluated the number and forms of the root canals by observation based on Vertucci classification. Using of magnifier by observers was optional. Examples of CBCT images of the two teeth as well as their appearances after clearing and staining are shown in [Figures 2 and 3](#).

All data were analyzed with SPSS software (SPSS version 22, SPSS, SAS, Chicago, IL, USA). Fisher's exact test was used

to assess the frequency of correct detection of the number and form of root canals by CBCT. The strength of agreement between the results obtained from CBCT and tooth clearing and staining was determined *via* the Kappa test. The level of significance was set at 0.05.

Results

In the current study, a total of 140 roots were evaluated with respect to the ability of CBCT to reveal the number and form of the pulp canals. The intra-examiner reliability in evaluation of CBCT images was calculated to be 91%. CBCT accurately detected the number of pulp canals in 129 (92.1%) roots. With respect to the configuration of root canals, 119 (85%) roots were correctly demonstrated by CBCT; however, the forms of root canals were not properly visualized in 21 (15%) roots. [Table 1](#) presents the frequency of correct diagnosis of the number(s) and forms of the root canals by CBCT in maxillary and mandibular teeth. The frequency of correct diagnosis of the number(s) and form(s) of the root canals according to the tooth type and root type is presented in [Tables 2 and 3](#), respectively. Detectability of the number and form of the root canals was uninfluenced by the type of jaw, tooth, or root.

The agreement between CBCT and tooth clearing and staining in detecting the number and revealing the form of the root canals was determined by Kappa agreement test. The strength of agreement is divided to poor (<0.2), fair (0.21-0.4), moderate (0.41-0.6), good (0.61-0.8) and excellent (0.81-1). The agreement between CBCT, and tooth clearing and staining in

Table 1. Frequency of correct diagnosis of the number and form of the root canals in maxillary and mandibular teeth by CBCT

Tooth	Correct diagnosis	
	Number of root canals	Form of root canals
Maxillary teeth	76 (95%)	69 (86.3%)
Mandibular teeth	53 (88.3%)	50 (83.3%)
P-value*	0.13	0.4

*Fisher's exact test, $P \leq 0.05$

Table 2. Frequency of correct diagnosis of the number and form of the root canals by CBCT according to tooth type

Jaw	Tooth type	Correct diagnosis			
		Number of root canals	P-value*	Form of root canals	P-value*
Maxilla	Molar teeth	57 (95%)	0.69	51 (85%)	0.45
	Premolar teeth	19 (95%)		18 (90%)	
Mandible	Molar teeth	36 (90%)	0.43	33 (82.5%)	0.56
	Incisor teeth	17 (85%)		17 (85%)	

*Fisher's exact test, $P \leq 0.05$

detection of the number of root canals was excellent in the maxilla ($\kappa=0.88\pm0.05$) and good in the mandible ($\kappa=0.720\pm0.097$) by considering the *P*-value of 0.001. The agreement between the two methods in demonstration of the form of root canals was good in both maxillary ($\kappa=0.73\pm0.07$) and mandibular ($\kappa=0.67\pm0.09$) teeth. The *P*-value was 0.001. The agreement between CBCT and tooth clearing and staining in detecting the number and revealing the form of the root canals based on the tooth type was presented in Table 4.

Discussion

In the present study, we evaluated the accuracy of CBCT in detecting the number and revealing the form of root canals and compared the results with those of the gold standard tooth clearing and staining method. Maxillary molar and premolar teeth as well as mandibular molar and incisor teeth were selected as study samples since these teeth have the greatest amount of variation in the features of the root canal system.

In very similar study to ours; Ordinola-Zapata *et al.* [24] revealed that type I of root form in mesial root of mandibular first molar in clearing method was detected lower than CBCT and micro-CT but in type II, there was no difference. Although, the clearing method has the limitation in flowing laterally into fine anatomical root structures such as isthmii but it could not explain the Ordinola-Zapata *et al.* [24] findings. The type I root form could not have above-mentioned limitation in flowing the dye. The CBCT machine

used in our study has 360 degree rotation around the object that is comparable with the degree of rotation in micro-CT thus the details of root canal space defined more accurately. In the study by Ordinola-Zapata *et al.* [24] the device was Palanmeca (proMax 3Ds) with 200 degree rotation around the object.

With respect to the detection of root canals, CBCT was successful in 129 of 140 (92.1%) roots; however, CBCT did not accurately detect the number of root canals in 11 (7.9%) roots of teeth, of which seven teeth belonged to the mandible (four molars and three incisors) and four belonged to the maxilla (three molars and one premolar).

The percentage of correct diagnoses of the number of root canals with CBCT in this study was 92.1%, which was comparable with the result reported by Neelakantan *et al.* [28] (99%) but much higher than the findings reported by Blattner *et al.* [25] (78.95%). This discrepancy may possibly be explained by the differences in the sample sizes, types of CBCT devices, and thickness of the image slices. Michetti *et al.* [30] showed a high correlation between CBCT and histological sections but they studied only nine extracted teeth.

With respect to tooth type, CBCT correctly diagnosed the number of root canals in 36 of 40 mandibular molar roots, 17 of 20 mandibular incisor roots, 57 of 60 maxillary molar roots, and 19 of 20 maxillary premolar roots. These results were not statistically significant; in other words, tooth type was not an influential factor in the accuracy of CBCT for detecting the number of canals. This was comparable to the results reported by Neelakantan *et al.* [28].

Table 3. Frequency of correct diagnosis of the number and form of the root canals by CBCT according to root type in multi-rooted teeth

Tooth	Root type	Correct diagnosis			
		Number of root canals	<i>P</i> -value*	Form of root canals	<i>P</i> -value*
Maxillary molars	Mesiobuccal	18 (90%)	0.76	13 (65%)	0.07
	Distobuccal	19 (95%)		18 (90%)	
	Palatal	20 (100%)		20 (100%)	
Mandibular molars	Mesial	18 (90%)	0.99	15 (75%)	0.48
	Distal	17 (89.5%)		17 (89.5%)	

*Fisher's exact test

Table 4. Agreement of CBCT and tooth clearing and staining in demonstrating the number and form of the root canals according to tooth type

Jaw	Tooth type	Number of root canals	<i>P</i> -value	Form of root canals	<i>P</i> -value
		κ values(SE)*		κ values(SE)	
Maxilla	Molar teeth	0.85 (0.08)	0.0001	0.63 (0.09)	0.0001
	Premolar teeth	0.89 (0.10)	0.0001	0.83 (0.11)	0.0001
Mandible	Molar teeth	0.77 (0.10)	0.0001	0.67 (0.10)	0.0001
	Incisor teeth	0.58 (0.20)	0.004	0.65 (0.17)	0.0001

*SE; standard error

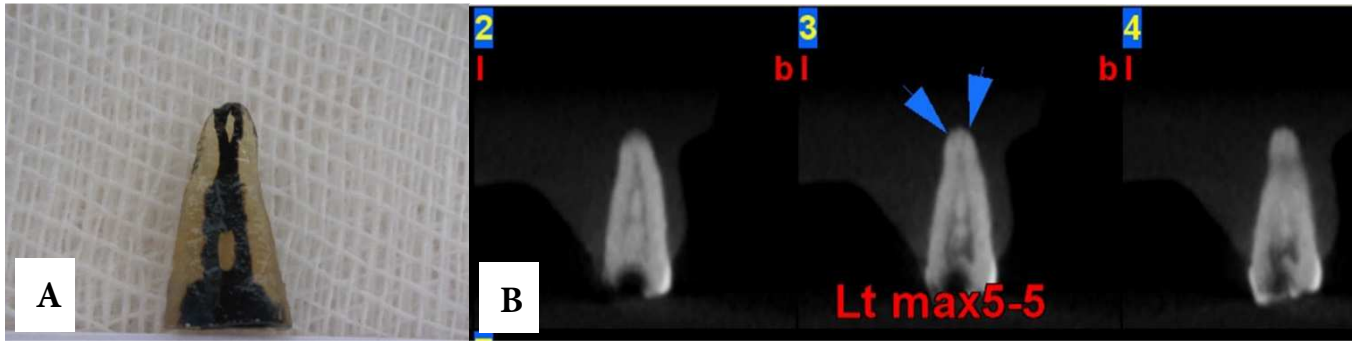


Figure 2. A) A maxillary premolar tooth after being cleared and stained; B) Cross-sectional CBCT images of the same tooth within the agar model

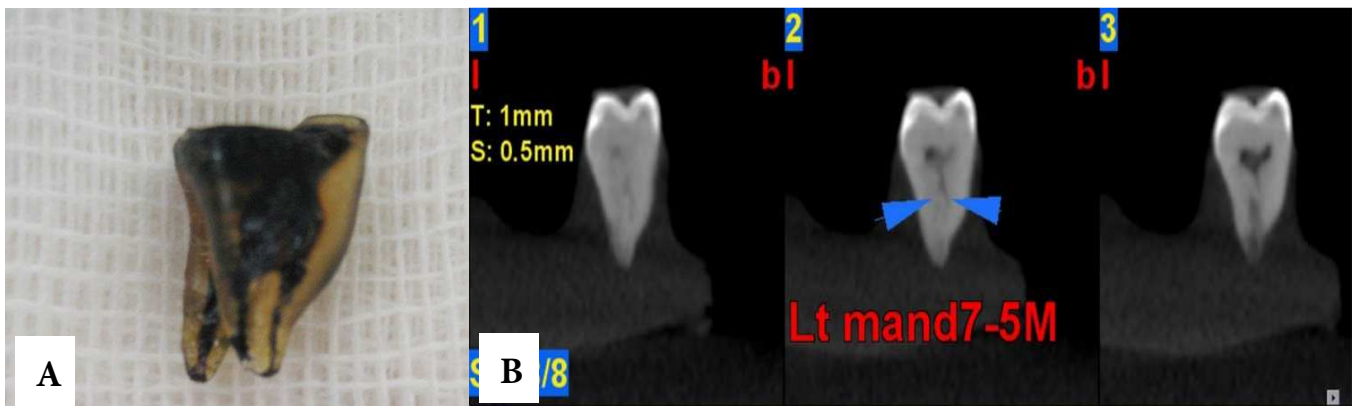


Figure 3. A) A mandibular molar tooth after clearing and staining; B) Axial and cross-sectional CBCT images of the mesial root of the same tooth fixed in an agar model

Neelakantan *et al.* [28] assessed the accuracy of various techniques for evaluation of the root and canal morphology in extracted human teeth. They concluded that CBCT did not differ greatly from the gold standard of tooth clearing and staining. Of interest, the accuracy of CBCT was shown to be higher than that of spiral CT and plain digital radiography [28]. Mittachi *et al.* [30] and Fernandes *et al.* [31] reported that CBCT could be successful method in evaluation of root form. Fernandes *et al.* [31] evaluated three CBCT machine and digital periapical radiographs in evaluation of forty mandibular incisors in comparing with micro-CT. There was a high degree of accuracy for all selected methods about type I and type Ia root canal as well as type III. The oval canals were identified by the NewTom CBCT device in this study.

In the present study, the anatomical location of the tooth root (mesial or distal in mandibular molars, and mesiobuccal, distobuccal, or palatal in maxillary molars) did not considerably influence the detection of root canals.

In an *in vitro* study, Blattner *et al.* [25] evaluated the accuracy of CBCT in revealing the number of root canals and, specifically, MB2 canals in maxillary molars. They reported that the results obtained from CBCT examinations were

strongly consistent with the results obtained using the gold standard of the study, which was tooth sectioning [25]. Similar results were noticed from Domark *et al.* study [32] in comparison between CBCT and micro-CT.

With respect to delineating the root canal forms in the current study, CBCT ability was not influenced by jaw and root types, although tooth type had a small effect. CBCT was acceptably accurate in demonstrating the form of root canals in most tooth types, but was less accurate in the mandibular incisors. The small diameter of the incisor roots in the mandible and low contrast of the image of the root canal against the thickness of the root could be contributing factors for the lower level of accuracy of CBCT in revealing the root canal forms.

The agreement of CBCT and tooth clearing and staining in the detection of the number of root canals was excellent in the maxillary and good in the mandibular teeth. The lower agreement of the results in the mandibular teeth is perhaps due to the intermediate conformity of CBCT and tooth clearing in the mandibular incisors. CBCT and tooth clearing methods also showed good to excellent levels of agreement in displaying the root canal forms in both maxillary and mandibular teeth.

Although the agreement between CBCT and tooth clearing results was not flawless, the accuracy of CBCT in revealing both the number and form of the root canals was convincing enough to be considered as an additional diagnostic tool for the evaluation of the root canal system in the field of endodontics. Likewise, Matherne *et al.* [26] and Baratto *et al.* [14] pointed out the impact of CBCT on the improvement of the root canal morphology evaluation.

As most of the previously performed studies were limited to an evaluation of a specific root canal of the maxillary molar teeth, a broad comparison of our results with those of the available literature could not be conducted.

Conclusion

The present research revealed that CBCT displays root canal morphology with high accuracy owing to the creation of multi-planar images of the root structures. This technique is therefore recommended for improving the clinician's knowledge of the root canal morphology, which will undoubtedly result in more successful endodontic treatments.

Acknowledgment

We would like to acknowledge Ehsan Kazemnejad (Department of Biostatistics, Guilan University of Medical Sciences, Rasht, Iran) for his assistance in analyzing the statistical data.

Conflict of Interest: 'None declared'.

References

- Guo J, Vahidnia A, Sedghizadeh P, Enciso R. Evaluation of root and canal morphology of maxillary permanent first molars in a North American population by cone-beam computed tomography. *J Endod.* 2014;40(5):635-9.
- Neelakantan P, Subbarao C, Ahuja R, Subbarao CV, Gutmann JL. Cone-beam computed tomography study of root and canal morphology of maxillary first and second molars in an Indian population. *J Endod.* 2010;36(10):1622-7.
- Silva EJNL, Nejaim Y, Silva AI, Haiter-Neto F, Zaia AA, Cohenca N. Evaluation of root canal configuration of maxillary molars in a Brazilian population using cone-beam computed tomographic imaging: an in vivo study. *J Endod.* 2014;40(2):173-6.
- Huang Y-D, Wu J, Sheu R-J, Chen M-H, Chien D-L, Huang Y-T, Huang C-C, Chen Y-J. Evaluation of the root and root canal systems of mandibular first premolars in northern Taiwanese patients using cone-beam computed tomography. *J Formos Med Assoc.* 2015;114(11):1129-34.
- Yang L, Chen X, Tian C, Han T, Wang Y. Use of cone-beam computed tomography to evaluate root canal morphology and locate root canal orifices of maxillary second premolars in a Chinese subpopulation. *J Endod.* 2014;40(5):630-4.
- Yang H, Tian C, Li G, Yang L, Han X, Wang Y. A cone-beam computed tomography study of the root canal morphology of mandibular first premolars and the location of root canal orifices and apical foramina in a Chinese subpopulation. *J Endod.* 2013;39(4):435-8.
- Kim Y, Lee S-J, Woo J. Morphology of maxillary first and second molars analyzed by cone-beam computed tomography in a Korean population: variations in the number of roots and canals and the incidence of fusion. *J Endod.* 2012;38(8):1063-8.
- Pattanshetti N, Gaidhane M, Al Kandari A. Root and canal morphology of the mesiobuccal and distal roots of permanent first molars in a Kuwait population—a clinical study. *Int Endod J.* 2008;41(9):755-62.
- Sert S, Bayirli GS. Evaluation of the root canal configurations of the mandibular and maxillary permanent teeth by gender in the Turkish population. *J Endod.* 2004;30(6):391-8.
- Zheng Q-h, Wang Y, Zhou X-d, Wang Q, Zheng G-n, Huang D-m. A cone-beam computed tomography study of maxillary first permanent molar root and canal morphology in a Chinese population. *J Endod.* 2010;36(9):1480-4.
- Weine FS, Healey HJ, Gerstein H, Evanson L. Canal configuration in the mesiobuccal root of the maxillary first molar and its endodontic significance. *Oral Surg Oral Med Oral Pathol.* 1969;28(3):419-25.
- Zhang R, Yang H, Yu X, Wang H, Hu T, Dummer PMH. Use of CBCT to identify the morphology of maxillary permanent molar teeth in a Chinese subpopulation. *Int Endod J.* 2011;44(2):162-9.
- Lee J-H, Kim K-D, Lee J-K, Park W, Jeong JS, Lee Y, Gu Y, Chang S-W, Son W-J, Lee W-C. Mesiobuccal root canal anatomy of Korean maxillary first and second molars by cone-beam computed tomography. *Oral Surg Oral Med Oral Pathol Oral Radiol Endod.* 2011;111(6):785-91.
- Baratto Filho F, Zaitter S, Haragushiku GA, de Campos EA, Abuabara A, Correr GM. Analysis of the internal anatomy of maxillary first molars by using different methods. *J Endod.* 2009;35(3):337-42.
- Dankner E, Friedman S, Stabholz A. Bilateral C shape configuration in maxillary first molars. *J Endod.* 1990;16(12):601-3.
- Kottoor J, Velmurugan N, Sudha R, Hemamalathi S. Maxillary first molar with seven root canals diagnosed with cone-beam computed tomography scanning: a case report. *J Endod.* 2010;36(5):915-21.
- Vertucci FJ. Root canal morphology of mandibular premolars. *J Am Dent Assoc.* 1978;97(1):47-50.
- Awawdeh L, Abdullah H, Al-Qudah A. Root form and canal morphology of Jordanian maxillary first premolars. *J Endod.* 2008;34(8):956-61.
- Weine F, Hayami S, Hata G, Toda T. Canal configuration of the mesiobuccal root of the maxillary first molar of a Japanese subpopulation. *Int Endod J.* 1999;32(2):79-87.

20. Patel S, Dawood A, Whaites E, Pitt Ford T. New dimensions in endodontic imaging: part 1. Conventional and alternative radiographic systems. *Int Endod J*. 2009;42(6):447-62.
21. Naoum H, Love R, Chandler N, Herbison P. Effect of X-ray beam angulation and intraradicular contrast medium on radiographic interpretation of lower first molar root canal anatomy. *Int Endod J*. 2003;36(1):12-9.
22. Maret D, Peters OA, Galibourg A, Dumoncel J, Esclassan R, Kahn J-L, Sixou M, Telmon N. Comparison of the Accuracy of 3-dimensional Cone-beam Computed Tomography and Micro-Computed Tomography Reconstructions by Using Different Voxel Sizes. *J Endod*. 2014;40(9):1321-6.
23. Kim Y, Perinpanayagam H, Lee J-K, Yoo Y-J, Oh S, Gu Y, Lee S-P, Chang SW, Lee W, Baek S-H. Comparison of mandibular first molar mesial root canal morphology using micro-computed tomography and clearing technique. *Acta Odontol Scand*. 2015;73(6):427-32.
24. Ordinola-Zapata R, Bramante C, Versiani M, Moldauer B, Topham G, Gutmann J, Nuñez A, Duarte M, Abella F. Comparative accuracy of the Clearing Technique, CBCT and Micro-CT methods in studying the mesial root canal configuration of mandibular first molars. *Int Endod J*. 2017;50(1):90-6.
25. Blattner TC, George N, Lee CC, Kumar V, Yelton CD. Efficacy of cone-beam computed tomography as a modality to accurately identify the presence of second mesiobuccal canals in maxillary first and second molars: a pilot study. *J Endod*. 2010;36(5):867-70.
26. Matherne RP, Angelopoulos C, Kulild JC, Tira D. Use of cone-beam computed tomography to identify root canal systems in vitro. *J Endod*. 2008;34(1):87-9.
27. Han X, Yang H, Li G, Yang L, Tian C, Wang Y. A study of the distobuccal root canal orifice of the maxillary second molars in Chinese individuals evaluated by cone-beam computed tomography. *J Appl Oral Sci*. 2012;20(5):563-7.
28. Neelakantan P, Subbarao C, Subbarao CV. Comparative evaluation of modified canal staining and clearing technique, cone-beam computed tomography, peripheral quantitative computed tomography, spiral computed tomography, and plain and contrast medium-enhanced digital radiography in studying root canal morphology. *J Endod*. 2010;36(9):1547-51.
29. Hargreaves KM, Berman LH. Cohen's pathways of the pulp: Elsevier Health Sciences; 2015.
30. Michetti J, Maret D, Mallet J-P, Diemer F. Validation of cone beam computed tomography as a tool to explore root canal anatomy. *J Endod*. 2010;36(7):1187-90.
31. da Silva Ramos LMP, Rice D, Ordinola-Zapata R, Capelozza ALA, Bramante CM, Jaramillo D, Christensen H. Detection of Various Anatomic Patterns of Root Canals in Mandibular Incisors Using Digital Periapical Radiography, 3 Cone-beam Computed Tomographic Scanners, and Micro-Computed Tomographic Imaging. *J Endod*. 2014;40(1):42-5.
32. Domark JD, Hatton JF, Benison RP, Hildebolt CF. An ex vivo comparison of digital radiography and cone-beam and micro computed tomography in the detection of the number of canals in the mesiobuccal roots of maxillary molars. *J Endod*. 2013;39(7):901-5.

Please cite this Accuracy of Cone-Beam Computed Tomography in Comparison with Standard Method in Evaluating Root Canal Morphology: An *In Vitro* Study. *Iran Endod J*. 2018;13(2):181-7. *Doi:* 10.22037/iej.v13i2.18614.