



Comparative Accuracy of Cone-Beam Computed Tomography and Clearing Technique in Studying Root Canal and Apical Morphology of Mandibular Canines

Mandana Naseri^a , Zohreh Ahangari^a , Nastaran Bagheri^b , Sanaa Jabbari^c , Atefeh Gohari^{a*}

^a Department of Endodontics, School of Dentistry, Shahid Beheshti University of Medical Sciences, Tehran, Iran; ^b Private Practice, Tehran, Iran; ^c Department of Endodontics, School of Dentistry, Alborz University of Medical Sciences, Alborz, Iran

ARTICLE INFO

Article Type: Original Article

Received: 12 Mar 2019

Revised: 25 Jun 2019

Accepted: 06 Jul 2019

Doi: 10.22037/iej.v14i4.25127

*Corresponding author: Atefeh Gohari, Department of Endodontics, School of Dentistry, Shahid Beheshti University of Medical Sciences, Evin, Tehran, Iran.

Tel: +98-912 8077586

E-mail: atp.gohari@gmail.com

© The Author(s). 2018 Open Access This work is licensed under the terms of the Creative Commons Attribution-NonCommercial-ShareAlike 4.0 International.

ABSTRACT

Introduction: Knowledge about root canal anatomy improves the long-term prognosis of endodontic treatment. This study aimed to investigate the accuracy of cone-beam computed tomography (CBCT) in assessment of morphology of root canal and apex in mandibular canines compared with the clearing technique. **Methods and Material:** In this *in vitro* study, 33 extracted mandibular canines were subjected to CBCT with 0.1 mm voxel size. Number and type of canals, prevalence of accessory canals, anastomosis, apical delta and distance from apical constriction (AC) to apical foramen (AF) and to anatomic apex (AA) and also distance from AF to the AA were determined on CBCT scans. After access cavity preparation, a #8 K file was passed through the main apical foramen. Its direction and distance from anatomic apex was determined under a stereomicroscope. After clearing and staining of teeth, other criteria were determined with stereomicroscope under 16× magnification and served for comparison with CBCT data. The agreement of two methods were evaluated by intra-class correlation and kappa coefficients for quantitative and qualitative data, respectively. **Results:** Most (93.9%) canine teeth were Vertucci's type I, followed by type III configuration in both CBCT and clearing techniques. The results of both techniques were not in agreement for assessment of accessory canals, however acceptable agreement was noted between them for detection of apical delta and also assessment of apical foramen deviation in buccolingual and mesiodistal directions. Both of two techniques had excellent agreement for evaluating the distances from AF to AA, AC to AF and AC to AA. **Conclusions:** CBCT is a reliable tool in assessment of root canal and apical topography in mandibular canines, however its use in accessory canal detection is not recommended.

Keywords: Canine Tooth; Clearing Technique; Cone-Beam Computed Tomography; Tooth Apex

Introduction

The most favorable outcomes of endodontic treatment are achieved through mechanical and chemical preparation of root canals and subsequently, efficient obturation. Adequate knowledge of the root canal system is therefore required, because routine preoperative radiography which is commonly used as an intra-operative tool for examining internal anatomy *in vivo*, shows a two-dimensional (2D) image and has the drawback of superimposition of anatomical structures on images [1]. Also, 2D radiographs are not reliable for assessment of the number of root

canals [2], also cannot well visualize the details of the root canal system such as anatomic apex (AA) [the tip of the root, the farthest part from the occlusal table], apical foramen (AF) [the point at which the root canal exits the root and faces the periodontal ligament, It does not necessarily coincide with AA] and apical constriction (AC) [the part of the root canal with the smallest diameter and is considered as the reference point for clinicians for apical termination limit in enlargement, cleaning, disinfection and filling procedures] [3]. Since accurate estimation of working length is not possible without knowledge about these three landmarks, clinicians must have adequate knowledge in this regard [4].



Figure 1. Clearing technique revealed mandibular canine teeth with Vertucci's type III canal configuration

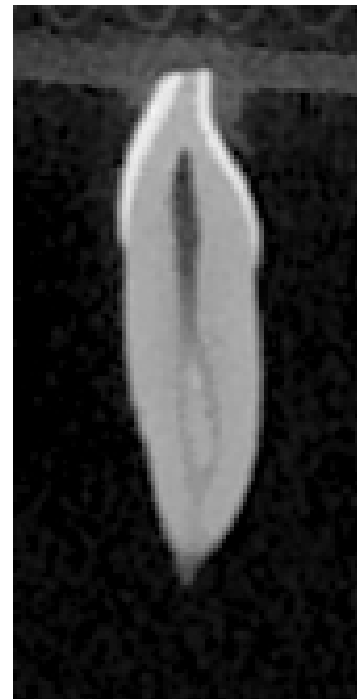


Figure 2. CBCT scan revealed mandibular canine teeth with Vertucci's type III canal configuration

There are several methods for investigating the root canal morphology: cross-sectioning [4], conventional radiography [5], cone-beam computed tomography (CBCT) [6], micro-CT [7] and clearing and staining methods [8, 9]. The clearing technique followed by staining and assessment under a stereomicroscope is a highly accurate technique to study morphological variations in extracted teeth [10]. This method as well as micro CT is commonly used as one of the most accurate *in vitro* methods [11]. Computed tomography (CT) was first used in endodontics by Tachibana [12]. This method is suitable for assessment of root canals since it enables scanning and 3D reconstruction of images [6]. However, in order to use CBCT with confidence *in vitro* and *in vivo*, a reliable agreement must exist between this method and the clearing and staining technique.

Studies using clearing and staining techniques have discussed that the position of apical foramen in almost half of mandibular canine teeth matches anatomic apex; however, in case of mismatch, reports regarding the location of apical foramen are conflicting [10, 13, 14]. The prevalence of accessory canals (tiny narrow canals extending in any direction from the pulp canal to the periodontium), apical delta (formed when the main canal divides into several canals in the apical region) and anastomoses (known as isthmuses, are inter-canal communications within the same root) are also variable in

different studies [10, 15-17]. In all previous studies, Vertucci's canal configuration type I [18] was the most common type in mandibular anterior teeth [14, 16, 19] but no consensus has been reached on its frequency of other tooth types.

This study aimed to assess the apical and canal morphology of mandibular canines using both clearing technique and CBCT scans, followed by comparing their effectiveness in identifying these criteria.

Materials and Methods

This *in vitro* study was conducted on mandibular canine teeth extracted for periodontal reasons in dental clinics in Tehran, Iran. It was approved by ethics committee of Shahid Beheshti University of Medical Sciences (Ethical number: IR.SBMU.RIDS.RES.1394.30) and had been conducted in full accordance with the World Medical Association Declaration of Helsinki. All patients, from whom the teeth were extracted, signed a written consent form.

The inclusion criteria were teeth with mature apices, no or minimal caries and no restoration, root fracture or apical resorption. The exclusion criteria were teeth stored in unsuitable conditions in terms of temperature or moisture, teeth with root canal calcification and history of previous endodontic treatment. A total of 33 canine teeth were selected using convenience sampling.




Figure 3. Cleared and stained mandibular canine tooth under a stereomicroscope at 16× magnification and 0.01 mm accuracy showing the presence of apical delta

The teeth were immersed in 1% sodium hypochlorite solution (Golrang Co., Pakshou, Tehran, Iran) for two days, debris and tissue residues were removed and were then stored in 0.9% normal saline until the experiment.

The teeth were placed upside down on a red wax sheet measuring 5×5 cm and the CBCT scans were taken using NewTom VGI (QR S.R.L., Verona, Italy) with 110 kVp, high resolution with a field of view of 6 cm×6 cm and 0.1 mm voxel size. Volumetric reconstruction was performed using multiplanar reformatting (MPR), cross sections and multiplanar features of NNT viewer software version 3.0 (QR SRL, Verona, Italy). Directing the deviation of apical foramen from anatomic apex in buccolingual and mesiodistal dimensions was assessed in coronal and sagittal plans, respectively. Determination of number and type of canals, presence of accessory canals, apical deltas and anastomoses was determined by assessing serial axial and sagittal and cross-sectional sections from the pulp chamber to the apex. The morphology of root apex was also examined in coronal and sagittal plans. All CBCT examinations were performed by two calibrated researchers (a radiologist and an endodontist). In case of any disagreement, a consultation with another radiologist was done.

Access cavities were then prepared using #2 round bur (Ecodent, Rosdorf, Germany) and a tapered fissure bur (Ecodent, Rosdorf, Germany) with high speed handpiece (Kavo, Biberach, West Germany). A #8 K-file (Mani, Tochigi, Japan) was placed in the root canal and the direction of apical foramen deviation from anatomic apex in buccolingual and mesiodistal dimensions and also distance from AF to AA were recorded under a stereomicroscope LTD (SZX-1LLB200, Olympus,

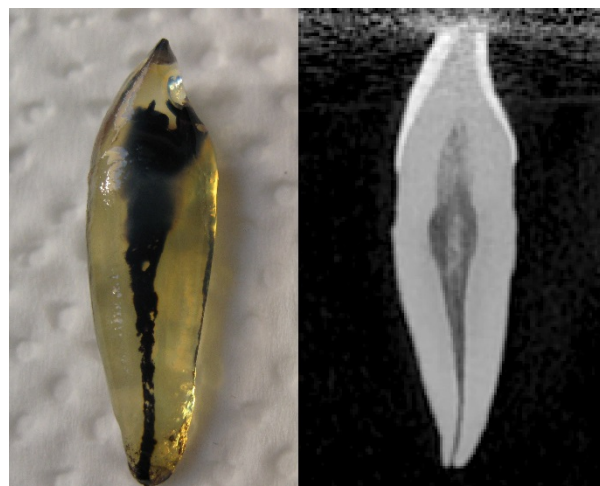


Figure 4. Cone-beam computed tomography and clearing technique were in an acceptable agreement for determination of canal type and the number of canals in mandibular canine teeth

Tokyo, Japan) under 16× magnification and 0.01 mm accuracy using its respective software (Olympia Zoom 3.2).

The teeth were then immersed in 1% sodium hypochlorite (Golrang Co., Pakshou, Tehran, Iran) for one day in order to dissolve debris and remaining pulp tissue and were then rinsed under running tap water for four h. For demineralization, the teeth were soaked in 5% nitric acid (Shiraz Petrochimie, Shiraz, Iran) for 2-3 days [20]. The solution was refreshed daily and to control complete demineralization, the teeth were examined by an explorer and radiographically compared (Skydent, New York, USA) with intact teeth. After rinsing them under running water for another four h, dehydration was performed using 70, 80 and 96% ethyl alcohol (Razi, Ahvaz, Iran) for 36 h. Then the clearing process was performed by immersion of teeth in methyl salicylate (Merck Millipore, Darmstadt, Germany) for two h. Using ink (Pelican Co., Tehran, Iran) injected into the canal through the access cavity by a 30 gauge needle (Supa, Tehran, Iran) under 25 mmHg negative pressure, staining was completed. Number of canals, canal type according to Vertucci's classification [18], presence/absence of accessory canals, anastomoses, apical delta and distance from AC to AF and AA were all determined under a stereomicroscope (SZX-1LLB200, Olympus, Tokyo, Japan) under 16× magnification and 0.01 mm accuracy. This procedure was done by an experienced endodontist.

Data were analyzed using SPSS version 22 (SPSS Inc., Chicago, IL, USA). Quantitative and qualitative data were analyzed using the mean and frequency values. The intra-class correlation coefficient (ICC) and kappa coefficients were used for assessment of quantitative and qualitative data to ensure reliability of CBCT results, respectively. The ICC values of 0<0.39 interpreted as poor, 0.40-0.74 as adequate, and 0>0.75 as

excellent. These values are believed to be the minimum standards for reliability coefficients adequate for research purposes [21].

Results

Vertucci type I was the most prevalent canal type in mandibular canine teeth (93.9%) followed by type III (6.1%) and no other types were seen at all. Apical delta was seen in 9 teeth (27.3%), but no accessory canal or anastomosis was noted in any tooth (Table 1).

Table 2 shows the prevalence and direction of AF deviation from AA in both buccolingual and mesiodistal dimensions.

Totally, 14 (42.4%) teeth had no deviation in buccolingual and mesiodistal directions.

The mean distances between AF, AA and AC are shown in Table 3.

As the same results of CBCT, results obtained from clearing technique showed that Vertucci's type I was the most common canal type of mandibular canine teeth (90.9%; $n=30$) and three teeth were type III (9.1%) (Table 1, Figures 1 and 2). A single canal was present in 90.9% ($n=30$); three teeth (9.1%) had two canals. Eight teeth (24%) had accessory canals and all the others (76%) did not. Apical delta was seen in 10 teeth (30.3%) (Figure 3) and no anastomosis was noted in any tooth.

Table 1. The prevalence of number of canals, canal type, accessory canals, anastomoses and apical delta obtained by CBCT imaging compared with clearing technique

		CBCT N (%)	Clearing N (%)	Kappa*/ Crude**
Canal type	I	31(93.9)	30(90.9)	0.78*
	III	2(6.1)	3(9.1)	
Canal number	1	31(93.9)	30(90.9)	0.79*
	2	2(6.1)	3(9.1)	
Accessory canals	Presence	0(0)	8(24)	75.75**
	Absence	33(100)	25(76)	
Anastomosis	Presence	0(0)	0(0)	97%**
	Absence	33(100)	33(100)	
Apical delta	Presence	9(27.3)	10(30.3)	0.63*
	Absence	24(72.7)	23(69.7)	
Total		33(100)	33(100)	

* Kappa coefficient for agreement >0.6 shows acceptable agreement between two techniques; **Crude agreement coefficient (starred) is used when the kappa coefficient for agreement could not be calculated since one parameter is 0

Table 2. The prevalence and direction of deviation of apical foramen from anatomic apex in both buccolingual and mesiodistal dimensions in mandibular canines, obtained from CBCT imaging compared with clearing technique

		CBCT N (%)	Clearing N (%)	Kappa
Buccolingual	No deviation	14(42.4)	12(36.3)	0.81
	Buccal	15(54.5)	21(63.6)	
	Lingual	1(3)	0(0)	
Mesiodistal	No deviation	14(42.4)	15(45.5)	0.67
	Mesial	11(33.3)	13(39.4)	
	Distal	8(24.2)	5(15.2)	
Total		33(100)	33(100)	

* Kappa coefficient for agreement

Table 3. Apical foramen to anatomic apex, apical constriction to apical foramen and apical constriction to anatomic apex mean distances determined by CBCT imaging compared with clearing technique

	CBCT Technique			Clearing Technique			ICC*	95% CI** for ICC	
	Mean (SD)	Min	Max	Mean (SD)	Min	Max		Min	Max
Apical foramen to anatomic apex	0.47 (0.43)	0	1.6	0.39 (0.38)	0	1.5	0.759	0.516	0.880
Apical constriction to apical foramen	0.55 (0.499)	0	1.8	0.72 (0.51)	0	1.7	0.805	0.580	0.906
Apical constriction to anatomic apex	0.92 (0.491)	0.1	2	0.94 (0.51)	0	1.8	0.871	0.737	0.936

* Intra-class correlation coefficient (ICC): used for the assessment of quantitative data to ensure reliability of CBCT results in comparison with clearing and staining technique; the amounts of $ICC > 0.75$ show excellent reliability and $0.40 < ICC < 0.75$ shows good reliability; **Confidence Interval

Table 2 shows that 12 teeth (36.3%) had no apical deviation in buccolingual direction, while 21 (63.6%) had buccal deviation. No case of lingual deviation was noted. Among of 33 teeth, 15 (45.5%) had no deviation in mesiodistal direction; 13 (39.4%) had mesial and 5 (15.2%) had distal deviations. The mean distances between AF, AA and AC are shown in Table 3.

Comparison of CBCT results and the results obtained from clearing technique

The kappa coefficient for agreement between the two methods for canal type and the number of canals was found to be 0.78 and 0.79, respectively which were both acceptable ($0 > 0.6$) (Figure 4).

The crude agreement coefficient between the two methods for accessory canals was 75.75%. Sensitivity of CBCT for detection of accessory canals in canine teeth was 0%, its positive predictive value was 0% and its negative predictive value was 100%. Therefore, the reliability of CBCT is not sufficient for accessory canals detection.

The kappa coefficient for agreement between the two methods for assessment of anastomosis could not be calculated since none of the teeth had anastomosis but crude agreement coefficient was found to be 97%.

The kappa coefficient for agreement between the two methods for assessment of apical delta was found to be 0.63, which expresses the agreement between two methods (Table 1). This number was found to be 0.87 and 0.67 for assessment of deviation of apical foramen in buccolingual and mesiodistal directions, respectively which were both acceptable (Table 2).

The ICC for agreement between the two methods for assessment of distances from AA to AF, AC to AF and AC to AA was found to be 0.76, 0.81 and 0.87, respectively. CBCT showed an excellent reliability in the assessment of AA to AF, AC to AF and AC to AA distances (Table 3).

Discussion

This study aimed to assess the morphology of root canal and all the criteria of apical area in mandibular canine teeth by clearing technique and CBCT scans and found that CBCT was not a reliable tool for assessment of accessory canals, but it was suitable for detection of apical delta and assessment of deviation of AF in buccolingual and mesiodistal directions in canine teeth. Additionally, CBCT was excellent for assessment of distance from AF to AA, AC to AF and AC to AA.

Clearing technique and micro-CT have the highest accuracy among *in vitro* techniques for assessment of morphology of root canals and apex [11, 22]. However, these techniques can only be used *in vitro* but their results can be beneficial for use in the clinical setting [23, 24]. One study showed that determination of

canal configuration was significantly affected by the evaluation method, micro-CT was more accurate in the detection of root canal morphology of mandibular mesial roots than CBCT [25].

Due to high cost and unavailability of micro-CT, we used clearing and staining technique as the classic standard in our study to assess the reliability of CBCT results, since the clearing technique is highly accurate [9]. Easy access, allowing adjustment of resolution and size of region of interest, acceptably high accuracy and no image distortion are among the benefits of CBCT. Due to these advantages, it was suggested as an alternative to the clearing technique for *in vitro* studies, as the latter one is technique sensitive and time consuming. CBCT can help in detection of type and shape of canals [23, 24]. Although it is theoretically accurate, voxel size must be taken into account. Voxel sizes smaller than 300 μm are adequate for assessment of hard tissue and root canal anatomy [26]. In the current study CBCT scans were taken with 100 μm voxel size. Kobayashi concluded that CBCT was accurate enough for linear measurement of anatomical landmarks [27]. However, resolution must be adjusted based on the required accuracy [28]. Neelakantan [12] compared number of canals measured on CBCT scans and clearing technique and stated that CBCT was an efficient non-invasive technique for assessment of root canal anatomy and has an accuracy similar to that of clearing technique. In assessment of canal types I and III, the results of CBCT match those of micro-CT and CBCT is more accurate than digital radiographs taken at two different angles [29].

In this study, we adopted the simple *in vitro* technique to take CBCT scans of teeth without using any contrast in the canal or around the roots. Also, the teeth were first decalcified and dehydrated and were then stained during clearing process. This method has advantages; for instance, the ink is not washed off during the process of clearing, also penetration of dye into main and accessory canals can be clearly seen by operator. Moreover, decalcification opens some calcified accessory canals and increases the accuracy of this assessment [9].

The results showed canine teeth were mostly type I canal of Vertucci's classification, type III was only seen in three teeth, and other types were not seen at all. The results of CBCT and clearing technique were in agreement with each other in this respect. Type I had a prevalence of about 93.9%, which was in line with the results of previous studies and type III showed the prevalence of 6.1%, close to the 2-7% value reported earlier [9, 19, 30]. In terms of number of canals, 93.9% of samples had a single canal and the remaining had two canals. The results of CBCT were in line with those of clearing technique, which indicates that CBCT was reliable for this assessment. Previous studies showed similar agreement between CBCT and clearing technique in this regard [31, 32].

According to the results of CBCT, accessory canals had 0% prevalence, however this value was found to be 24% by clearing technique. As a result, CBCT does not have adequate accuracy for assessment of accessory canals in canine teeth. This result was in agreement with those reported by Khademi *et al.* [33]. However, one study showed high-resolution scan mode of CBCT could accurately identify and locate lateral and accessory canals [34]. Anastomosis was not seen in any tooth in our study, as a result kappa coefficient for agreement between the two methods for assessment of it could not be calculated.

Apical delta was seen in 30.3% of cases in our study and CBCT was found to be suitable for its detection. However, the value obtained in our study was higher than that reported by Vertucci [19] and almost similar to the value reported by Sert and Bayirli [9].

Position of apical foramen was also investigated in the present study. Both methods showed buccal deviation as the highest frequency, followed by central position and lingual deviation in buccolingual direction. In mesiodistal direction, foramen was mainly at the center of apex, followed by mesial and then distal deviations. The results of CBCT matched those of clearing technique in this regard and thus CBCT can be reliably used for assessment of foramen position relative to apex. Burch and Hulen [35] also reported that buccal deviation of AF relative to the AA had the highest frequency, in contrast to Martos *et al.* [14] reporting the central position as the most common one. However, they both assessed anterior teeth altogether and not only canine teeth. Blaskovic-Subat [36] reported the lowest prevalence of deviation of AF relative to AA in mandibular canine teeth. Detection of foramen deviation is important in that it cannot be detected on 2D radiographs taken during endodontic treatment and in case of presence of deviation in buccolingual direction, correct determination of working length cannot be done merely based on radiography.

The distance from AF to AA on CBCT scans was 0.47 mm in our study, which was close to the values reported by Martos *et al.* [14] and Dummer *et al.* [15]. CBCT and clearing technique results matched in this respect and thus CBCT can be used for this measurement. Also, the mean distance from AC to AF on CBCT scans was found to be 0.55, with excellent agreement with that of clearing technique. Citterio *et al.* [37] using micro CT reported this distance to be 0.72 mm and Kuttler [4] reported it 0.5 to 1.5 mm. In the present study, distance from AC to AA was 0.87 mm and 0.92 mm by CBCT and clearing technique, respectively. The agreement was excellent between the two methods. Dummer *et al.* [15] reported the value to be 0.79 mm for canine teeth, which was close to our obtained one.

In general, controversy in values reported in different studies highlights the role of genetics and importance of ethnic

background in tooth morphology. Also, difference in age and gender of patients may also be responsible for these variations. Aging is associated with continued deposition of cementum, which can alter the distance between AF and AA [38]. Chronic stimulations and trauma to teeth can as well cause ectopic calcifications in the root canal or pulp chamber. Last but not least, different methodologies and *in vitro* or *in vivo* design of the studies significantly affect the results.

Conclusion

Vertucci type I was the most prevalent canal type in mandibular canine teeth (93.9%) followed by type III. Both methods showed buccal deviation as the highest frequency, followed by central position and lingual deviation in buccolingual direction. In mesiodistal direction, foramen was mainly at the center of apex, followed by mesial and then distal deviations.

Within the limitations of this study, the results showed that CBCT was not suitable for assessment of accessory canals but can be reliably used for detection of apical delta and of apical foramen deviation from anatomic apex in mandibular canine teeth. Additionally, it has an excellent reliability in assessment of distances between apical constriction, anatomic apex and apical foramen.

Acknowledgment

This article was based on an undergraduate thesis by Nastaran Bagheri which was successfully completed under the supervision of Dr Mandana Naseri by Dental School of Shahid Beheshti University of Medical Sciences.

Conflict of Interest: 'None declared'.

References

1. Patel S. New dimensions in endodontic imaging: Part 2. Cone beam computed tomography. *Int Endod J.* 2009;42(6):463-75.
2. Nattress BR, Martin DM. Predictability of radiographic diagnosis of variations in root canal anatomy in mandibular incisor and premolar teeth. *Int Endod J.* 1991;24(2):58-62.
3. Ricucci D, Langeland K. Apical limit of root canal instrumentation and obturation, part 2. A histological study. *Int Endod J.* 1998;31(6):394-409.
4. Kuttler Y. Microscopic investigation of root apices. 1955. *J Indiana Dent Assoc.* 2010;89(1):20-8.
5. Pineda F, Kuttler Y. Mesiodistal and buccolingual roentgenographic investigation of 7,275 root canals. *Oral Surg Oral Med Oral Pathol.* 1972;33(1):101-10.
6. Bulut DG, Kose E, Ozcan G, Sekerci AE, Canger EM, Sisman Y. Evaluation of root morphology and root canal configuration of premolars in the Turkish individuals using cone beam computed

- tomography. *Eur J Dent.* 2015;9(4):551-7.
7. Grande NM, Plotino G, Gambarini G, Testarelli L, D'Ambrosio F, Pecci R, Bedini R. Present and future in the use of micro-CT scanner 3D analysis for the study of dental and root canal morphology. *Ann Ist Super Sanita.* 2012;48(1):26-34.
 8. Singh S, Pawar M. Root canal morphology of South asian Indian mandibular premolar teeth. *J Endod.* 2014;40(9):1338-41.
 9. Sert S, Bayirli GS. Evaluation of the root canal configurations of the mandibular and maxillary permanent teeth by gender in the Turkish population. *J Endod.* 2004;30(6):391-8.
 10. von Arx T. Frequency and type of canal isthmuses in first molars detected by endoscopic inspection during periradicular surgery. *Int Endod J.* 2005;38(3):160-8.
 11. Sert S, Aslanalp V, Tanalp J. Investigation of the root canal configurations of mandibular permanent teeth in the Turkish population. *Int Endod J.* 2004;37(7):494-9.
 12. Neelakantan P, Subbarao C, Subbarao CV. Comparative evaluation of modified canal staining and clearing technique, cone-beam computed tomography, peripheral quantitative computed tomography, spiral computed tomography, and plain and contrast medium-enhanced digital radiography in studying root canal morphology. *J Endod.* 2010;36(9):1547-51.
 13. Tachibana H, Matsumoto K. Applicability of x-ray computerized tomography in endodontics. *Endod Dent Traumatol.* 1990;6(1):16-20.
 14. Martos J, Lubian C, Silveira LF, Suita de Castro LA, Ferrer Luque CM. Morphologic analysis of the root apex in human teeth. *J Endod.* 2010;36(4):664-7.
 15. Dummer PM, McGinn JH, Rees DG. The position and topography of the apical canal constriction and apical foramen. *Int Endod J.* 1984;17(4):192-8.
 16. Al-Qudah AA, Awawdeh LA. Root canal morphology of mandibular incisors in a Jordanian population. *Int Endod J.* 2006;39(11):873-7.
 17. Soleymani A, Namaryan N, Moudi E, Gholinia A. Root Canal Morphology of Mandibular Canine in an Iranian Population: A CBCT Assessment. *Iran Endod J.* 2017;12(1):78-82.
 18. Vertucci FJ. Root canal anatomy of the human permanent teeth. *Oral Surg Oral Med Oral Pathol.* 1984;58(5):589-99.
 19. Vertucci FJ. Root canal anatomy of the mandibular anterior teeth. *J Am Dent Assoc.* 1974;89(2):369-71.
 20. Robertson D, Leeb IJ, McKee M, Brewer E. A clearing technique for the study of root canal systems. *J Endod.* 1980;6(1):421-4.
 21. Fleiss J. The design and analysis of clinical experiments. 1986.
 22. Szabo BT, Pataky L, Mikusi R, Fejerdy P, Dobo-Nagy C. Comparative evaluation of cone-beam CT equipment with micro-CT in the visualization of root canal system. *Ann Ist Super Sanita.* 2012;48(1):49-52.
 23. Michetti J, Maret D, Mallet JP, Diemer F. Validation of cone beam computed tomography as a tool to explore root canal anatomy. *J Endod.* 2010;36(7):1187-90.
 24. Milanezi de Almeida M, Bernardineli N, Ordinola-Zapata R, Villas-Boas MH, Amoroso-Silva PA, Brandao CG, Guimaraes BM, Gomes de Moraes I, Hungaro-Duarte MA. Micro-computed tomography analysis of the root canal anatomy and prevalence of oval canals in mandibular incisors. *J Endod.* 2013;39(12):1529-33.
 25. Ordinola-Zapata R, Bramante CM, Versiani MA, Moldauer BI, Topham G, Gutmann JL, Nunez A, Duarte MA, Abella F. Comparative accuracy of the Clearing Technique, CBCT and Micro-CT methods in studying the mesial root canal configuration of mandibular first molars. *Int Endod J.* 2017;50(1):90-6.
 26. Maret D, Peters OA, Galibourg A, Dumoncel J, Esclassan R, Kahn JL, Sixou M, Telmon N. Comparison of the accuracy of 3-dimensional cone-beam computed tomography and micro-computed tomography reconstructions by using different voxel sizes. *J Endod.* 2014;40(9):1321-6.
 27. Kobayashi K, Shimoda S, Nakagawa Y, Yamamoto A. Accuracy in measurement of distance using limited cone-beam computerized tomography. *Int J Oral Maxillofac Implants.* 2004;19(2):228-31.
 28. Bauman R, Scarfe W, Clark S, Morelli J, Scheetz J, Farman A. Ex vivo detection of mesiobuccal canals in maxillary molars using CBCT at four different isotropic voxel dimensions. *Int Endod J.* 2011;44(8):752-8.
 29. Paes da Silva Ramos Fernandes LM, Rice D, Ordinola-Zapata R, Alvares Capelozza AL, Bramante CM, Jaramillo D, Christensen H. Detection of various anatomic patterns of root canals in mandibular incisors using digital periapical radiography, 3 cone-beam computed tomographic scanners, and micro-computed tomographic imaging. *J Endod.* 2014;40(1):42-5.
 30. Rahimi S, Shahi S, Yavari HR, Reyhani MF, Ebrahimi ME, Rajabi E. A stereomicroscopy study of root apices of human maxillary central incisors and mandibular second premolars in an Iranian population. *J Oral Sci.* 2009;51(3):411-5.
 31. Mokhtari H, Niknami M, Mokhtari Zonouzi HR, Sohrabi A, Ghasemi N, Akbari Golzar A. Accuracy of Cone-Beam Computed Tomography in Determining the Root Canal Morphology of Mandibular First Molars. *Iran Endod J.* 2016;11(2):101-5.
 32. Dalili Kajan Z, Taramsari M, Khosravi Fard N, Kanani M. Accuracy of Cone-beam Computed Tomography in Comparison with Standard Method in Evaluating Root Canal Morphology: An In Vitro Study. *Iran Endod J.* 2018;13(2):181-7.
 33. Khademi A, Mehdizadeh M, Sanei M, Sadeqnejad H, Khazaei S. Comparative evaluation of root canal morphology of mandibular premolars using clearing and cone beam computed tomography. *Dent Res J (Isfahan).* 2017;14(5):321-5.
 34. Ji Y, Wen S, Liu S, Zhu M, Yao M, Wang T, Lin Z. Could cone-beam computed tomography demonstrate the lateral accessory canals? *BMC Oral Health.* 2017;17(1):142.
 35. Burch JG, Hulen S. The relationship of the apical foramen to the anatomic apex of the tooth root. *Oral Surg Oral Med Oral Pathol.* 1972;34(2):262-8.
 36. Blaskovic-Subat V, Maricic B, Sutalo J. Asymmetry of the root canal foramen. *Int Endod J.* 1992;25(3):158-64.
 37. Citterio F, Pellegatta A, Citterio CL, Maddaloni M. Analysis of the apical constriction using micro-computed tomography and anatomical sections. *Giornale Italiano di Endodonzia.* 2014;28(1):41-5.
 38. Altunsoy M, Ok E, Nur BG, Aglarci OS, Gungor E, Colak M. A cone-beam computed tomography study of the root canal morphology of anterior teeth in a Turkish population. *Eur J Dent.* 2014;8(3):302-6.

Please cite this paper as: Naseri M, Ahangari Z, Bagheri N, Jabbari S, Gohari A. Comparative Accuracy of Cone-Beam Computed Tomography and Clearing Technique in Studying Root Canal and Apical Morphology of Mandibular Canines. *Iran Endod J.* 2019;14(4): 271-7. *Doi:* 10.22037/iej.v14i4.25127.