

Original Article

A comparative study on colposcopy directed biopsy and Pap smear tests in patients with an abnormal Pap smear

Farideh Dadkhah, Nahid Alishah

Dept. Gynecology, Iran Univ. Med. Sci., Tehran

ABSTRACT

Objective: Since colposcopy biopsy test plays a significant role in the evaluation of cervix, especially in patients with an abnormal result of Pap smear test, therefore, this research study was conducted to compare the results of Pap smear and colposcopy directed punch biopsy tests at Firoozgar and Akbarabady hospitals from 2001 to 2003.

Materials and Methods: This cross-sectional study was carried out on 80 conveniently-sampled women at different ages with an abnormal result of Pap smear test. In this respect, colposcopy directed biopsy was taken from suspicious areas of these patients.

Results: A positive predictive value equal to 67.5% was found in patients with an abnormal result of Pap smear and colposcopy directed biopsy tests which confirmed the reliability of the study.

Conclusion: These findings strongly suggest the necessity to obtain cervicovaginal smears from all sexually active women and for this purpose colposcopy directed biopsy is the best choice for evaluation of patients with an abnormal result of Pap smear test.

Key words: Atypical Squamous Cells of Undetermined Significance, Cervical Intraepithelial Neoplasia, Squamous Cell Carcinoma, Colposcopy, Punch Biopsy

Introduction

Invasive squamous cell carcinoma is a rare cancer nowadays due to the development of advanced screening tests including Pap smear and colposcopy directed biopsy in women. On this basis, precancerous lesions including low- and high-grade squamous intraepithelial ones

(LSIL and HSIL respectively) can be diagnosed on time and appropriately treated. Therefore, a lower rate of morbidity and mortality exists for cervical cancer(1). In this respect, a majority of women diagnosed as having invasive cervical carcinoma do not often receive routine screening tests. In this research study, patients with an

Received: 29 December 2005

Accepted: 15 February 2006

*Address communications to: F. Dadkhah Dept. Gynecology, Iran university med.sci-Tehran- Iran
E-mail:blinding.brightness@gmail.com

abnormal result of Pap smear referred to Ob-Gyn clinics of Firoozgar and Akbarabady hospitals were evaluated. In addition, cytology slides were requested for women with abnormal Pap smears from other laboratories to be re-evaluated by pathologists of these hospitals. On condition of not obtaining these slides, another Pap smear was taken during colposcopy and those cases that SCJ could not be observed were excluded from the study.

Materials and Methods

In this study, 80 patients with abnormal Pap smears including atypical squamous cells of undetermined significance (ASCUS), LSIL, HSIL, and invasive carcinoma were evaluated by colposcopy. For this purpose, patients were laid in litotomy position and normal saline moistened sterile speculum was inserted. Primary observation of the smears was performed with low magnification (X5) to enhance the view of the entire cervix and vagina. Then, after application of acetic acid (3%) to the cervix, this region was re-evaluated with high magnification (X40). After performing cervical biopsy (the so-called punch biopsy) on the aceto-white and suspicious areas, the fixative-preserved specimen was sent for further pathological evaluation.

Colposcopic findings(2,3):

Aceto-white epithelium: Acetic acid does not affect mature colposcopic findings.

Acetowhite Epithelium: Acetic acid does not affect the mature glycogen-producing epithelium, because the acid does not penetrate below the upper 1/3 of the epithelium. The cells in this region have very small nuclei and a large amount of glycogen (not protein). These areas appear pink during colposcopy. Displasic cells which are most affected, turn to white. They contain large nuclei with abnormally large amount of chromatin (protein). The columnar villi become plumper, therefore SCJ become easier to be observed. They appear slightly white, particularly in the presence of metaplasia.

The immature metaplastic cells have large nuclei and also show some effects of acetic acid, but they are not as white or opaque as CIN, but

instead appear gray and filmy.

Punctuation: This term refers to dilated capillaries terminating on the surface which appear from the ends as a collection of dots. When these vessels occur in a well-demarcated area of aceto-white epithelium, they indicate an abnormal epithelium, most often CIN.

Mosaic pattern: Terminal capillaries surrounding roughly circular or polygonal shaped blocks of aceto-white epithelium crowded together are called mosaic, because their appearance is similar to mosaic tile. Mosaic pattern tends to be associated with higher-grade lesions, i.e. CIN2 and CIN3.

Atypical vascular pattern: These patterns are characteristic of invasive cervical cancer and include looped vessels, branching vessels, and reticular vessels.

Leukoplakia: This is a white epithelial plaque, visible before application of acetic acid. A layer of keratin on the surface of epithelium causes it. Keratin production is abnormal in cervicovaginal mucosa. Several factors can cause leukoplakia including HPV, keratinizing CIN, keratinizing carcinoma, chronic trauma from diaphragm, pessary, or tampon, and radiotherapy. Such areas should undergo biopsy to rule out keratinizing carcinoma.

Colposcope: This device is a binocular microscope with a built-in light source and a converging objective lens attached to a supporting appliance. It provides magnification and illumination for colposcopic assessment of the target tissue. Low power magnification (X2-X6) is used for examination of the vulva, vagina, and cervix. High power magnification (X15-X40) is especially helpful when assessing the fine detail of vessel patterns. The green filter absorbs certain wavelengths of light, making the red color of the vessel appear blacker and sharpening the contrast with the surrounding epithelium.

Results

From the 80 patients studied in this research, about %86.3 were educated under diploma of High school, non-smokers; the marital age of

%94 was under 20 & %20 under 14 years.
 %95 were multi para & %5 nulli para, & vaginal spotting was their most common complaint.
 The mean age of patients was 43.5 years; & the prevalence age of ASCUS was 30-34, LSIL 45-49 years, HSIL 45-49 years, & SCC 50-59 years old. (Figure 1)

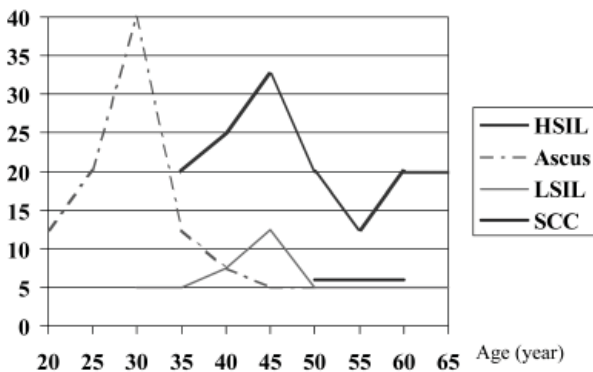


Fig.1: Frequency of age based on diagnosis

The patients' most common contraception methods were OCP & WD.

- In 32 patients (%40), ASCUS was found in Pap-Smears, but the Biopsy results showed %68.8 normal, %18.8 CIN1 & %12.5 CIN2.
- In 10 patients (%12.5), LSIL was found in Pap-Smears, but the biopsy results showed %20 Normal, %60 CIN1 & %20 CIS.
- In 34 patients, (%42.5), HSIL was found in Pap-Smears, but the biopsy results showed %5.9 Normal, %5.9 CIN1, %23.5 CIN2, 17.6 CIN3, 23.5 CIS & %23.5 SCC.
- In 4 patients (%5), SCC was found in Pap-Smears, & all were proved in Colposcopy results. (Figure 2,3)

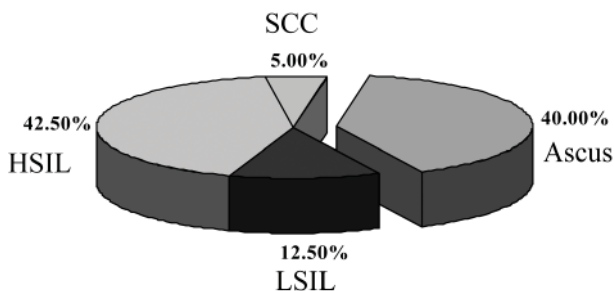


Fig.2: Results of pap smears

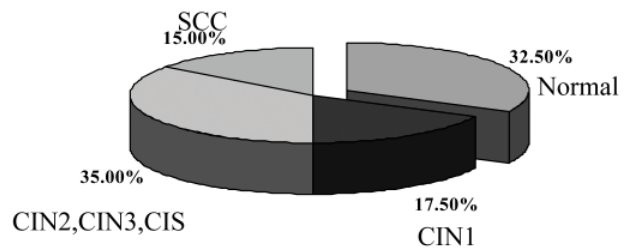


Fig.3: Results of colposcopy

Discussion

The necessity of performing colposcopy directed biopsy in patients with abnormal Pap. Smears is evidenced by the amount of %10-%20 progression of CIN1, %30 progression of CIN2, & up to %70 progression of CIN3 to higher stages(2).

On the basis of this comparative research, cytological diagnosis of ASCUS is associated with an incidence of %18.8 CIN1, %12.5 CIN2 in colposcopy biopsy; since the option of repeat Pap. Testing is weakened by %20-%50 false negative rate in identifying CIN lesions as well as the noncompliance of the patients, therefore immediate colposcopy is assumed to be the most reliable method(4).

It is also mentioned in Novak 2002; "immediate colposcopy is assumed to be the most sensitive method of detecting CIN2 or CIN3(5).

Based on a meta-analysis of 84 appropriately designed & conducted studies, the Agency for Health Care Policy & Research reported that conventional cytology has a specificity of 98% & a sensitivity of 51%(1).

In an article (*J. pediatric adolescence gynecology,2001*)It is mentioned that from 51 abnormal Pap. smears, 15% Normal, 29.4% CIN1, 25.5% CIN2 & 2% CIN3 were detected in colposcopy-biopsy. Therefore it is suggested that both Pap.smear & colposcopy-biopsy are essential in diagnosis & treatment of cervical lesions(6).

Conclusion

1. Pap. Smear should be performed annually on all women from the beginning of sexual activity, & be considered by a pathologist.

2. According to the *Positive Predictive Value* of 67.5% in our study, it is recommended to perform Colposcopy directed biopsy immediately in all patients with abnormal Pap. Smears.
3. All Gynecology residents must be trained to apply colposcope.

References

1. Rubin S.C: Cervical cancer & Preinvasive Neoplasia, Philadelphia, Lippicott Raven Publisher, 1995. P 115-125
2. Barabara S. Apgar, Gregory L. Brotzman : Abnormal Transformation Zone.in: Brabara S. Apgar,MarkSpitzer,GregoryL. Brotzman,editors; Colposcopy Principals & Practice (An Integrated Text Book & Atlas). Philadelphia, Pensilvania, W SAUNDERS COMPANY; 2002. P 173-186,249
3. Rubin M.: Follow-up Of An Abnormal Pap. Test & Colposcopy. In Wallis LA editor.Textbook Of Women's Health; New York, Little Brown, 1997. P. 901
4. Ellen E. Sheets. Cervix.in: GeoffGreenwood; St. Louis,editors Kistener's Gynecology: Missouri: Mosby, 1999. P.102-109
5. Keneth D. Hatch, Jonathan S. Berek. Intraepithelial Disease of The Cervix.in: Jonathan S. Berek editors.Novak's Gynecology. Philadelphia, Lippincott Williams & Wilkins, 2002. P. 471-480
6. Hassan EA, Creatas GK, H.C . Colposcopy Directed Biopsy Finding In The Young Female. Journal Pediatric Adolescent Gynecology 2001 Feb, 14(1):35-38