

Original Article

Inflammatory Pseudotumor of the Orbit: A Histopathologic and Immunohistochemical Study of 32 Cases

Fahimeh Asadi-Amoli¹, Farnoosh Azadbakht¹, Easa Jahanzad¹,
Ali Sadeghie-Tari¹, Mojgan Akbarzadeh-Jahromi¹

1. Department of Pathology, Cancer Institute of Imam-Khomeini Hospital, Tehran, Iran.

ABSTRACT

Background and Objective: Inflammatory pseudotumor is a lesion composed of proliferating spindle cells with mixed inflammatory infiltrates. Some authors have proposed the name inflammatory myofibroblastic tumor as a proper descriptive term rather than the vague inflammatory pseudotumor. The aim of this study was to verify the myofibroblastic origin of spindle cells in idiopathic orbital inflammatory pseudotumor by immunohistochemical staining.

Materials and Methods: We reviewed a series of 32 inflammatory pseudotumors arising in orbit for expression of smooth muscle actin, vimentin, desmin and anaplastic lymphoma kinase using immunohistochemical staining.

Results: There were 21 females and 11 males aged 3 to 64 years with a mean age of 31.

Immu-nohistochemically, spindle cells of 51.75%, 79.3%, and 17.2% of lesions expressed smooth muscle actin (15/29), vimentin (23/29) and desmin (5/29). All lesions (32/32) were negative for anaplastic lymphoma kinase

Conclusion: In this study, reactivity for smooth muscle actin in spindle cells can be demonstrated as myofibroblastic differentiation. The absence of anaplastic lymphoma expression in all cases of orbital inflammatory pseudotumor in this study strongly suggests that these lesions, albeit histologically similar, are biologically distinct from their soft tissue counterparts or those inflammatory myofibroblastic tumor that negative for anaplastic lymphoma immunoreactivity may be characterized by one or more chromosomal aberration involving regions other than 2p23 is as yet unknown.

Key words: Inflammatory pseudotumor, Orbit, ALK kinase

Received: 27 May 2008

Accepted: 9 August 2008

Address communications to: Dr. Farnoosh Azadbakht, Department of Pathology, Cancer Institute of Imam-Khomeini Hospital, Tehran, Iran.

Email: azadbakht@razi.tums.ac.ir

Introduction

Idiopathic inflammatory pseudotumor (IPT) of the orbit or eye is a rare, benign and self-limited disorder (1-4). These tumors most commonly arise in the lungs and abdomen, but they have been reported in virtually all anatomic subsets of the body in patients of all ages (5). In the head and neck, the orbit is the most common site of occurrence (5). Its pathogenesis is unknown.

The diagnostic entity “inflammatory pseudotumor” has undergone something of a revolution in recent years. What was once a heterogeneous group of poorly defined entities has been refined, and it presently encompasses several distinct biologic processes including both reactive condition as well as neoplasm (6-9). Some authors have proposed the name “inflammatory myofibroblastic tumor” as a proper descriptive term for this tumor, rather than the vague “inflammatory pseudotumor. Inflammatory myofibroblastic tumor (IMT) is a lesion composed of proliferating myofibroblastic spindle cells with mixed inflammatory infiltrates of lymphocytes, plasmacells, eosinophils and histiocytes (10).

Histopathologic discrimination of these lesions may require careful attention not only to the histopathologic findings but also to clinical course and to additional diagnostic tools, particularly immunocytochemistry. The neoplastic nature of IMT was confirmed by proving the presence of clonal abnormalities in the short arm of chromosome 2 (2;3;6-8) involving the anaplastic lymphoma kinase (ALK) gene. Resultant ALK protein over-expression in myofibroblastic cells was found out in 35% to 60% of IMT cases, suggesting neoplastic nature of these tumors rather than a reactive or reparative process (6-8). However, the concept of the same lesions in orbit was not changed and was still referred to as “inflammatory pseudotumor” (IPT) but in a few case reports used term “inflammatory myofibroblastic pseudotumor” when myofibroblasts were rich in the mass. We consider that they are the same lesion that occurs in the other soft tissue and suggest that they be referred to in unison as IMT.

To verify the histopathology and immunohistochemi-

stry for myofibroblastic differentiation and ALK expression of orbital IPT, we analyzed clinicopathologic features and performed SMA, vimentin, desmin and ALK immunohistochemistry on 32 cases of orbital IPT.

Materials and Methods

Thirty two cases of orbital inflammatory pseudotumor were selected from the histopathology files of the Department of Pathology at the Farabi hospital between 1991 and 2007. Clinical information (age and sex of the patient, site and side of the lesion) was obtained from the pathology report.

Hematoxylin and Eosin-stained slides were reviewed in all cases. All cases met the established light microscopic histopathologic criteria for orbital inflammatory pseudotumor (11). Formalin-fixed, paraffin-embedded sections were available in all cases. Immunohistochemical staining was performed using a conventional labeled streptavidin-biotin method according to the manufacturer’s protocol. Briefly, 4 μ m tissue sections were placed on silanecoated slides, deparaffinized, and rehydrated with graded ethanol and phosphate-buffered saline. After antigen retrieval by microwaves blocking endogenous peroxidase, goat serum to prevent nonspecific reaction and primary antibodies were applied sequentially. The primary antibodies (Table 1) used were as follows: SMA (n = 29; DAKO, dilution 1:100), vimentin (n = 29; DAKO, dilution 1:100), desmin (n = 29; DAKO, dilution 1:100) and ALK-1 protein (n = 32; DAKO, dilution 1:250). These slides were incubated in biotinylated goat anti-mouse immunoglobulin and then in a solution of streptavidin-biotin complex. Immunoreactivity was visualized using 3,3-diaminodenzidine (DAB).

Reaction was interpreted as positive if a distinct precipitate was present in cytoplasm of the spindle cells. The positive control for ALK-1 was an anaplastic large cell lymphoma, which showed a diffuse cytoplasmic positivity. Positive reaction of α -SMA with or without vimentin or desmin was considered as myofibroblastic differentiation.

Table 1: Immunohistochemical antibodies

Antigen retrieval	Dilution	Source	Antibody (clone)
Microwave	1:100	DAKO	SMA
Microwave	1:100	DAKO	Vimentin
Microwave	1:100	DAKO	Desmin
Microwave	1:250	DAKO	ALK-1

Results

Clinical features

The patients' mean age was 31 years (ranging from 3 to 64 years) and females were affected more often than males (1.9/1). Tumor side varied and included the right (n = 15, 46.9%) and left (n = 17, 53.1%). The most common presentation was proptosis followed by pain and swelling.

Gross and microscopic findings

The lesions were unilateral (n = 30) or bilateral (n = 2) ranging in size from 0.3 to 4 cm (mean 1.37 cm) and having gray-white to creamy-brown color.

Microscopically, all cases were composed of spindle cells, a variable fibrocollagenous stroma, and inflammatory cells component made up lymphocytes, plasmacells, histiocytes, neutrophils and eosinophils. The proportion of each of these elements varied between cases, as well as within cases. Other histopathological findings including perivascular lymphocytic infiltration, fat necrosis, lymphoid follicle formation myositis and dacryoadenitis variably were also seen in some cases. The spindle cells had a long and eosinophils cytoplasm without cross-striation (Fig. 1). Mitosis and coagulative necrosis was not present. Type of lesions is summarized in Table 2.

Table 2: Type of idiopathic orbital inflammatory pseudotumor

Type	Frequency	Percent (%)
Acute	3	9.4
Subacute	13	40.6
Chronic	15	46.9
Chronic sclerosing	1	3.1

Immunohistochemical findings

The spindle cells were immunoreactive for alpha smooth muscle actin (SMA) in 15 out of 29 cases (Fig. 2) and vimentin in 23 out of 29 cases, 51.7%

and 79.3%, respectively. Thirty two out of 32 cases studied were negative for the ALK-1 protein (Table 3).

Table 3: Antibodies and immunohistochemical results

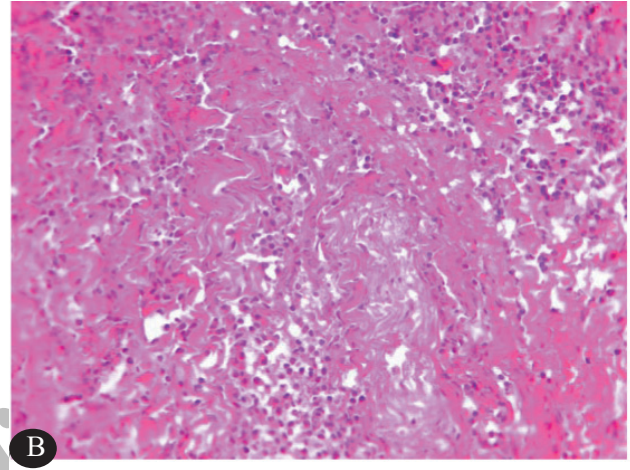
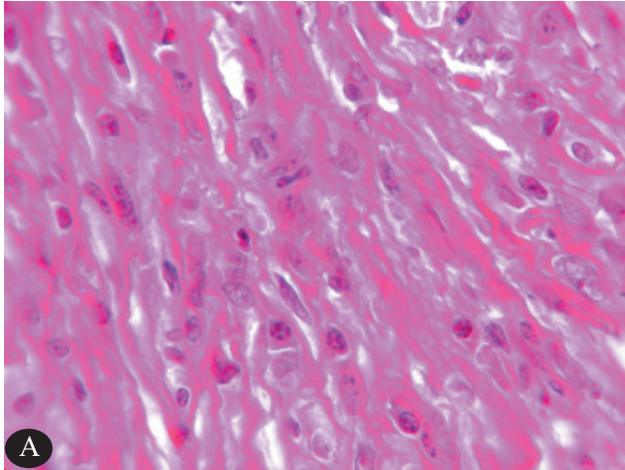
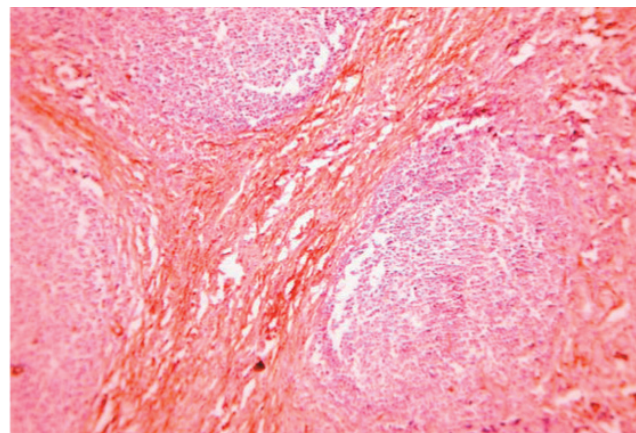
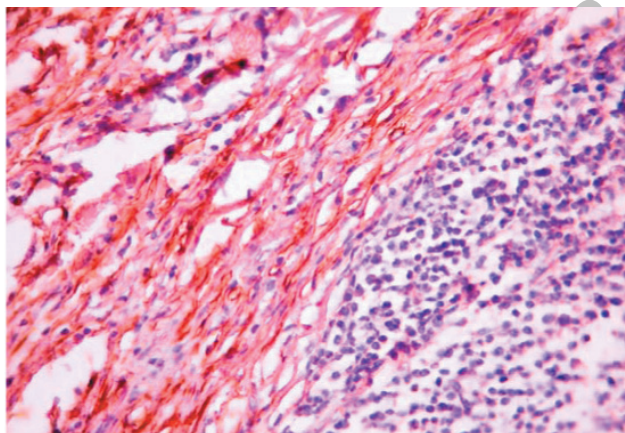
Antibody	Number of stained cases	Percent of positive test (number)
SMA- α	29	51.7% (15)
Vimentin	29	79.3% (23)
Desmin	29	17.2% (5)
SMA & Vimentin- α	29	44.8% (13)
SMA & Desmin- α	29	6.9% (2)
SMA & Desmin & Vimentin- α	29	3.4% (1)
Desmin & Vimentin	29	17.2% (5)
SMA or vimentin	29	86.2% (25)
ALK	32	0% (0)

Comparison of immunohistochemical results in different microscopic types of orbital inflammatory

pseudotumor is summarized in Table 4.

Table4: Comparison of immunohistochemical results in different microscopic types of idiopathic orbital inflammatory pseudotumor

Type	Frequency	SMA	Vimentin	Desmin	SMA & Vimentin
Acute	3	2 (50%)/1	1/2 (50%)	0/1 (0%)	1/2 (50%)
Subacute	13	8/13 (61.5%)	9/13 (69.2%)	1/13 (7.7%)	6/13 (46.2%)
Chronic	15	6/13 (46.2%)	12/13 (92.3%)	3/13 (23.1%)	6/13 (46.2%)
Chronic sclerosing	1	0/1 (0%)	1/1 (100%)	1/1 (100%)	0/1 (0%)

**Fig.1: (A & B) inflammatory pseudotumor of orbit. The lesion composed of spindle cells admixed with inflammatory infiltrated cells ($\times 100$ & $\times 400$).****Fig.2. Spindle immunoreactivity for SMA (smooth muscle actin) (Avidin-biotin peroxidase; $\times 100$ & $\times 400$). Note the follicle formation of inflammatory cells.**

Discussion

Despite many studies, the nature of IPT has remained a curious lesion. It was originally described in the lung and called plasmacell granuloma (12). The term inflammatory myofibroblastic tumor commonly referred to as inflammatory pseudotumor in the earlier literature (13) and implies for myofibroblastic differentiation, which is supported by immunohistochemical and ultrastructural data. IMT

is a neoplastic process that can arise in many sites within the head and neck including orbit (14-16). The histological features of this tumor vary slightly from site to site, which may at least in part, be related to the differences in the phase of the lesion's development at the time the lesion becomes symptomatic or detectable. The histopathologic examination is essential to the diagnosis of IMT. Microscopically, IMTs are composed of proliferating spindle cells, a variably

prominent collagenous stroma and a background of inflammatory cells consists mainly of lymphocytes and plasma cells. Immunohistochemical staining is useful in confirmation of the myofibroblastic phenotype (17-20).

Our immunohistochemical findings for myofibroblastic differentiation are similar to other authors (8;21-29). Immunohistochemically, most of the spindle cells showed evidence of myofibroblastic differentiation, as 15/29 cases stained for smooth muscle actin and 23 out of 29 cases stained for desmin, in contrast to the findings of Facchetti et al that most spindle cells were positive for vimentin and macrophages-associated markers (30) and by Selves et al that is derived from follicular dendritic reticulum cells (FDRC) (31). Some IMTs may exhibit aggressive local behavior and rarely metastasis (32) and some of them do not respond to conventional treatments (corticosteroids) which point to the possibility that at least some subsets of IMTs are in fact true neoplasm (6;7).

Recent cytogenetic and molecular studies have identified abnormalities of chromosome 2p23 (short arm of chromosome 2 at the region p21-p23, the site of the ALK gene that codes for a tyrosin kinase receptor) (7;33-36). In IMTs immunohistochemistry for ALK-1, P80 is useful as an indicator of 2p23 abnormality and the sensitivity of both antibodies are known to be comparable (8). ALK immunoreactivity has been reported in 36% to 60% of IMT (7;8;14;26;29;33;36;37). ALK-1 reactivity lends support to the diagnosis of IMT and its neoplastic feature. Thirty two cases of orbital IPT were obtained from our files. Immunohistochemistry for ALK receptor kinase expression did not detect ALK kinase expression (0 out of 32). This finding is in sharp contrast to that of Lawrence et al (34) who showed strong ALK kinase expression by immunohistochemistry in 7 out of 11 cases of soft tissue IMT, Coffin et al (7) who reported 12 out of 45 cases of IMT positive for ALK kinase and other studies (7;8;14;26;29;33;36;37). Further support for the absence of ALK expression in some IPTs comes from a study by Neuhauser et al who found no ALK expression in 10 out of 10 cases of splenic IPT (23), Jeffery et al that none of their 13 cases of splenic and lymph node IPT showed ALK expression (38) and other studies (18). Several studies have proposed a role for EBV (23;39) and HHV8 (39;40). One of two case reports of orbital IMT shows ALK expression (28) and another study shows no immunoreactivity for ALK (18). So, the absence of ALK expression in

all cases of orbital IPT in this study and most others orbital IMT studies strongly suggests that these lesions, albeit histologically similar, are biologically distinct from their soft tissue and should be considered histopathologic and clinical information and those IMTs that are negative for ALK immunoreactivity may be characterized by one or more chromosomal aberration involving regions other than 2p23 is as yet unknown counterparts.

Conclusion

Although ALK immunoreactivity clearly does not distinguish between a reactive and a neoplastic process, it is possible that FISH analysis for ALK gene alteration might be useful in distinguishing those lesions that are truly neoplastic from those that are reactive.

References

1. Uy HS, Nguyen QD, Arbour J, Gravel M, D'Amico DJ, Jakobiec FA, et al. Sclerosing inflammatory pseudotumor of the eye. *Arch Ophthalmol* 2001 Apr;119(4):603-7.
2. Thorne JE, Volpe NJ, Wulc AE, Galetta SL. Caught by a masquerade: sclerosing orbital inflammation. *Surv Ophthalmol* 2002 Jan;47(1):50-4.
3. Sarker A, An C, Davis M, Praprotnik D, McCarthy LJ, Orazi A. Inflammatory pseudotumor of the spleen in a 6-year-old child: a clinicopathologic study. *Arch Pathol Lab Med* 2003 Mar;127(3):e127-e130.
4. Bahadori M, Liebow AA. Plasma cell granulomas of the lung. *Cancer* 1973 Jan;31(1):191-208.
5. Fletcher C, Unni K, Mertens F. Pathology and Genetics, Tumors of Soft Tissue and Bone. World Health Organization Classification of Tumors. 337:a2295. doi: 10.1136/bmj.a2295. ed. Lyon: IARC Press; 2002.
6. Cook JR, Dehner LP, Collins MH, Ma Z, Morris SW, Coffin CM, et al. Anaplastic lymphoma kinase (ALK) expression in the inflammatory myofibroblastic tumor: a comparative immunohistochemical study. *Am J Surg Pathol* 2001 Nov;25(11):1364-71.
7. Coffin CM, Patel A, Perkins S, Elenitoba-Johnson KS, Perlman E, Griffin CA. ALK1 and p80 expression and chromosomal rearrangements involving 2p23 in inflammatory myofibroblastic tumor. *Mod Pathol* 2001 Jun;14(6):569-76.
8. Cessna MH, Zhou H, Sanger WG, Perkins SL, Tripp S, Pickering D, et al. Expression of ALK1 and

p80 in inflammatory myofibroblastic tumor and its mesenchymal mimics: a study of 135 cases. *Mod Pathol* 2002 Sep;15(9):931-8.

9. Brooks J, Mills S, Carter D, Greenson J, Oberman H. *Sternberg's Diagnostic Surgical Pathology*. 4 ed. Philadelphia: 2004.

10. Jeon YK, Chang KH, Suh YL, Jung HW, Park SH. Inflammatory myofibroblastic tumor of the central nervous system: clinicopathologic analysis of 10 cases. *J Neuropathol Exp Neurol* 2005 Mar;64(3):254-9.

11. Yanoff M, Fine B. *Ocular pathology*. 5 ed. London: Mosby- Wolf; 2002.

12. Coffin CM, Humphrey PA, Dehner LP. Extrapulmonary inflammatory myofibroblastic tumor: a clinical and pathological survey. *Semin Diagn Pathol* 1998 May;15(2):85-101.

13. Pettinato G, Manivel JC, De RN, Dehner LP. Inflammatory myofibroblastic tumor (plasma cell granuloma). Clinicopathologic study of 20 cases with immunohistochemical and ultrastructural observations. *Am J Clin Pathol* 1990 Nov;94(5):538-46.

14. Coffin CM, Hornick JL, Fletcher CD. Inflammatory myofibroblastic tumor: comparison of clinicopathologic, histologic, and immunohistochemical features including ALK expression in atypical and aggressive cases. *Am J Surg Pathol* 2007 Apr;31(4):509-20.

15. Misselevitch I, Podoshin L, Fradis M, Naschitz JE, Yeshurun D, Boss JH. Inflammatory pseudotumor of the neck. *Otolaryngol Head Neck Surg* 1991 Dec;105(6):864-7.

16. Narla LD, Newman B, Spottswood SS, Narla S, Kolli R. Inflammatory pseudotumor. *Radiographics* 2003 May;23(3):719-29.

17. Wenig BM, Devaney K, Bisceglia M. Inflammatory myofibroblastic tumor of the larynx. A clinicopathologic study of eight cases simulating a malignant spindle cell neoplasm. *Cancer* 1995 Dec 1;76(11):2217-29.

18. Sa HS, Ji JY, Suh YL, Kim YD. Inflammatory myofibroblastic tumor of the orbit presenting as a subconjunctival mass. *Ophthal Plast Reconstr Surg* 2005 May;21(3):211-5.

19. Harik LR, Merino C, Coindre JM, Amin MB, Pedeutour F, Weiss SW. Pseudosarcomatous myofibroblastic proliferations of the bladder: a clinicopathologic study of 42 cases. *Am J Surg Pathol* 2006 Jul;30(7):787-94.

20. Vadmal MS, Pellegrini AE. Inflammatory myofibroblastic tumor of the skin. *Am J Dermatopathol* 1999 Oct;21(5):449-53.

21. Coffin CM, Watterson J, Priest JR, Dehner LP. Extrapulmonary inflammatory myofibroblastic tumor (inflammatory pseudotumor). A clinicopathologic and immunohistochemical study of 84 cases. *Am J Surg Pathol* 1995 Aug;19(8):859-72.

22. Goldblum J. Myofibroblastic Proliferations of the Genitourinary Tract: Reactive Pseudosarcomatous Proliferations or Inflammatory Myofibroblastic Tumors? *Adv Anat Pathol* 2006;13(6):332.

23. Neuhauser TS, Derringer GA, Thompson LD, Fanburg-Smith JC, Aguilera NS, Andriko J, et al. Splenic inflammatory myofibroblastic tumor (inflammatory pseudotumor): a clinicopathologic and immunophenotypic study of 12 cases. *Arch Pathol Lab Med* 2001 Mar;125(3):379-85.

24. Mentzel T, Dry S, Katenkamp D, Fletcher CD. Low-grade myofibroblastic sarcoma: analysis of 18 cases in the spectrum of myofibroblastic tumors. *Am J Surg Pathol* 1998 Oct;22(10):1228-38.

25. Sastre-Garau X, Couturier J, Derre J, Aurias A, Kljanienko J, Lagace R. Inflammatory myofibroblastic tumour (inflammatory pseudotumour) of the breast. Clinicopathological and genetic analysis of a case with evidence for clonality. *J Pathol* 2002 Jan;196(1):97-102.

26. Nonaka D, Birbe R, Rosai J. So-called inflammatory myofibroblastic tumour: a proliferative lesion of fibroblastic reticulum cells? *Histopathology* 2005 Jun;46(6):604-13.

27. Ahmad SM, Tsirbas A, Kazim M. Inflammatory myofibroblastic tumour of the orbit in a 7-year-old child. *Clin Experiment Ophthalmol* 2007 Mar;35(2):160-2.

28. O'Malley DP, Poulos C, Czader M, Sanger WG, Orazi A. Intraocular inflammatory myofibroblastic tumor with ALK overexpression. *Arch Pathol Lab Med* 2004 Jan;128(1):e5-e7.

29. Biselli R, Boldrini R, Ferlini C, Boglino C, Inserra A, Bosman C. Myofibroblastic tumours: neoplasias with divergent behaviour. Ultrastructural and flow cytometric analysis. *Pathol Res Pract* 1999;195(9):619-32.

30. Facchetti F, De Wolf PC, De WI, Frizzera G. Inflammatory pseudotumor of lymph nodes. Immunohistochemical evidence for its fibrohistiocytic nature. *Am J Pathol* 1990 Aug;137(2):281-9.

31. Selves J, Meggetto F, Brousset P, Voigt JJ, Pradere B, Grasset D, et al. Inflammatory pseudotumor of the liver. Evidence for follicular dendritic reticulum cell proliferation associated with clonal Epstein-Barr virus. *Am J Surg Pathol* 1996 Jun;20(6):747-53.

32. Hedlund GL, Navoy JF, Galliani CA, Johnson WH, Jr. Aggressive manifestations of inflammatory pulmonary pseudotumor in children. *Pediatr Radiol* 1999 Feb;29(2):112-6.

33. Griffin CA, Hawkins AL, Dvorak C, Henkle C, Ellingham T, Perlman EJ. Recurrent involvement of 2p23 in inflammatory myofibroblastic tumors. *Cancer Res* 1999 Jun 15;59(12):2776-80.

34. Lawrence B, Perez-Atayde A, Hibbard MK, Rubin BP, Dal CP, Pinkus JL, et al. TPM3-ALK and TPM4-ALK oncogenes in inflammatory myofibroblastic tumors. *Am J Pathol* 2000 Aug;157(2):377-84.

35. Yousem SA, Shaw H, Cieply K. Involvement of 2p23 in pulmonary inflammatory pseudotumors. *Hum Pathol* 2001 Apr;32(4):428-33.

36. Su LD, Atayde-Perez A, Sheldon S, Fletcher JA, Weiss SW. Inflammatory myofibroblastic tumor: cytogenetic evidence supporting clonal origin. *Mod Pathol* 1998 Apr;11(4):364-8.

37. Rabban JT, Zaloudek CJ, Shekitka KM, Tavassoli FA. Inflammatory myofibroblastic tumor of the uterus: a clinicopathologic study of 6 cases emphasizing distinction from aggressive mesenchymal tumors. *Am J Surg Pathol* 2005 Oct;29(10):1348-55.

38. Kutok JL, Pinkus GS, Dorfman DM, Fletcher CD. Inflammatory pseudotumor of lymph node and spleen: an entity biologically distinct from inflammatory myofibroblastic tumor. *Hum Pathol* 2001 Dec;32(12):1382-7.

39. Arber DA, Kamel OW, van de RM, Davis RE, Medeiros LJ, Jaffe ES, et al. Frequent presence of the Epstein-Barr virus in inflammatory pseudotumor. *Hum Pathol* 1995 Oct;26(10):1093-8.

40. Gomez-Roman JJ, Sanchez-Velasco P, Ocejudo-Vinyals G, Hernandez-Nieto E, Leyva-Cobian F, Val-Bernal JF. Human herpesvirus-8 genes are expressed in pulmonary inflammatory myofibroblastic tumor (inflammatory pseudotumor). *Am J Surg Pathol* 2001 May;25(5):624-9.

Archive of SID