

Original Article

Evaluation of Cyclin D1 Expression in Esophageal Squamous Cell Carcinoma and its Effect on Response Rate to Neo- adjuvant Chemoradiotherapy

Mohammad-Reza Ghavam Nassiri¹, Fatemeh Varshoe Tabrizi¹, Fatemeh Homaei Shandiz²,
Mohammad Khagedaloe³, Kamran Ghafarzadegan⁴

1. Dept. of Radiation Oncology, Mashhad University of Medical Sciences, Mashhad, Iran
2. Cancer Research Center, Mashhad University of Medical Sciences, Mashhad, Iran
3. Dept. of Epidemiology, Mashhad University of Medical Sciences, Mashhad, Iran
4. Dept. of Pathology, Mashhad University of Medical Sciences, Mashhad, Iran

ABSTRACT

Background and Objective: Esophageal cancer especially squamous cell carcinoma (SCC) is one of the most common gastro intestinal malignancies in north part of Iran (Khorasan). The standard treatment for esophageal cancer is surgical resection, but its outcome remains poor. Then, the oncologists try to treat this cancer with sandwich protocols especially neo-adjuvant chemo-radiotherapy. Several studies have reported that over expression of Cyclin D1 is a negative prognostic factor and is correlated with poor response to chemo-radiotherapy and decrease of survival. For this reason we evaluated Cyclin D1 expression in patients with esophageal SCC and its effect on response rate to neo- adjuvant chemo-radiotherapy in north-east Iran.

Materials and Methods: We analyzed Cyclin D1 expression by immunohistochemistry in 37 endoscopic biopsies of esophageal SCC from April 2004 to March 2005 in Mashhad University of Medical Science, Iran and compared it with clinical and pathologic response rate to neo adjuvant chemo radiotherapy.

Results: Cyclin D1 over expression was detected in 24 patients (64.9%). Nine patients with Cyclin D1 over expression had pathologic complete response (37.5%) as compared with 9 patients with negative cyclin D1 expression (69.2%) ($P=0.09$).

Conclusion: Cyclin D1 is a useful tumor marker to select patients may not be suitable for neo-adjuvant chemo-radiotherapy and it is better to refer them for surgery or definitive radiotherapy.

Key words: Esophagus, Squamous cell carcinoma, Cyclin D1, Neoadjuvant Therapies

Introduction

Esophageal cancer especially squamous cell carcinoma (SCC) is one of the most gastro intestinal

malignancies in northern Iran (Khorasan). Although esophageal adenocarcinoma is more common in Western countries but in east of Turkey, north of Iran and China, Esophageal squamous cell carcinoma

Received: 13 April 2009

Accepted: 13 August 2009

Address communications to: Dr Fatemeh Homaei-Shandiz, Omid Hospital, Alandast Sq., Mashhad, Iran

Email: homaeif@yahoo.com

(ESCC) is more common (1). Presently, the standard treatment for esophageal cancer is surgical resection, but its outcome remains poor (1, 2).

The rationale for tri-modality therapy, chemo-radiotherapy followed by surgery, is based on the pattern of both local and distant failure associated with surgery alone and chemo-radiotherapy without surgery, which are two treatment options established as standard of care based on data from randomized controlled trials (1).

Recent evidence has suggested that Cyclin D1 gene amplification might be involved in the development of specialized protein that bind to and activate cyclin depended kinase (CDK) molecules, which lead to phosphorylation of target proteins regulating the cell cycle. Over expression of Cyclin D1 has been identified in approximately 30% of patients with Barrett's esophagus or esophageal squamous cell carcinoma (1, 3, 4).

In multiple studies, Cyclin D1 over expression is a predictor of poor out come and is correlated with regional and distant metastases, high tumor grade and stage, poor response to chemo-radiotherapy and decreased overall survival (1, 3-7).

In the current study, we examined Immunohistochemically endoscopic biopsy specimens of esophageal SCC in order to find out Cyclin D1 over expression frequency and then evaluated pathologic response rate in surgical specimens after preoperative chemo-radiotherapy and correlation of Cyclin D1 over expression and poor response to neo- adjuvant chemo-radiotherapy.

Patients and Methods:

Thirty seven patients (20 males and 17 females, range 32 – 75y, and median age 57y) with confirmed ESCC treated from April 2004 to March 2005 by pre operative chemo-radiotherapy and followed by curative esophagectomy at Omid and Imam Reza Hospitals of Mashhad University of Medical Science, Iran. All patients had been examined by gastrointestinal endoscope, barium swallow, chest x- ray and liver sonography. None of patients was metastatic; all patients had pathologic biopsies to confirm diagnosis of esophageal SCC. We reviewed all the endoscopic biopsies and investigated Cyclin D1 expression by immunohistochemistry in these

specimens.

All 37 patients received preoperative concurrent chemo-radiotherapy. Chemotherapy regimen prescribed in this form: cisplatin 25 mg/ m² on day 1-3 day and 5FU 500 mg/ m² on day 1-3 day bolus for 1 or two cycles. All patients received external beam radiation by Co 60 or 9MV x- ray (linear accelerator, Nepton) using the conventional fractionated irradiation. The irradiated volume included the gross tumor with a safety margin of 5cm both proximally and distally. Treatment was given through two opposed field (anterior – posterior and posterior – anterior) with daily fraction 2 Gy, 5days pre week to total dose 30-40 Gy in 15-20 fractions over 3-4 weeks. Definite trans- hiatal escophagectomy was undertaken 3 week after chemo-radiotherapy.

We also examined all pathologic surgical specimens after preoperative chemo-radiation for rate of complete response.

Immunohistochemical staining method:

Biopsy and surgical specimens were fixed in 40 gr/ L formal dehyde and embedded in paraffin wax. Five – micron section cut from each specimen, dewaxed in xylene, rehydrated through grading concentration of ethanol were immersed in 3% hydrogen proxide to block the endogenous peroxidase and washed in phosphate buffered saline. For Cyclin D1 immunohistochemical staining, tissue sections were heated in 10 mmol/L sodium citrate (pH 6.0). In a microwave oven for 10 min to expose the antigens, and, then, treated with normal goat serum (10%) before slaining to reduce specific antibody binding. Tissue sections were incubated overnight. Cyclin D1 stating was conducted with the following antibody: mouse monoclonal anti Cyclin D1 anti body (Novo castra laboratories Ltd. UK) at 1: 20 dilution. The sections were then washed and incubated with biotinylated goat anti- rabbit IgG (Vector laboratories, Burlingame, CA) at room temperature for 30 min. After washing, the sections were incubated with avidin- biotin- peroxidase complex at room temperature for 30 min with the vectastain Elit ABC kit (Vector laboratories Burlingame,CA). Color developed with 3, 3- diamin- obenzidine as the substrate.

Sections were counter – stained with harris acid hematoxylin to demonstrate the specify of the

immunostaining and the primary antibody was placed with similar protein concentration of normal rabbit IgG.

For Cyclin D1, positive cell nucleus not found or the percentage of positive cell nucleus was $>10\%$ was taken as negative. When the percentage of positive cell nucleus was between 11-25%, it was taken as weakly positive. The percentage of positive cell between 26-50% was taken as moderately positive and greater than 50% was strongly positive.

Statistical analysis:

Data were statistically reviewed using SPSS software (version 14). χ^2 or Fisher's exact, test *t*-test, ANOVA and Spearman's Correlation were used to compare the frequencies of Cyclin D1 in different groups. $P < 0.05$ was considered statistically significant.

Ethical Considerations

Since, the study was performed on the paraffin blocks of pathological samples, and in respect of not revealing patients' secrets and records, this study was ethically watched. All samples had Code registry numbers and no name was used to identify a sample or a patient.

Results

Twenty cases (54.1%) were male and 17 (45.9%) were female. Median age was 57.94 ± 12.8 years (range 32-75 years). Eighteen patients were <60 years (43.2%) and 31 were ≥ 60 years (56.8%).

Based on endoscopic report and barium swallow features, tumor location was limited to lower third of esophagus in 25(67.6%) cases and middle third in 12 cases (32.4%). Length of lesion was undetermined in 22 patients and in 15 patients was measured according endoscopic and barium swallow reports with median 5.2 ± 1.78 cm and range 2-8 cm.

Clinical dysphagia grading was recorded for all patients at first visit and after preoperative chemoradiotherapy for clinical response investigation.

According to dysphagia grading: 4 patients had grade I (10.8%), 9 grade II (24.3%), 14 grade III (37.8%), 10 grade IV (27%) in before treatment.

Our pathologist reviewed all the endoscopic and surgical blocks. Based on pathologic grading (1), the most reported grade was grade II.

Cyclin D1 over expression in endoscopic specimens was different from 0-80% (Fig. 1).

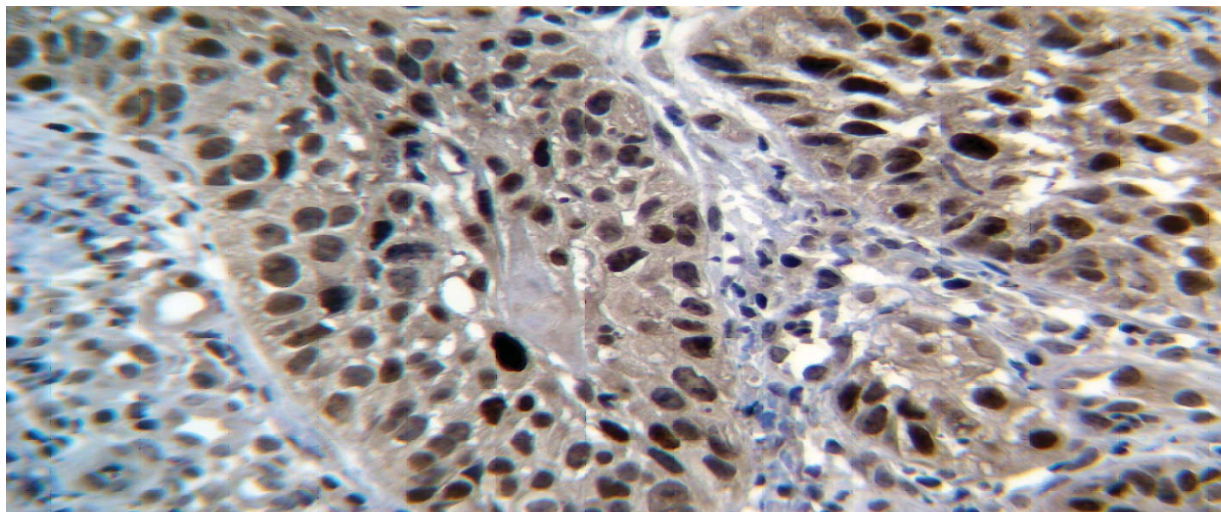


Fig. 1. Strongly Positive Cyclin D1 in Esophageal squamous cell carcinoma

According to cut off point 10%, 24 patients (64.9%) were Cyclin D1 positive (7). Relation between endoscopic Cyclin D1 over expression with age, sex and tumor grade is shown in Table 1.

Table 1: Correlation between Cyclin D1 Over Expression and Age, Sex and Tumor Grade

	<i>Cyclin D1 negative</i> Number (%)	<i>Cyclin D1 positive</i> Number (%)	<i>p-values</i>
sex			
Male	8(40%)	12(60%)	0.373
Female	5(29.4%)	12(70.6%)	
Age			
Mean (SD)	57.87(±13.2)	58.7(±10)	0.962
<60	5(50%)	5(50%)	0.014
>=60	88(74.57%)	30(25.42%)	

Clinical response was evaluated after neo-adjuvant chemo-radiotherapy in dysphagia grading reported by patients. Four patients with grade I dysphagia had no different in dysphagia grading after neo-adjuvant chemo-radiotherapy, but 9 patients with grade II dysphagia before treatment, 8 patients had grade I after chemo-radiation (88.9%) and only one case had persistently grade II dysphagia. From 14 cases with grade III dysphagia in 13 patients (96.9%) dysphagia was better. From 10 patients with grade IV dysphagia in 8 patients (80%) dysphagia was improved and 8 cases had no clinical response to neo-adjuvant chemo-radiotherapy. None of patients had progression in dysphagia.

After surgery all pathologic specimens were reviewed and complete response was reported in 18 cases (48.6%) and 19 cases had no response (51.4%). 9 patients without Cyclin D1 expression had complete pathologic response (69.2%) versus 9 patients with Cyclin D1 over expression (37.5%) [$P= 0.09$] (Fig. 2).

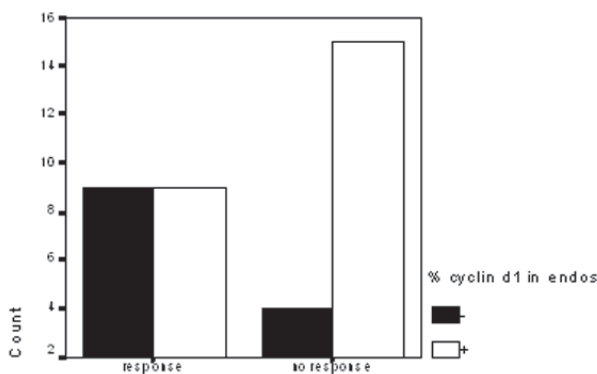


Fig. 2. Relationship between Cyclin D1 Overexpression and Complete Pathologic Response to Chemo-radiotherapy Regimen in ESCC Patients ($P= 0.09$)

Discussion

Cancer of esophagus is one of the most common cancers in northern Iran, for which current consensus of treatment varies from surgery, radiotherapy and chemotherapy or their combination. The outcome, however remain dismal, because most patients are seen with advanced disease on diagnosis (1).

Thus, the majority of patients need a multimodality to increase survival (1,3-7). Recently, more tumor markers are being correlated with tumor characteristics. The ability to predict, on the basis of immunohistochemical assessment of pretreatment biopsy, which patients are likely to respond to chemo-radiotherapy would be a major advance in the management of cancer patients.

Thus, it is possible to provide the most adequate protocol for different patients by combining traditional factors and the markers of tumor cells (3, 5).

Most studies reported patients with Cyclin D1 amplification and protein expression had a poor outcome and a higher incidence of distant metastasis than those in amplification negative or protein expression –negative groups (4, 6-11).

The overall survival rates and disease free survival in the high Cyclin D1 expression group were significantly shorter than in the Cyclin D1 low or non-expression group.

Somega *et al.* (7) reported Cyclin D1 as an indicator of tumor progression and prognosis in patients with esophageal SCC. Nation *et al.* (12), reported 55 esophageal cancer patient with a ratio of Cyclin D1 protein positive expression of 38% gave a 5 year survival rate of 7, as compared with 59% in patients who showed Cyclin D1 protein negative expression ($P<0.01$).

In our study, Cyclin D1 over expression was seen in endoscopic specimens of 24 patients (64.9%).

We could not find any relation between Cyclin D1 expression and sex, age and tumor grade (Table 2)

We observed 18 (48.6%) complete response to neoadjuvant chemo-radiotherapy. Patients who were Cyclin D1 positive in endoscopic specimens had lower pathologic complete response compared with Cyclin D1 negative group (Fig. 2) ($P=0.09$)

Conclusion

Considering that more than 60% patients had Cyclin D1 protein over expression in endoscopic specimens; it may be useful as tumor marker in ESCC patients and this group, because of low response to preoperative chemo-radiotherapy, better to refer for definitive surgery as soon as possible.

Acknowledgments

We would like to thank Dr. R. Salec and Dr. M. Sylaniyan for their helpful guidance. The authors also are thanking Mrs. Lari for her technical assistance. This work was supported by grants from Cancer Research Center of Mashhad University of Medical Science and Research Council of Mashhad University of Medical Sciences (code number = 228). The authors declare that they have no conflicts of interest.

References

1. El-Naggar AK, Kaye FJ, Shirazi Y, Gutkind JS, Forastiere AA. Meeting report--the NIDCR 2(nd) Salivary Gland Tumor Meeting, November 2008. *Head Neck* 2009;31(12):1542-3.
2. Kii T, Takiuchi H, Kawabe S, Gotoh M, Ohta S, Tanaka T, *et al.* Evaluation of prognostic factors of esophageal squamous cell carcinoma (stage II-III) after concurrent chemoradiotherapy using biopsy specimens. *Jpn J Clin Oncol* 2007;37(8):583-9.
3. Zhu SC, Li R, Wang YX, Feng W, Li J, Qiu R. Impact of simultaneous assay, the PCNA, cyclinD1, and DNA content with specimens before and after preoperative radiotherapy on prognosis of esophageal cancer-possible incorporation into clinical TNM staging system. *World J Gastroenterol* 2005;7;11(25):3823-9.

4. Shamma A, Doki Y, Shiozaki H, Tsujinaka T, Yamamoto M, Inoue M, *et al.* Cyclin D1 overexpression in esophageal dysplasia: a possible biomarker for carcinogenesis of esophageal squamous cell carcinoma. *Int J Oncol* 2000;16(2):261-6.

5. Zhu S, Zhai F, Yin W. Effect of cyclin D1 protein expression on the prognosis of esophageal squamous-cell carcinoma treated with preoperative radiotherapy. *Zhonghua Zhong Liu Za Zhi* 1998;20(2):129-31.

6. Prognostic significance of CyclinD1 and E-Cadherin in patients with esophageal squamous cell carcinoma: multi-institutional retrospective analysis. Research Committee on Malignancy of Esophageal Cancer, Japanese Society for Esophageal Diseases. *J Am Coll Surg* 2001; 192(6):708-18.

7. Itami A, Shimada Y, Watanabe G, Imamura M. Prognostic value of p27(Kip1) and CyclinD1 expression in esophageal cancer. *Oncology* 1999;57(4):311-7.

8. Mega S, Miyamoto M, Ebihara Y, Takahashi R, Hase R, Li L, *et al.* Cyclin D1, E2F1 expression levels are associated with characteristics and prognosis of esophageal squamous cell carcinoma. *Dis Esophagus* 2005;18(2):109-13.

9. Toyoda H, Nakamura T, Shinoda M, Suzuki T, Hatooka S, Kobayashi S, *et al.* Cyclin D1 expression is useful as a prognostic indicator for advanced esophageal carcinomas, but not for superficial tumors. *Dig Dis Sci* 2000;45(5):864-9.

10. Zhang J, Li Y, Wang R, Wen D, Sarbia M, Kuang G, *et al.* Association of cyclin D1 (G870A) polymorphism with susceptibility to esophageal and gastric cardiac carcinoma in a northern Chinese population. *Int J Cancer* 2003 Jun 10; 105(2):281-4.

11. Shamma A, Doki Y, Shiozaki H, Tsujinaka T, Inoue M, Yano M, *et al.* Effect of cyclin D1 and associated proteins on proliferation of esophageal squamous cell carcinoma. *Int J Oncol* 1998;13(3):455-60.

12. Naitoh H, Shibata J, Kawaguchi A, Kodama M, Hattori T. Overexpression and localization of cyclin D1 mRNA and antigen in esophageal cancer. *Am J Pathol* 1995;146(5):1161-9.