

# Case Report

## Primary Stromal Sarcoma of Breast with Nodal Recurrence

Ali Yaghobi<sup>1</sup>, Payam Azadeh<sup>1</sup>, Shiva Moghadam<sup>1</sup>, Behrouz Shafaghi<sup>2</sup>

1. Dept. of Radiotherapeutic oncology, Shahid Beheshti University of Medical Sciences, Tehran, Iran

2. Dept. of Pathology, Shahid Beheshti University of Medical Sciences, Tehran, Iran

### ABSTRACT

Although most breast cancers are adenocarcinomas of the mammary gland, primary breast sarcomas may also arise from mammary gland mesenchymal tissue. Sarcomas represent less than 1% of primary breast neoplasms. These tumors are at high risk of recurrence and are known to have poor prognosis. Surgical resection is the primary treatment for these lesions and axillary lymph node dissection is not routinely indicated in the setting of a clinically negative axilla. In this report, we introduce a patient with breast stromal sarcoma based on surgical pathology that has experienced axillary lymph node recurrence later during follow up period.

**Key words:** Breast, Sarcoma, Adenocarcinoma, Iran

### Introduction

The annual incidence of primary breast sarcoma is low, occurring in fewer than 1% of women with breast malignancies (1). One subgroup is spindle cell, which resembles leiomyoma but contains occasional glandular spaces, and tubular as well as lobular variants. They have shown to behave as low-grade malignant neoplasm, having the potential to recur locally if not completely excised and, very rarely, to metastasize (2).

Pathology analysis has a great importance in diagnosis of primary breast sarcomas (3). While low-grade tumors tend to follow an indolent course, high-grade tumors, which represent the majority of

cases, are extremely aggressive. The main factors that determine disease stage include histological grade and tumor size. The majority of publications consist of limited retrospective series, which have not been able to define the optimal management of these tumors in terms of surgery, radiation therapy (RT), and chemotherapy. Nevertheless, it is common to consider total mastectomy without axillary dissection as the standard of care (4).

### Case report

Our patient is a 54-year-old married woman who initially referred with left breast pain and discomfort,

---

Received: 13 January 2009

Accepted: 10 April 2009

Address communications to: Dr Ali Yaghobi, Department of Radiotherapeutic oncology, Shahid Beheshti University of Medical Sciences, Tehran, Iran

Email: dryaghobi@yahoo.com

in another center about 4 years ago. According to evaluations, the diagnosis of breast cyst was reported and aspiration had been performed then. After that, she gradually had begun feeling pain and rigidity. A few months later, she was referred with a palpable mass. Afterwards diagnostic evaluations such as mammography and ultrasonography with the suspicion of breast sarcoma left breast mastectomy were conducted.

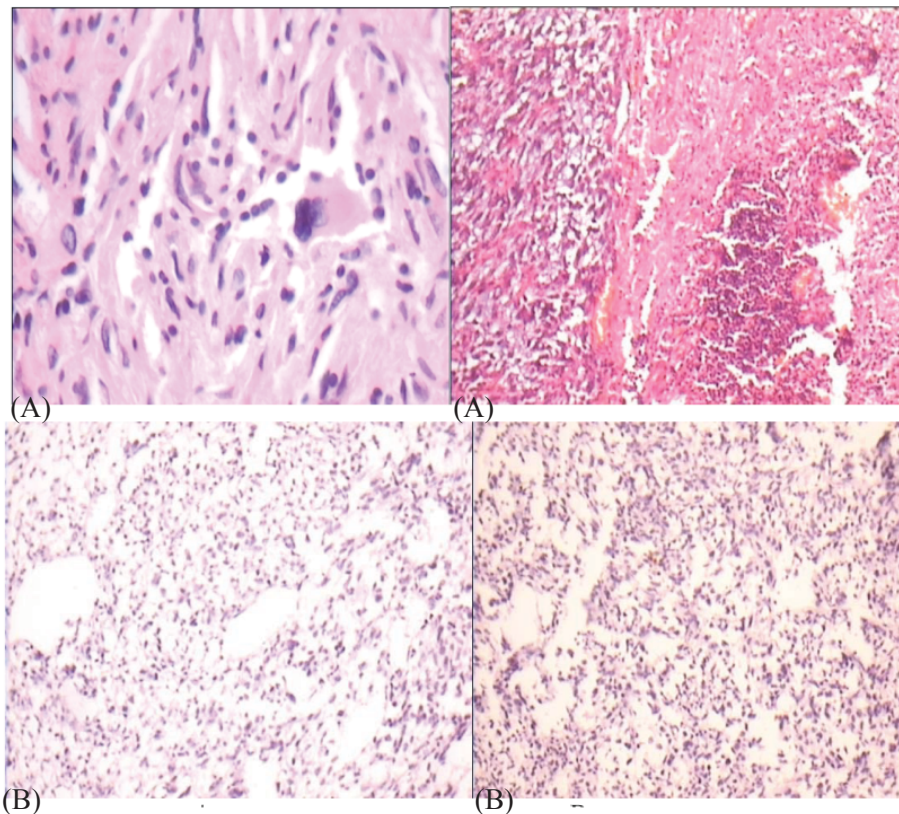
The surgical pathology result at that time was low-grade breast stromal sarcoma. In macroscopic view, multiple tumoral mass with relatively hard consistency and whitish colored largest measuring 7×4×3cm were reported and a pinkish fleshy tumoral mass in one focus was seen. In microscopy, neoplastic tissue showed intense proliferation of stroma cells and some mitotic figure with atypical appearance in some parts.

After that, she was under follow up for about 4 years. During which, she referred with left arm pain and axillary swelling since 3 months ago and she was referred to our clinic. At the time of her admission, she did not have any abnormal clinical history that could be related to her symptoms, and in physical examination, we did not detect anything abnormal except of palpable lymphadenopathy in left axillary.

Lab data including CBC diff and biochemistry, RFT and LFT were in normal ranges. On suspicion of nodal recurrence of malignancy the patient referred for left axillary lymph node dissection.

The initial pathology was reviewed in another pathology center. In microscopic review of previous blocks, specimens showed a spindle cell sarcoma with foci of storiform pattern composed of cells with pleomorphic nuclei, some multinucleated cells, and frequent mitoses. No necrosis and no lymph node structure were seen. On IHC study, tumoral cells showed no immunoreaction for CKAE1/AE3, Desmin, S100, HMB45 and CD68 and positive reaction for SMA. IHC study of lymph nodes with envisions method about CKAE1/3, CD68 (macrophage marker), desmin, HMB45, S100 and SMA was negative. Both results of lymph node dissection and the initial surgery were reported as low-grade spindle cell sarcoma. Five of seven evaluated lymph nodes were involved by tumor. It was reported as compatible with metastatic stromal sarcoma of breast (Fig.1).

Paraclinical evaluations such as imaging and bone scan were performed. Thorax and abdominopelvic CT scan with and without contrast revealed no evidence of disease progression. Whole Body Bone Scan was negative for metastasis.



**Fig. 1.** Microscopic view of tumor, the first row H&E, the second row is IHC staining view for Desmin (A) and CKAE1/3 (B)

Based on these findings, we planned to perform radiation therapy for our patient. Because of left sided location of RT, echocardiography was recommended. LV function was normal and Ejection Fraction was 60%.

External RT with 50 Gray in 27 fractions via four fields as left sided lateral and medial tangentials and both anterior and posterior supraclavicle with Cobalt 60 system was performed. Treatment of supraclavicle fields continued with 54 Gray in 3 more fractions. Now the patient is currently under surveillance in our clinic.

## Discussion

Although the majority of breast malignancies are adenocarcinomas developed on the mammary gland, primary breast sarcomas (PBS) may also arise from the mesenchymal tissue of the mammary gland. The variety of cells present in this tissue, such as fat cells, muscle cells, or endothelial cells, explains the heterogeneity of the histological types (5). The prevalence of primary breast sarcoma is low, occurring in less than 1% of women with breast malignancies (1).

Sarcoma of the breast is mainly seen in women, male cases usually representing less than 5% of primary breast sarcomas. Mean age is between 47 and 52 years (range of 17-89), and mean tumor size is between 5.5 and 5.7 cm. (3,4). A causative factor cannot be identified in the majority of primary breast sarcomas. In contrast, secondary breast sarcomas are associated with prior radiotherapy and conditions causing chronic lymphedema. A primary breast sarcoma most often presents as a large, painless, firm mass within the breast. They are seldom associated with skin and nipple changes. Clinically, these tumors often exhibit more rapid growth than do epithelial breast cancers. As a result, tumor size can be quite large, ranging from 1.5 to 30 cm.

Mammographically, calcifications and spiculation are usually absent, and these tumors may be mistaken for benign lesions (4).

The diagnosis of sarcomas in organs where they are rarely encountered is often a challenge for the pathologist. Electron microscopic examination may help in some cases, and immunoperoxidase studies can be used to further categorize these tumors. Primary breast sarcomas are uncommon, and in general they are classified according to the same criteria applied to the soft tissue counterparts. A group of mammary sarcomas are referred to as

stromal sarcomas. Pure stromal sarcomas of the breast are very rare, in addition, few cases have been reported in the literature. These tumors are composed of uniform spindle cells, often arranged in loose bundles with no epithelial elements (3, 6). Pathology analysis is of paramount importance in diagnosis of primary breast sarcomas. All doubtful cases have to be reviewed by an experienced pathologist (4). An immunohistochemical panel composed of S100, SMA, and 4 CKs, including basal-specific 34\_E12 and CK14 or CK5, is valuable in the assessment of a suspected metaplastic spindle cell tumor (2).

Similar to sarcomas found elsewhere in the body, primary breast sarcomas tend to spread by direct local invasion or hematogenously; regional lymph node involvement is rare except in the setting of widespread metastatic disease. Even if axillary lymphadenopathy is palpable, pathologic examination often fails to reveal disease spread (4). However, our case as discussed above had revealed a very rare setting as primary breast stromal sarcoma with axillary lymph node involvement in the absence of widespread metastasis.

Histological subtype is not a significant prognostic factor, with the exception of angiosarcomas, which have a poor prognosis relative to other subtypes. While low-grade tumors tend to follow an indolent course, high-grade tumors, which represent the majority of cases, are extremely aggressive. As with soft tissue sarcomas arising elsewhere in the body, prognosis for primary breast sarcomas is highly dependent upon histological grade and tumor size; these are the main factors that determine disease stage. Among the features that are used to assign grade are the extent of tissue differentiation, the mitotic count, presence or absence of necrosis, cellularity, and pleomorphism (4).

In the case of the patients with malignant, mesenchymal neoplasm's of the breast the probability of the recurrence and distant metastases, is the biggest during the first two years since diagnosis. The patients survive 5 years without the symptoms of neoplasm, have very little probability of local recurrence and spread of disease during 20 years of observation (7).

Given the rarity of breast sarcomas, there are no prospective randomized trials to guide therapy. Treatment principles have been derived from small retrospective case reviews of primary breast sarcomas and extrapolated from studies of nonbreast soft tissue sarcomas, since clinical behavior, histology, and prognosis are similar. In general, the choice of

treatment is influenced by histological grade and tumor size. Surgery represents the only potentially curative modality. An adequate resection margin is the single most important determinant of long-term survival. Tumor size was predictive of local recurrence, development of metastatic disease, and overall survival too (4, 8). Although frequently performed, axillary lymph node dissection is not routinely indicated in the setting of a clinically negative axilla, since the incidence of lymphatic spread is 5 percent or less overall, and lymphadenectomy does not improve outcomes (1, 3, 4, 8). The benefit of adjuvant radiation therapy (RT) is controversial; observational series provide conflicting data. On balance, the available data support a benefit for adjuvant RT in terms of locoregional control for large high-grade sarcomas (4, 8). As with nonbreast soft tissue sarcomas, the role of adjuvant chemotherapy is not well defined. There are no studies that exclusively involve patients with primary breast sarcomas. Nevertheless, as with extremity sarcomas, adjuvant chemotherapy is generally reserved for patients with large high-grade or recurrent tumors, and only after a thorough discussion as to the risks and benefits of therapy (4).

The authors declare that they have no conflicts of interest.

### References

1. Blanchard DK, Reynolds CA, Grant CS, Donohue

JH. Primary nonphyllodes breast sarcomas. *Am J Surg* 2003;186(4):359-61.

2. Dunne B, Lee AH, Pinder SE, Bell JA, Ellis IO. An immunohistochemical study of metaplastic spindle cell carcinoma, phyllodes tumor and fibromatosis of the breast. *Hum Pathol* 2003;34(10):1009-15.

3. Bousquet G, Confavreux C, Magne N, de Lara CT, Poortmans P, Senkus E, *et al.* Outcome and prognostic factors in breast sarcoma: a multicenter study from the rare cancer network. *Radiother Oncol* 2007;85(3):355-61.

4. Uptodate.com/online/content [homepage on the Internet]. Primary nonepithelial breast malignancies. The Netherlands: 2009 (<http://www.uptodate.com/online/content>)

5. Confavreux C, Lurkin A, Mitton N, Blondet R, Saba C, Ranchere D, *et al.* Sarcomas and malignant phyllodes tumours of the breast--a retrospective study. *Eur J Cancer* 2006;42(16):2715-21.

6. Garcia-Palazzo IE, Palazzo JP, Liu ZM, Taguchi T, Testa JR. Correction: cytogenetic findings in a breast stromal sarcoma. Application of fluorescence in situ hybridization to characterize the breakpoint regions in an 11;19 translocation: *Cancer Genet Cytogenet* 63:4751-, 1992. *Cancer Genet Cytogenet* 1996 ;1;89(1):92.

7. Niwinska A, Chmielewski R. Breast sarcoma and carcinosarcoma. *Am J surg* 2002;184:361-4.

8. Fields RC, Aft RL, Gillanders WE, Eberlein TJ, Margenthaler JA. Treatment and outcomes of patients with primary breast sarcoma. *Am J Surg* 2008;196(4):559-61.