

## Case Report

### Ancient Schwannoma of the Trigeminal Nerve Mimicking High Grade Lesion

Amit Agrawal, Arvind Bhake, Nisha Meshram, Nisha Meshram

Dept. of Surgery, Datta Meghe Institute of Medical Sciences, Nagpur, India

#### ABSTRACT

Ancient schwannomas rarely found in the central nervous system and ancient change in an intracranial schwannoma (intracranial portion of the trigeminal nerve) is extremely rare. A seventy-year man presented with headache of 3 months duration and one episode of generalized tonic-clonic seizures. Imaging findings were suggestive of left temporal high grade lesion. During surgery there was well capsulated extra-axial lesion. Histology was suggestive of ancient schwannoma. Based on the literature it is suggested when the intraoperative appearance of a cerebello-pontine lesion is consistent with a schwannoma and the frozen section is suggestive of a malignant lesion, a complete excision of the lesion can be carried out.

**Key words:** Schwannoma, Brain tumor, Trigeminal nerve

#### Introduction

Ancient schwannoma a relatively uncommon histological variant of schwannoma was initially described by Ackerman *et al.* (1), usually involves the peripheral nervous system (2-10). Ancient schwannomas rarely found in the central nervous system (3, 11) and ancient change in an intracranial schwannoma (intracranial portion of the trigeminal nerve) has been described once (12). We report this article because of rarity, unique appearance and distinct clinical application.

#### Case report

A seventy-year man presented with headache of 3 months duration and one episode of generalized tonic-

clonic seizures. There was no previous significant history. General and systematic examination was normal. Higher mental functions were normal. There were no focal neurological deficits. Fundus showed bilateral papilloedema. X-ray chest and ultrasound was normal. Blood investigations were normal. CT scan brain plain and contrast showed heterogeneous enhancing mass lesion in left temporal region with mass effect and peri-lesional oedema (Fig. 1). Based on imaging findings a differential diagnosis of high grade glioma and metastases were made. The patient underwent left fronto-temporal craniotomy and near total decompression of the lesion was performed. The lesion was extra-axial, firm, vascular, fibrous in nature with well-defined plane of separation from brain. Intra-operative impression was meningioma

---

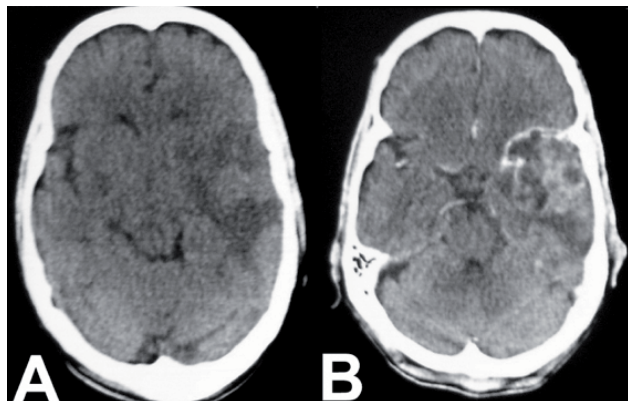
Received: 11 June 2009

Accepted: 13 August 2009

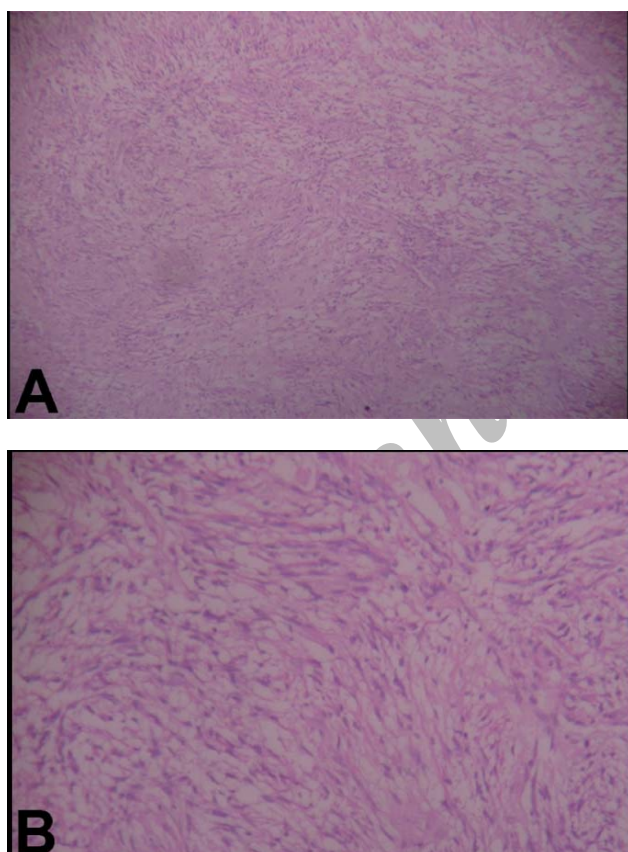
Address communications to: Dr Amit Agrawal, Department of Surgery, Datta Meghe Institute of Medical Sciences, Sawangi (Meghe), India

Email: dramitagrawal@gmail.com

versus schwannoma. On histology, the section showed elongated spindle nuclear cells arranged in the palisades and occasional Verucae bodies, part of the sections showed aggressive, atypical nuclear morphology suggestive of ancient schwannoma (Fig. 2). The patient is doing well at following up.



**Fig 1:** Axial CT scan showing a well-circumscribed heterogeneous mass with peripheral enhancement



**Fig 2:** The section showed elongated spindle nuclear cells arranged in the palisades and occasional Verucae bodies, part of the sections showed aggressive, atypical nuclear morphology suggestive of ancient schwannoma (A) H&E, (B)  $\times 400$ .

## Discussion

Ancient schwannomas are rare benign tumors, deriving from neural crest cells (1, 13). All these changes believed to occur because it takes a long time for schwannomas to develop (14). Ancient schwannoma is characterized by hypercellularity, nuclear pleomorphism, hyperchromasia and degenerative changes including perivascular hyalinization, calcification, cystic necrosis, relative loss of Antoni type A tissue, and degenerative nuclei (1, 12, 15, 16). Increased cellularity and nuclear atypia with cell pleomorphism may resemble malignant tumors, resulting in a false interpretation as high-grade lesions including malignant peripheral nerve sheath tumors (1, 5, 12). However, the absence of mitosis and the presence of cystic necrosis and a well-defined capsule without brain invasion helps to differentiate these lesions from high-grade lesions (12). The radiological findings for ancient schwannoma are similar to those for schwannoma (1). On CT scan appear as a well-defined mass with enhancement in capsules or pericystic areas including enhancement of surrounding degeneration areas (9). Ancient schwannomas are benign tumors and the goal of treatment is complete excision with possible preservation of the involved nerve as complete resection is usually curative with a good prognosis (12). It has been suggested that if the intraoperative appearance of a cerebello-pontine lesion is consistent with a schwannoma and the frozen section is suggestive of a malignant lesion a complete excision of the lesion can be carried out (12).

## References

1. Ckerman LV, Taylor FH. Neurogenous tumors within the thorax; a clinicopathological evaluation of forty-eight cases. *Cancer* 1951; 4(4):669-91.
2. Dayan D, Buchner A, Hirschberg A. Ancient neurilemmoma (Schwannoma) of the oral cavity. *J Craniomaxillofac Surg* 1989; 17(6):280-2.
3. Graviat S, Sinclair G, Kajani N. Ancient schwannoma of the foot. *J Foot Ankle Surg* 1995; 34(1):46-50.
4. Hide IG, Baudouin CJ, Murray SA, Malcolm AJ.

Giant ancient schwannoma of the pelvis. *Skeletal Radiol* 2000; 29(9):538-42.

5. Isobe K, Shimizu T, Akahane T, Kato H. Imaging of ancient schwannoma. *Am J Roentgenol* 2004; 183(2):331-6.
6. Jayaraj SM, Levine T, Frosh AC, Almeyda JS. Ancient schwannoma masquerading as parotid pleomorphic adenoma. *J Laryngol Otol* 1997; 111(11):1088-90.
7. Loke TK, Yuen NW, Lo KK, Lo J, Chan JC. Retroperitoneal ancient schwannoma: review of clinico-radiological features. *Australas Radiol* 1998; 42(2):136-8.
8. McCluggage WG, Bharucha H. Primary pulmonary tumours of nerve sheath origin. *Histopathology* 1995; 26(3):247-54.
9. Schultz E, Sapan MR, Heffey-Atkinson B, Naidich JB, Arlen M. Case report 872. "Ancient" schwannoma (degenerated neurilemoma). *Skeletal Radiol* 1994; 23(7):593-5.
10. Darwish BS, Balakrishnan V, Maitra R. Intramedullary ancient schwannoma of the cervical spinal cord: case report and review of literature. *J Clin Neurosci* 2002; 9(3):321-3.
11. Mills B, Marks PV, Nixon JM. Spinal subarachnoid haemorrhage from an "ancient" schwannoma of the cervical spine. *Br J Neurosurg* 1993; 7(5):557-9.
12. Ugokwe K, Nathoo N, Prayson R, Barnett GH. Trigeminal nerve schwannoma with ancient change. Case report and review of the literature. *J Neurosurg* 2005; 102(6):1163-5.
13. Dodd LG, Marom EM, Dash RC, Matthews MR, McLendon RE. Fine-needle aspiration cytology of "ancient" schwannoma. *Diagn Cytopathol* 1999; 20(5):307-11.
14. Dahl I. Ancient neurilemmoma (schwannoma). *Acta Pathol Microbiol Scand* 1977; 85(6):812-8.
15. Kagaya H, Abe E, Sato K, Shimada Y, Kimura A. Giant cauda equina schwannoma. A case report. *Spine* 2000; 25(2):268-72.
16. Giglio M, Giasotto V, Medica M, Germinale F, Durand F, Queirolo G, *et al.* Retroperitoneal ancient schwannoma: case report and analysis of clinico-radiological findings. *Ann Urol (Paris)* 2002; 36(2):104-6.

Archive of SID