

Case Report

Mesenchymal Chondrosarcoma: A Report of Two Cases with Immunohistochemical Study

Reeby Sara Thomas, Herald J Sherlin, Anuja Natesan,
Priya Premkumar, Pratibha Ramani, Thiruvengadam Chandrasekar,
Vinod Narayanan

Dept. of Oral and Maxillofacial Pathology, Saveetha Dental College, Chennai, Tamil Nadu, India

ABSTRACT

Mesenchymal chondrosarcoma (MC) is an uncommon tumor with an aggressive behaviour. We present two cases of MC. The first one is a unique case of MC of the maxilla metastasized from the clavicle. The second describes MC in the mandible with extensive involvement of the condyle. A 31-year-old male and a 22-year-old male presented to Saveetha Dental College, with a 2-month history of progressive mass in left posterior maxilla and a firm swelling in the right mandibular region, respectively. Incisional biopsy of both the cases revealed characteristic bimorphic pattern composed of sheets of undifferentiated round and spindle cells along with areas of chondroid matrix of variable cellularity. Histopathological features were suggestive of MC. These type of neoplasms show local aggressive behaviour with high metastatic and recurrence potential due to which the prognosis of MC is poor.

Key words: Mesenchymal Chondrosarcoma, Maxilla, Mandible, India

Introduction

Mesenchymal chondrosarcoma (MC) is a histologically distinct, rare, malignant neoplasm thought to derive from primitive cartilage-forming mesenchyme (1). MC represents approximately 1% of all chondrosarcomas (2). It was first described by Lichtenstein and Bernstein in 1959 as a biphasic tumor, comprising of spindle cell mesenchyme interspersed with areas of chondroid

differentiation (3). MC primarily occurs in the femur, ribs, clavicle and facial bone although other sites have been reported (4-6).

Only 37 cases of MC of the maxilla have been reported till date. We report the first case of metastatic MC from clavicle to the maxilla. The incidence of primary chondrosarcoma of the clavicle is extremely rare, contributing to less than 0.5% of all tumors affecting the clavicle (7).

This article presents an additional case MC of

Received: 9 August 2009

Accepted: 27 December 2009

Address communications to: Dr. Reebysara Thomas, Dept. of Oral and Maxillofacial Pathology, Saveetha Dental College, Chennai, Tamil Nadu, India

Email: reebysara@hotmail.com

mandible, which is unique because of its extensive involvement including the condyle.

Case Report

Case 1:

A 31 year old Indian male reported to the out-patient department of Saveetha Dental College, with a chief complaint of swelling and pain in relation to the left posterior maxilla for the past 2 months. History revealed that the swelling was insidious in onset with gradual progression to the present state accompanied with pain and difficulty in swallowing. Patient reportedly underwent surgery 5 months prior for chondrosarcoma of the left clavicle.

Clinical examination revealed a firm swelling measuring approximately 6cm × 4cm in size extending from the left maxillary premolar region into the tuberosity and soft palate. The swelling was well defined, lobulated, covered by a greyish white slough and tender on palpation (Fig. 1). Computerised tomography (CT) scan revealed a 5.3cm × 6.2cm × 6cm radiolucent mass with specks of radiopacities eroding the posterior maxillary wall. Tumour infiltration into the retromaxillary region, pterygoid musculature and lateral wall of the nose was evident. This radiographic appearance suggested a high grade malignancy. An incisional biopsy revealed characteristic bimorphic pattern composed of sheets of undifferentiated round and spindle cells along with areas of chondroid matrix of variable cellularity. Cells of chondroid differentiation exhibited both nuclear and cytoplasmic pleomorphism, hyperchromasia along with numerous abnormal mitotic figures. Areas of ossification were also evident (Fig. 2). Immunohistochemical analysis of sections was performed using antibodies against S100 and Vimentin (Biogenex, San Ramon, Ca, USA). S100 was positive for the malignant chondrocytes within the chondroid matrix (Fig. 3). The mesenchymal areas around the chondroid matrix showed strong positivity to vimentin. Histopathological features were suggestive of Mesenchymal Chondrosarcoma. Correlating with the past surgical history and clinical findings, a final diagnosis of Mesenchymal Chondrosarcoma of maxilla metastasized from clavicle was made. Patient declined treatment due to personal reasons.

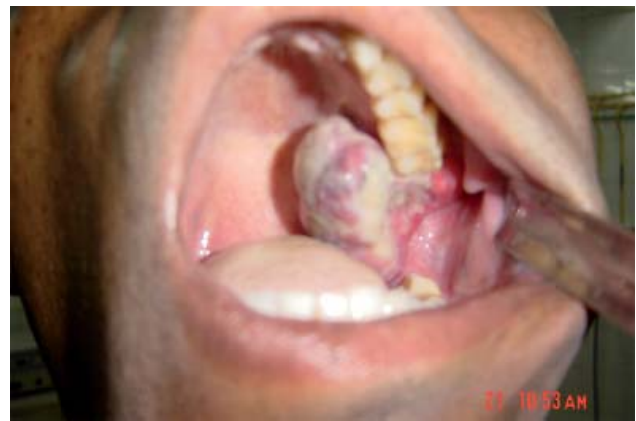

Fig. 1: Intraoral picture showing a lobulated swelling extending from left second premolar region to the soft palate.

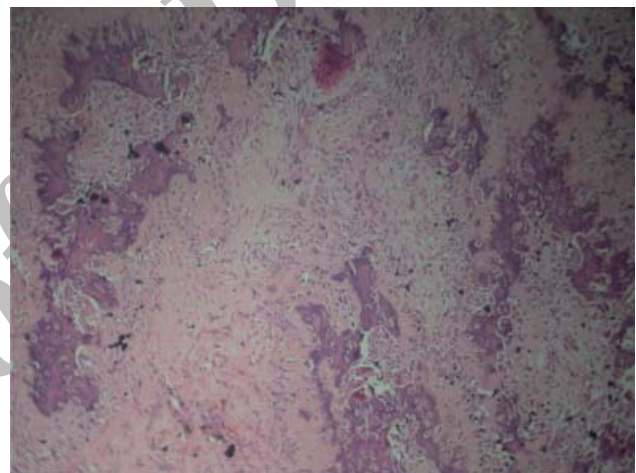


Fig. 2: Tumor mass composed of sheets of undifferentiated pleomorphic cells within a chondroid matrix (H&E staining ×100)

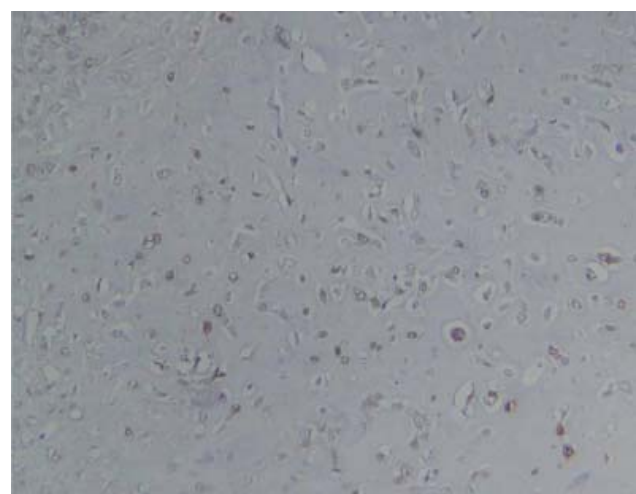


Fig. 3: IHC showing malignant chondrocytes with S100 positivity.

Case 2:

A 22 year old Indian male presented to the out-patient department of Saveetha Dental College, with a 2 month history of swelling and numbness in the right mandibular region. Extra-oral examination revealed a swelling measuring 7cm × 6cm in size. It extended superiorly, 2cm below the outer canthus of the right eye and inferiorly to the lower border of the mandible. Anteriorly the swelling extended 2cm from the angle of the mouth and posteriorly, 3cm from the tragus of the ear. Marked facial asymmetry along with bicortical expansion was noted on the right side. On palpation, swelling was tender and firm in consistency. Right mandibular nerve paresthesia along with submandibular and cervical lymphadenopathy was detected. Intra-orally, on inspection the swelling, extended from the right mandibular premolar region to the retromolar region. The swelling appeared diffuse but lobulated with an ulcerated surface and measured 5cm × 5cm in size. The swelling was bony hard in consistency and tender on palpation. CT scan revealed a massive radiolucent lesion with dispersed radiopacities in the bone presenting as sun burst appearance on the right side of the ramus of the mandible extending into the condyle. The lesion measured 5cm × 4.3cm × 5.7cm in size (Fig. 4). An incisional biopsy revealed a bimorphic pattern composed of fields of chondroid matrix along with sheets of undifferentiated round and spindle cells. The nuclei of chondrocytes was large and pleomorphic with numerous mitotic figures. Histopathological features were suggestive of MC. Immunohistochemical analysis of the tumor cells revealed positivity for vimentin and S-100.

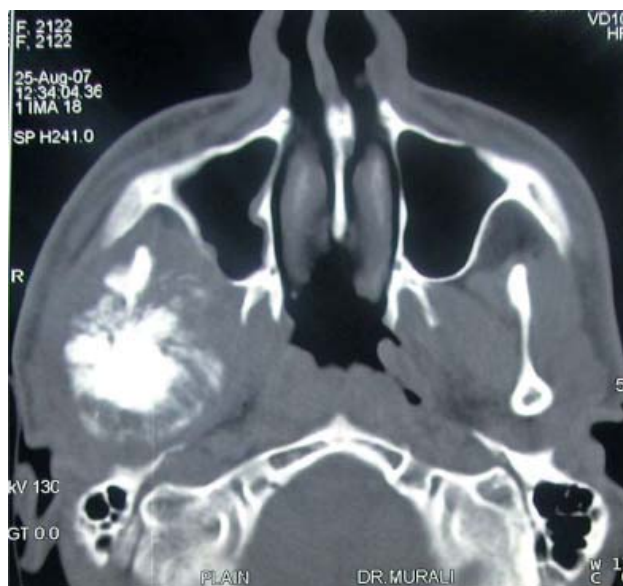

Fig. 4: CT scan showing radiolucent lesion with dispersed radio-opacities and sunburst pattern on the right side of mandible

The patient underwent hemimandibulectomy followed by reconstruction using iliac graft. Grossly the resected specimen measured 7.2cm × 6.4cm. It was brownish white in colour, nodular and firm in consistency. The excisional biopsy was consistent with the report of MC. Considering the sparse chondroid matrix and increased cellularity, large & pleomorphic nuclei with prominent nucleoli, and the presence of numerous mitotic figures, a final diagnosis of Mesenchymal Chondrosarcoma, Grade III was made.

Discussion

MC is an uncommon but characteristic malignant tumour first described by Lichenstein and Bernstein (3). MC is a rare subtype of chondrosarcoma that constitutes 1% of all chondrosarcomas (6). Three percent to 25% of all skeletal MC occur in the maxillofacial region (8). The premolar and molar region was the most common site affected in the maxilla according to Christensen *et al.* (9). A total of 37 cases of MC affecting the maxilla have been reported in English Literature till date (10). To the best of our knowledge, we add one more case to the literature and the first case of metastatic MC from the clavicle to the maxilla.

In the mandible, 26 cases have been reported in English literature till date. Although the most common location is the premolar- molar area but the symphysis, coronoid and condyle may be involved (8). This is a unique case of MC of mandible extensively involving the condyle.

MC occurs between ages 10 and 30 with a mean age of 29.7 years. There is a predilection for the maxilla followed by mandible in the craniofacial complex (11, 12). Our patients (aged 31 years and 22 years) were also within the reported age range and with the same site of occurrence. MC is reported to have a 1.6:1 gender predilection for females (10) although the cases we present occurred in males.

The predominant clinical symptom is painless mass or swelling. Other most commonly reported symptoms are nasal obstruction, epistaxis, tooth mobility, headache, bleeding, ulceration, facial asymmetry, paresthesia and trismus (8). In the first case, patient reported with a painful mass along with dysphagia. In the second case, the patient reported with a swelling causing facial asymmetry and paresthesia.

Takahashi *et al.* indicated differences in the radiographic features between mandibular and maxillary lesions. Maxillary MC frequently presents as a radiopaque or mixed mass that commonly invades the maxillary sinus, similar to our first case. Mandibular MC usually appears as a radiolucent lesion with occasional calcifications (13). This coincides with the Second case.

The histopathology of MC is distinct regardless of the site of origin. They are characterised by a biphasic pattern, with a sheet-like or patternless proliferation of small undifferentiated spindle or round cells surrounding discrete nodules of differentiated hyaline cartilage (10). Our findings were also consistent with previous literatures. The differential diagnosis for MCs include other cartilage-containing lesions, such as conventional chondrosarcoma, chondroblastic osteosarcoma however the absence of osteoid matrix, bony trabeculae and alkaline phosphates expressed by the tumor cells exclude this possibility, chondromyxoid fibroma which presents as a lobulated myxoid areas composed of spindle or stellate cells, chondroma, osteochondroma and synovial chondromatosis (10,14).

The immunohistochemical profiles of the present

cases were consistent with the literature. The cells of the cartilaginous component demonstrated positive immunostaining for S100 (15). Mesenchymal components were positive for vimentin. Although the S100 protein, vimentin and total collagen immunohistochemical staining is not specific for discriminating this neoplasm. Aigner *et al.* have reported that substantial portion of MC show chondroprogenitor phenotype with an onset in expression of vimentin and collagen type IIA (16). These results establish MC as the very neoplasm of differentiating premesenchymal chondroprogenitor cells (17).

Recent studies showed that malignant mesenchymal chondroblasts exhibit stronger expression of CD99, IL-1 α , cPKC- α , p-PKC- α /beta II, PDGFR- α , p-JNK, Ki-67, and bcl-2 antigens than their more mature-appearing chondrocytic counterparts in chondrosarcoma. The expressions of both MMP1 and MMP2 have a significant correlation with the tumor grade and a crucial role in invasion of human cartilaginous tumors (16). The cytogenetic factor which instigates this tumour is der (13, 21) (q10; q10) translocation, unique to MC (18).

It is proposed that the most effective therapeutic modality is wide surgical excision, accompanied by radiotherapy, which may play a role, although some believe MC to be a radioresistant tumor. Chemotherapy plays a limited role, and should be employed for high grade mesenchymal tumours, local recurrence with aggressive behaviour, or where there is a potential for metastasis (14).

The prognosis of MC is poor because tumours have a tendency for late recurrence either local or via metastasis. Metastasis of MC is hematogenous and the most common site is the lung and bone (14). We report the first case of a metastatic MC arising in the maxilla from the clavicle in English literature. Niven *et al.* reported that prognosis for maxillary MC is poor and death may occur at a relatively high frequency due to late recurrence or metastasis (10). Unfortunately our patient succumbed to the disease three months after diagnosis. Akpolat and Gok reported that atleast 60% of patients have recurrences within five years of initial treatment (8). Our patient with mandibular MC remains disease free, one year after surgical resection.

Conclusion

MC is a rare malignant connective tissue tumor. These tumors show local aggressive behaviour as well as a high metastatic and recurrence potential. Due to these features the prognosis of MC is poor. In this report we present the first case in English literature of maxillary MC, metastasized from the clavicle and a rare presentation of mandibular MC extending to the condyle.

References

1. Rushing EJ, Armonda RA, Ansari Q, Mena H. Mesenchymal chondrosarcoma: a clinicopathologic and flow cytometric study of 13 cases presenting in the central nervous system. *Cancer* 1996; 77(9):1884-91.
2. Pellitteri PK, Ferlito A, Fagan JJ, Suarez C, Devaney KO, Rinaldo A. Mesenchymal chondrosarcoma of the head and neck. *Oral Oncol* 2007; 43(10):970-5.
3. Lightenstein L, Bernstein D. Unusual benign and malignant chondroid tumors of bone. A survey of some mesenchymal cartilage tumors and malignant chondroblastic tumors, including a few multicentric ones, as well as many atypical benign chondroblastomas and chondromyxoid fibromas. *Cancer* 1959; 12:1142-57.
4. Al-Bayaty HF, Murti PR, Thomson ER, Deen M. Painful, rapidly growing mass of the mandible. *Oral Surg Oral Med Oral Pathol Oral Radiol Endod* 2003; 95(1):7-11.
5. Christensen RE, Jr. Mesenchymal chondrosarcoma of the jaws. *Oral Surg Oral Med Oral Pathol* 1982; 54(2):197-206.
6. Nakashima Y, Unni KK, Shives TC, Swee RG, Dahlin DC. Mesenchymal chondrosarcoma of bone and soft tissue. A review of 111 cases. *Cancer* 1986; 57(12):2444-53.
7. Amalourde A, Vinayaga P, Naveed N, Jamal A, Looi LM, Sengupta S. A rare case of chondrosarcoma of the clavicle. *Med J Malaysia* 2004; 59 Suppl F: 60-2.
8. Akpolat N, Gok U. Mesenchymal Chondrosarcoma of the Mandible. *Turk J Med Sci* 2004 ;(34):209-13.
9. Hackney FL, Aragon SB, Aufdemorte TB, Holt GR, Van Sickels JE. Chondrosarcoma of the jaws: clinical findings, histopathology, and treatment. *Oral Surg Oral Med Oral Pathol* 1991; 71(2):139-43.
10. Tien N, Chaisuparat R, Fernandes R, Sarlani E, Papadimitriou JC, Ord RA, *et al.* Mesenchymal chondrosarcoma of the maxilla: case report and literature review. *J Oral Maxillofac Surg* 2007; 65(6):1260-6.
11. Aziz SR, Miremadi AR, McCabe JC. Mesenchymal chondrosarcoma of the maxilla with diffuse metastasis: case report and literature review. *J Oral Maxillofac Surg* 2002; 60(8):931-5.
12. Lockhart R, Menard P, Martin JP, Auriol M, Vaillant JM, Bertrand JC. Mesenchymal chondrosarcoma of the jaws. Report of four cases. *Int J Oral Maxillofac Surg* 1998; 27(5):358-62.
13. Takahashi K, Sato K, Kanazawa H, Wang XL, Kimura T. Mesenchymal chondrosarcoma of the jaw--report of a case and review of 41 cases in the literature. *Head Neck* 1993; 15(5):459-64.
14. Angiero F, Vinci R, Sidoni A, Stefani M. Mesenchymal chondrosarcoma of the left coronoid process: report of a unique case with clinical, histopathologic, and immunohistochemical findings, and a review of the literature. *Quintessence Int* 2007; 38(4):349-55.
15. Swanson PE, Lillemoe TJ, Manivel JC, Wick MR. Mesenchymal chondrosarcoma. An immunohistochemical study. *Arch Pathol Lab Med* 1990; 114(9):943-8.
16. Aigner T, Loos S, Muller S, Sandell LJ, Unni KK, Kirchner T. Cell differentiation and matrix gene expression in mesenchymal chondrosarcomas. *Am J Pathol* 2000; 156(4):1327-35.
17. Stefansson K, Wollmann RL, Moore BW, Arnason BG. S-100 protein in human chondrocytes. *Nature* 1982; 295(5844):63-4.
18. Brown RE, Boyle JL. Mesenchymal chondrosarcoma: molecular characterization by a proteomic approach, with morphogenic and therapeutic implications. *Ann Clin Lab Sci* 2003; 33(2):131-41.