

## Original Article

### Determination of CD117 Expression in Glial Tumors and Its Comparison between High Grade and Low Grade Tumors

Arash Dehghan<sup>1</sup>, Hosein Mahjoub<sup>2</sup>, Azadeh Rajeipour<sup>1</sup>

1. Dept. of Pathology, Hamedan University of Medical Sciences, Hamedan, Iran
2. School of Health, Hamedan University of Medical Sciences, Hamedan, Iran

#### ABSTRACT

**Background and Objective:** Gliomas are the most common primary brain tumors. Despite therapeutic advances, the majority of gliomas do not respond to either chemo or radiotherapy. CD117, the gene product of c-kit has been expressed in cells of glial tumors. Because gastrointestinal stromal tumors (GISTs) that express CD117 respond dramatically to treatment with tyrosine kinase inhibitors, identification of glial tumors that express CD117 might open new therapeutic approaches for treatment of these tumors.

**Material and Methods:** CD117 expression was investigated in 69 glial tumors of different types and grades. This protein was visualized by immunohistochemistry with commercially available antibody. The comparison of CD117 expression between high and low-grade tumors was evaluated with SPSS V16 soft ware and Chi square test.

**Results:** Forty two percent of the tumors were positive for CD117 expression. There was a statistically significant difference in CD117 immunoreactivity between high grade and low-grade tumors (61.1% versus 21.2%,  $P=0.001$ ). 96.6% of the positive cases had cell membranous and/or cytoplasmic staining. All except two of the positive cases showed strong expression intensity. In 26.1% of cases, CD117 also expressed in endothelial cells of tumor vessels that 88.9% of them was in high-grade tumors. Glioblastoma, anaplastic oligodendroglioma and anaplastic ependymoma showed the highest staining grade.

**Conclusion:** CD117 has an important role in growth of glial tumors, especially high grade ones and that patients with CD117 expressing glial tumors might benefit from tyrosine kinase inhibitors. This finding should be further studied.

**Key words:** Brain Tumors, Gliomas, CD117 Antigen, Immunohistochemistry

---

Received: 22 June 2009

Accepted: 3 January 2010

Address communications to: Azadeh Rajeipour, Dept. of Pathology, Hamedan University of Medical Sciences, Hamedan, Iran

Email: azadr2001@yahoo.com

## Introduction

CD117 is a transmembrane tyrosine kinase growth factor receptor (1). It is the product of c-kit gene expression (2). Its ligand is referred to as stem cell factor (SCF) (3). CD117 is expressed by a variety of normal human cell types, including germ cells, immature myeloid cells, and mast cells (1). Also it immunolocalized in a variety of neoplasms, the most notable of which is GISTs, where c-kit is felt to be a relatively specific and sensitive immunohistochemical marker of GISTs. If a GIST expresses CD117, it is generally treated with tyrosine kinase inhibitors (Gleevec) (2). Glial tumors are the most common primary brain tumors. Despite therapeutic advances, the majority of gliomas do not respond either to chemo or radiotherapy (4) and investigation for new therapeutic approaches is indicated in these patients. The CD117/SCF signaling pathway is operative in astrocytes and neurons in normal developing and adult brain (3,5-7) and CD117 expression might have potential therapeutic significance for brain tumors (3,8).

CD117 was detected in gliomas especially with higher levels in anaplastic forms and glioblastomas (3,4,9-12). The importance of this pathway is underscored by growth impairment by a tyrosine kinase inhibitor of human glioblastoma that was injected into mouse brain (13), and by several reports from the effect of tyrosine kinase inhibitor (imatinib) therapy on glioblastoma (14-16). As only a subset of patients seems to benefit from imatinib mesylate therapy and due to potential side effects and high costs of imatinib mesylate therapy, selection of the appropriate patients for this therapy is important. As a step toward this goal, the present study screened 69 human glioma samples of all major types and grades for CD117 expression.

## Material and Methods

Formalin-fixed, paraffin-embedded tissue blocks were retrieved from 69 glial tumor cases of different types and grades from files of Pathology Department at Mobasher (Besat) Hospital of Hamedan University of Medical Sciences, Iran. All cases were reviewed by pathologist for the accuracy of diagnosis according

to the current World Health Organization criteria (17). Only one case of mixed glioma was there that excluded from study. CD117 expression was assessed immunohistochemically using the Polyclonal Rabbit Anti-Human CD117, c-kit (code A4502) and peroxidase labeled polymer (code K5007); Dako North America, Carpinteria, California, USA.

For each sample the following steps were performed:

Three ~~m~~-thick tissue sections were deparaffinized. Sections were microwave-treated for antigen retrieval in target retrieval solution (DAKO; code S1700) for 20 minutes at 95-99°C then incubated with 3% hydrogen peroxide in methanol for 15 minutes to block endogenous peroxidase activity. After 30 minutes incubation with the primary antibody (polyclonal rabbit anti-human CD117, c-kit, code A4502) at a 1/400 dilution in primary antibody dilution buffer, the sections were incubated with the peroxidase labeled polymer (DAKO; code K5007). After each step in the above staining procedure, the samples were carefully washed at least three times, each time with phosphate buffered saline (PBS) buffer (pH=7.4). Then, the sections were immersed for 10 minutes in diaminobenzidine (DAB) for chromogenic visualization, rinsed in distilled water briefly, counterstained with hematoxylin for 1 minute, dehydrated, and mounted.

As negative control, rabbit immunoglobulin fraction (solid-phase absorbed, code X0936); Dako North America, Carpinteria, California, USA was used.

As positive control, the reaction was tested on sections from GIST. The GIST contained cells that served as positive controls (tumor cells and interstitial cells of Cajal) as well as cells that were internal negative controls (smooth muscle cells of muscularis mucosa and muscularis propria). The stained tumor samples were numbered and assessed by pathologist who used light microscopy to determine the following goals:

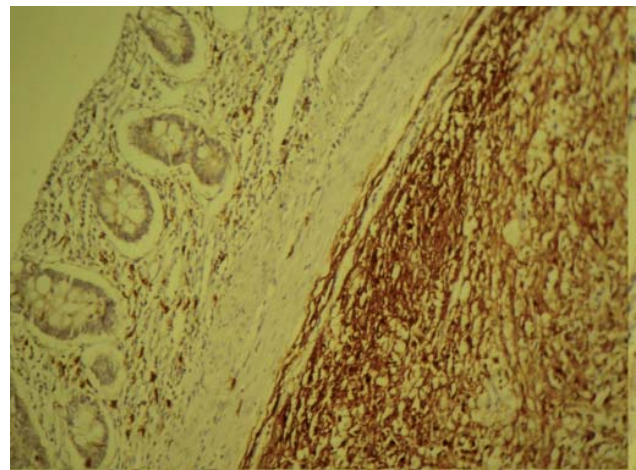
- Presence (+) or absence (-) of CD117 immunostaining
- Expression location (cell membrane, cytoplasm, cell processes, nucleus)

- Expression intensity (weak, strong)
- Percent of positively-stained cells (expression grade: 0=0%, 1+=1-10%, 2+=11-50%, 3+=51-75%, 4+>75%)

The comparison of CD117 expression between high and low-grade tumors was evaluated with SPSS V16 soft ware and Chi square test.

**Results**

We first assessed GIST sample for the evaluation of the immunohistochemical staining quality used in the present study. The most convincing pattern of CD117 positivity is on featuring a membrane component in addition to a cytoplasmic one (18). CD117 immunoreactivity of the GIST sample was shown in Fig. 1.



**Fig. 1:** CD117 immunostaining in a gastrointestinal stromal tumor(GIST), reveals strong and diffuse cytoplasmic and membranous staining pattern. Internal positive controls, the interstitial cells of Cajal are also strongly stained (long arrows), whereas the internal negative control, muscularis mucosa, is not stained (short arrows). (original magnification × 100)

CD117 positivity was detected in 29 of the 69 tumor cases. There was a statistically significant difference in CD117 expression between high and low grade tumors (61% versus 21.2% , P=0.001) (Table 1).

**Table 1:** CD117 expression in high grade and low grade glial tumors

Tumor grade	Low grade			High grade		
	CD117+	CD117-	Total	CD117+	CD117-	Total
<b>Tumor type</b>						
<b>Astrocytoma</b>	4	21	25	13	11	24
<b>Oligodendroglioma</b>	1	4	5	4	2	6
<b>Ependymoma</b>	2	1	3	5	1	6
<b>Total</b>	7 (21.2%)	26 (78.8%)	33 (100%)	22 (61.1%)	14 (38.9%)	36 (100%)

**Pearson Chi- Square=** 11.249

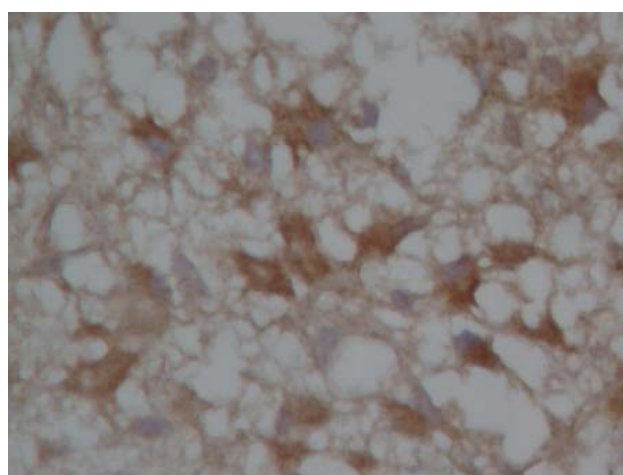
The staining intensity was strong in 27 cases and weak in one ependymoma and one astrocytoma. The staining grade ranged from 1+ to 4+ (Table 2).

**Table 2:** CD117 staining grades in glial tumors

CD117 expression grade*	0	1+	2+	3+	4+
Tumor type					
<b>Glioblastoma</b>	8	7	1	1	
<b>Anaplastic astrocytoma</b>	3	3	1		
<b>Well differentiated astrocytoma</b>	17	1	3		
<b>Pilocytic astrocytoma</b>	4				
<b>Anaplastic oligodendroglioma</b>	2	2	1		1
<b>Oligodendroglioma</b>	4				1
<b>Anaplastic ependymoma</b>	1	2	2	1	
<b>Ependymoma</b>	1	2			

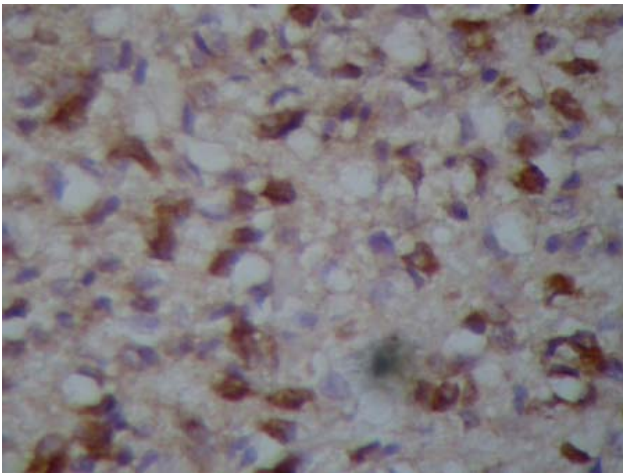
\*Staining grade ( percent of positive cells ) was scored as: 0=0%, 1+= 1-10%,2+= 11-50%, 3+= 51-75%, 4+> 75%

Except for one case of oligodendroglioma, the highest expression grades belonged to high grade tumors (Glioblastoma, anaplastic oligodendroglioma and anaplastic ependymoma). In nearly all tumors, CD117 staining was mainly diffuse cytoplasmic, often with higher and irregular expression levels evident at or near periphery of the cells, as expected for a membrane-bound receptor. These characteristics agree with those of the GIST and previous observation in brain tumors (3, 9, 19). For example, glioblastoma had particularly strong staining that frequently predominated in the periphery of the cells and cell processes (Fig. 2), whereas astrocytoma were less intensely stained and staining of processes were also evident. In two cases of astrocytoma the cytoplasmic staining had focal punctuate accentuation, which is also evident in GISTs and other tumors (20-22).



**Fig. 2:** CD117 immunoreactivity in glioblastoma. Neoplastic cells have strong cytoplasmic, membranous and cell processes staining. (original magnification × 400)

Anaplastic oligodendroglioma had sparse cytoplasm; therefore, CD117 immunoreactivity appeared as a ring around the nucleus of the cells (Fig. 3).



**Fig. 3:** CD117 staining in anaplastic oligodendroglioma. (original magnification  $\times 400$ )

Another important finding was that in 18 cases, the CD117 was expressed in endothelial cells of tumor vessels (Fig. 4). Sixteen of them were in proliferated endothelial cells of high-grade tumors and most with strong intensity. In 16 of the 18 cases, the CD117 was expressed in tumor cells as well. In addition, CD117 immunoreactivity was detected in severely gliotic tissues surrounding the tumor and in neurons of normal cortex.

### Discussion

The gliomas are the most common primary tumors of the central nervous system (2) and their overall prognosis is poor (23), thus any effort for finding of novel therapies is indicated.

In this study, CD117 immunoreactivity was detected in 42% of gliomas that ranged from 16% to 75% in different previous studies (3,4,9-12,24-26), including the study of Cetin *et al* that found CD117 immunoreactivity in 75% of 52 assessed glial tumors (3) and another on 179 gliomas of different types and grades with positivity rate of 15.6% (4). This wide range of positivity can arise from different properties of commercial antibodies, the dilution used in staining, antigen retrieval procedures or other issues. In the present study, the DAKO rabbit anti-human CD117 antibody, which is reported to have a higher sensitivity compared to the Santa Cruz antibody for other types of tumors (21, 27), was used at a 1/400 dilution after antigen retrieval treatment.

High-grade tumors had a higher proportion of

CD117 expression than low grade ones as in the previous studies (3, 9, 26). All three major types of gliomas expressed CD117 and the highest staining grades were found in glioblastomas, anaplastic oligodendrogliomas, and anaplastic ependymomas. Similar results achieved in Cetin *et al* study for glioblastomas and anaplastic oligodendrogliomas (3). In our study, none of four pilocytic astrocytomas was CD117 immunoreactive as in Cetin *et al* study (3). The high-grade gliomas, especially glioblastoma, associated with a poor prognosis even after optimal treatment with function-saving surgical resection followed by both radiation and chemotherapy (16), thus nowadays many investigations have focused on identifying target therapies. Our results also directed to this goal. In two studies the CD117 immunoreactivity was detected in endothelial cells of tumor vessels, especially in high grade ones. One of them was Gomes *et al* study that they found CD117 staining in 22.3% of gliomas. In our study, CD117 immunoreactivity was detected in endothelial cells of tumor vessels in 26.1% of cases that 88.9% of them were in high grade ones.

The results of this and previous studies (7, 9, 11, 12, 25, 26) suggest that CD117 may play a role in gliomagenesis and it may open new therapeutic approaches for treatment of gliomas. As only a fraction of patients seems to benefit from imatinib mesylate therapy and due to potential side effects and high costs of this therapy, selection of the appropriate patients is important. In several trial studies the effect of imatinib therapy for treatment of glioblastomas was investigated (14-16) and preclinical studies provide evidence that imatinib increases the chemo or radiosensitivity of glioblastoma cells in culture (28-32) suggesting that imatinib may enhance the activity of chemotherapeutic agents used to treat glioblastomas.

### Conclusion

Regarding to the CD117 immunoreactivity in glial tumors and the significant difference in its expression between high and low grade tumors, we concluded that CD117 has an important role in growth of glial tumors, especially high grade ones. Therefore, patients with CD117 expressing glial tumors might benefit from

tyrosine kinase inhibitors similar to patients with GISTs. However, more universal studies in the immunohistochemical and molecular levels evaluation of responsiveness to tyrosine kinase inhibitor therapy should be conducted.

### Acknowledgment

This study was supported by grants from the Vice Chancellorship for Research, Hamedan University of Medical Sciences, Iran as a residential thesis. The authors thank pathology technicians of Noor Pathobiology Laboratory, Tehran, Iran for technical assistance. The authors declare that they have no conflicts of interest.

### References

1. Morini M, Bettini G, Preziosi R, Mandrioli L. C-kit gene product (CD117) immunoreactivity in canine and feline paraffin sections. *J Histochem Cytochem* 2004;52(5):705-8.
2. Babbs D. Selected reviews on topics in oncologic pathology related to tumors of the breast, gynecologic organs, and head and neck region. 2nd ed. Philadelphia: Churchill Livingstone; 2006.
3. Cetin N, Dienel G, Gokden M. CD117 expression in glial tumors. *J Neurooncol* 2005;75(2):195-202.
4. Gomes AL, Reis-Filho JS, Lopes JM, Martinho O, Lambros MB, Martins A, et al Molecular alterations of KIT oncogene in gliomas. *Cell Oncol* 2007;29(5):399-408.
5. Zhang SC, Fedoroff S. Cellular localization of stem cell factor and c-kit receptor in the mouse nervous system. *J Neurosci Res* 1997;47(1):1-15.
6. Jin K, Mao XO, Sun Y, Xie L, Greenberg DA. Stem cell factor stimulates neurogenesis in vitro and in vivo. *J Clin Invest* 2002;110(3):311-9.
7. Blom T, Fox H, ngers-Loustau A, Peltonen K, Kerosuo L, Wartiovaara K, et al KIT overexpression induces proliferation in astrocytes in an imatinib-responsive manner and associates with proliferation index in gliomas. *Int J Cancer* 2008;123(4):793-800.
8. Hamel W, Westphal M. The road less travelled: c-kit and stem cell factor. *J Neurooncol* 1997;35(3):327-33.
9. Kristt DA, Reedy E, Yarden Y. Receptor tyrosine kinase expression in astrocytic lesions: similar features in gliosis and glioma. *Neurosurgery* 1993;33(1):106-15.
10. Matsuda R, Takahashi T, Nakamura S, Sekido Y,

Nishida K, Seto M, et al Expression of the c-kit protein in human solid tumors and in corresponding fetal and adult normal tissues. *Am J Pathol* 1993;142(1):339-46.

11. Puputti M, Tynninen O, Sihto H, Blom T, Maenpaa H, Isola J, et al Amplification of KIT, PDGFRA, VEGFR2, and EGFR in gliomas. *Mol Cancer Res* 2006;4(12):927-34.

12. Haberler C, Gelpi E, Marosi C, Rossler K, Birner P, Budka H, et al Immunohistochemical analysis of platelet-derived growth factor receptor-alpha, -beta, c-kit, c-abl, and arg proteins in glioblastoma: possible implications for patient selection for imatinib mesylate therapy. *J Neurooncol* 2006;76(2):105-9.

13. Kilic T, Alberta JA, Zdunek PR, Acar M, Iannarelli P, O'Reilly T, et al Intracranial inhibition of platelet-derived growth factor-mediated glioblastoma cell growth by an orally active kinase inhibitor of the 2-phenylaminopyrimidine class. *Cancer Res* 2000;60(18):5143-50.

14. Brooks BJ, Bani JC, Fletcher CD, Demeteri GD. Challenges in oncology. Case 4. Response of metastatic gastrointestinal stromal tumor including CNS involvement to imatinib mesylate (STI-571). *J Clin Oncol* 2002;20(3):870-2.

15. McLaughlin ME, Robson CD, Kieran MW, Jacks T, Pomeroy SL, Cameron S. Marked regression of metastatic pilocytic astrocytoma during treatment with imatinib mesylate (STI-571, Gleevec): a case report and laboratory investigation. *J Pediatr Hematol Oncol* 2003;25(8):644-8.

16. Dresemann G. Imatinib and hydroxyurea in pretreated progressive glioblastoma multiforme: a patient series. *Ann Oncol* 2005;16(10):1702-8.

17. Smith C, Ironside J. Diagnosis and pathogenesis of gliomas. *Current Diag Pathol* 2007;13(3):180-92.

18. Rosai J. Ackerman's Surgical Pathology. 9 ed. New York: Mosby; 2004.

19. Miyano-hara O, Takeshima H, Kaji M, Hirano H, Sawamura Y, Kochi M, et al Diagnostic significance of soluble c-kit in the cerebrospinal fluid of patients with germ cell tumors. *J Neurosurg* 2002;97(1):177-83.

20. Hornick JL, Fletcher CD. Validating immunohistochemical staining for KIT (CD117). *Am J Clin Pathol* 2003;119(3):325-7.

21. Lucas DR, al-Abbadi M, Tabaczka P, Hamre MR, Weaver DW, Mott MJ. c-Kit expression in desmoid fibromatosis. Comparative immunohistochemical evaluation of two commercial antibodies. *Am J Clin Pathol* 2003;119(3):339-45.

22. Sabah M, Leader M, Kay E. The problem with KIT: clinical implications and practical difficulties with CD117 immunostaining. *Appl Immunohistochem Mol Morphol* 2003;11(1):56-61.
23. Lallana EC, Abrey LE. Update on the therapeutic approaches to brain tumors. *Expert Rev Anticancer Ther* 2003;3(5):655-70.
24. Natali PG, Nicotra MR, Sures I, Santoro E, Bigotti A, Ullrich A. Expression of c-kit receptor in normal and transformed human nonlymphoid tissues. *Cancer Res* 1992 Nov 15;52(22):6139-43.
25. Stanulla M, Welte K, Hadam MR, Pietsch T. Coexpression of stem cell factor and its receptor c-Kit in human malignant glioma cell lines. *Acta Neuropathol* 1995;89(2):158-65.
26. Mennel HD, Hallier-Neelsen M, Hagner S, Benes L. Two novel cell specific receptor proteins, CRLR and CD 117 in human glial tumors. *Clin Neuropathol* 2006;25(3):107-14.
27. Lonardo F, Pass HI, Lucas DR. Immunohistochemistry frequently detects c-Kit expression in pulmonary small cell carcinoma and may help select clinical subsets for a novel form of chemotherapy. *Appl Immunohistochem Mol Morphol* 2003;11(1):51-5.
28. Holdhoff M, Kreuzer KA, Appelt C, Scholz R, Na IK, Hildebrandt B, et al Imatinib mesylate radiosensitizes human glioblastoma cells through inhibition of platelet-derived growth factor receptor. *Blood Cells Mol Dis* 2005;34(2):181-5.
29. O'Reilly T, Wartmann M, Maira SM, Hattenberger M, Vaxelaire J, Muller M, et al Patupilone (epothilone B, EPO906) and imatinib (STI571, Glivec) in combination display enhanced antitumour activity in vivo against experimental rat C6 glioma. *Cancer Chemother Pharmacol* 2005;55(4):307-17.
30. Katayama R, Huelsmeyer MK, Marr AK, Kurzman ID, Thamm DH, Vail DM. Imatinib mesylate inhibits platelet-derived growth factor activity and increases chemosensitivity in feline vaccine-associated sarcoma. *Cancer Chemother Pharmacol* 2004;54(1):25-33.
31. Aloyz R, Grzywacz K, Xu ZY, Loignon M, Aouf-Jamali MA, Panasci L. Imatinib sensitizes CLL lymphocytes to chlorambucil. *Leukemia* 2004;18(3):409-14.
32. Kano Y, Akutsu M, Tsunoda S, Mano H, Sato Y, Honma Y, et al. In vitro cytotoxic effects of a tyrosine kinase inhibitor STI571 in combination with commonly used antileukemic agents. *Blood* 2001;97(7):1999-2007.