

## Original Article

### Surgical Histopathology of Benign Ovarian Cysts: A Multicentre Study

Maliheh Arab<sup>1</sup>, Mohammad Hashemi<sup>2</sup>, Nadereh Masoumi<sup>1</sup>  
Mehdi Yaseri<sup>3</sup>, Farzaneh Golfam<sup>4</sup>, Mojgan Ebrahimi<sup>5</sup>

1. Dept. of Gynecology and Obstetrics, Shahid Beheshti University of Medical Sciences, Tehran , Iran
2. Dept. of Pathology, Shahid Beheshti University of Medical Sciences, Tehran , Iran
3. Dept. of Epidemiology and Biostatistics, Tehran university of Medical Sciences, Tehran , Iran
4. Dept. of Surgery, Shahed university, Tehran, Iran
5. Dept. of Pathology, Hamadan University of Medical Sciences, Hamadan. Iran

#### ABSTRACT

**Background and Objective:** Ovarian tumors are among the most frequent pathologic conditions in gynecologic practice and a frequent cause of hospitalization and surgery. The aim of this study was to determine histologic distribution of benign operated masses especially functional ovarian cysts.

**Material and Methods:** Benign ovarian files of operated patients (2961 cases) in 20 tertiary and secondary hospitals were reviewed regarding age and histopathology from 1998- 2005. Analysis was done by SPSS software (version 13).

**Results:** The most common benign histologies in order of frequency were functional cyst (57%), serous cystadenoma (13%), dermoid cyst (10%), mucinous cystadenoma (7%) and endometrioma (6%).

**Conclusion:** Functional cysts were the most common benign ovarian cyst. Nearly high distribution of functional cysts in the present study may be an index of need to management improvement and less surgical decisions in ovarian tumors.

**Key words:** Ovarian cyst, Endometrioma, Operations, Iran

---

Received: 13 September 2009

Accepted: 16 December 2009

Address communications to: Dr Maliheh Arab, Department of Gynecology and Obstetrics, Shahid Beheshti University of Medical Sciences, Tehran, Iran

Email: drmarab@yahoo.com

## Introduction

Ovarian tumors are among the most frequent pathologic conditions in gynecologic practice and a frequent cause of hospitalization and surgery (1).

Ovarian masses are a common occurrence in women of all age groups, with approximately 8% of asymptomatic women aged 25 to 40 yr who were randomly sampled from a population registry having a cyst larger than 2.5 cm. Most ovarian tumors are benign (2). Another study found that of women aged 50 yr and older, 18% had a finding of a unilocular ovarian cyst of 10 cm or Less (3). Simple ovarian cysts are much more common in postmenopausal women that previously had been thought. The available studies give prevalence rates between 3.3% and 14.8% (4-9).

Given these findings, all practitioners who care for women will, at some point in their careers, encounter the finding of an ovarian mass. Ovarian masses often are asymptomatic and found at the time of routine health care visits, during screening for other unrelated complaints, or when evaluating a specific gynecologic complaint (10). The vast majority of ovarian cysts in women of reproductive age are physiological (Functional), either follicular cysts or cystic corpus luteum (11).

Most clinicians who are faced with an ovarian tumor would recommend surgery or expectant management depending on the clinical complaints and the presumed nature of the lesion (12). Surgical management, in order to early diagnosis and aggressive treatment may improve survival of ovarian cancer especially in younger patients (below 45 yr old) (13).

In contrast, surgical management of functional cysts (luteal mass or simple cyst) may not be beneficial in comparison with either medical treatment in the case of a luteal mass or expectant management in cases of a simple cyst (14, 15).

Many functional ovarian cysts can be managed conservatively with observation and sometimes pain control (16). A thorough knowledge of the spectrum of

ovarian disorders is essential to assist care providers in targeted evaluation and appropriate management and referrals.

The purpose of this study was to define distribution of benign histologies in operated ovarian masses as an index of appropriate clinical management and surgical interventions in ovarian cysts, especially functional masses.

## Material and Methods

Ovarian histopathology files of 20 tertiary and secondary care hospitals were included in this multicentre study from 1998-2005. Seventeen out of 20 hospitals were in Tehran, Iran and the other three in Hamadan Province located in the western region of Iran. Participating hospitals included 18 academic and 2 non- academic, but under university surveillance, as well.

Hospitals were under the domain of seven universities including Shahid Beheshti, Tehran, Iran, Hamadan, Shahed, Azad and Baghiatallah. All benign ovarian histology files of patients operated on due to ovarian mass were selected. Referring to their documented database, age and histology were recorded. Analysis was done by SPSS software (version 13).

## Results

Among 3303 ovarian histopathology files, excluding malignant, borderline, metastatic and unspecified cases, remaining 2961 benign ovarian histologies included in the study.

The mean age of the patients as a whole was 34 yr old. The mean and median age of patients, and different histologies are shown in Table 1.

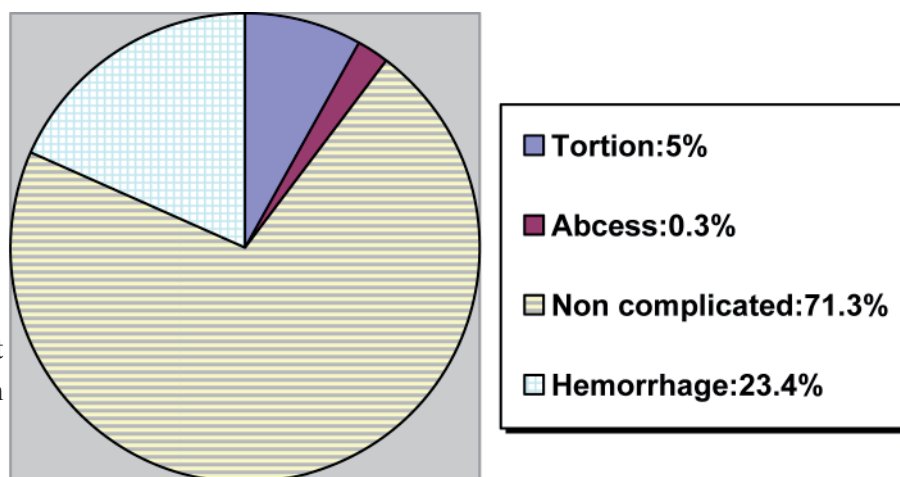
Hemorrhage as the most common complication of benign ovarian cysts was revealed in 694 out of 2961 benign ovarian cysts, followed by 178 torsion and 11 abscess cases (Fig.1)

**Table1:** Distribution of different surgical histopathologies in benign ovarian masses

|                             | Frequency N (%) | Age  |        |
|-----------------------------|-----------------|------|--------|
|                             |                 | Mean | Median |
| <b>Functional cyst</b>      | 1691(57.1)      | 33   | 30     |
| <b>Serous cystadenoma</b>   | 390 (13.1)      | 40   | 40     |
| <b>Mucinous cystadenoma</b> | 222(7.4)        | 37   | 35     |
| <b>Dermoid cyst</b>         | 304 (10.2)      | 32   | 30     |
| <b>Endometrioma</b>         | 177 (5.9)       | 33   | 32     |
| <b>Tortion (NS)*</b>        | 70 (2.3)        | 28   | 25     |
| <b>Abscess</b>              | 11 (0.37)       | 38   | 37     |
| <b>Adenofibroma</b>         | 48 (1.6)        | 38   | 34     |
| <b>Fibro- Thecoma</b>       | 48 (1.6)        | 43   | 46     |
| <b>Total</b>                | 2961 (100)      |      |        |

\*NS: Histology of cyst is unspecified or no cyst is defined

**Fig. 1-** Distribution of different complicated cysts in benign ovarian surgical histopathologies



## Discussion

The most common benign ovarian mass in the present study was functional cyst (57%), followed by serous cystadenoma (13%) and dermoid cyst (10%) (Table 1). Results of two other studies first in Netherlands including 463 (Mean age=39 yr) and second in Italy including 98 benign ovarian masses, Presented histology of patients which are

compared with our results in table 2 (17, 18). In Netherlands study the most common histopathology was endometrioma (29%) followed by dermoid cyst (24%) and functional cyst (19%). In Italian study the most common histology was endometrioma (19%) followed by functional cyst (18%).

In review of results, it should be kept in mind that studied population had been operated patients.

**Table2:** Frequency comparison of some benign ovarian surgical histopathologies in Iran, Netherland and Italy

|                              | Iran N (%) | Netherlands N (%) | Italy N (%) |
|------------------------------|------------|-------------------|-------------|
| <b>Functional cyst</b>       | 1691(57.1) | 89(19.3)          | 18(18.3)    |
| <b>Serous cystadenoma</b>    | 390 (13.1) | 51(11)            | 7(7.1)      |
| <b>Mucinous cystadenoma</b>  | 222(7.4)   | 58(12.5)          | 5(5.1)      |
| <b>Dermoid cyst</b>          | 304 (10.2) | 110(23.8)         | 7(7.1)      |
| <b>Endometrioma</b>          | 177 (5.9)  | 135 (29.2)        | 19(19.4)    |
| <b>Others (non selected)</b> | 177 (5.9)  | 18 (3.9)          | 41 (41.8)   |
| <b>Total</b>                 | 2961 (100) | 461 (100)         | 98 (100)    |

In another study in lahore on 110 operated patients with mean age of 36 yr, histopathology of benign tumors revealed follicular/ luteal cyst in 32% and serous cystadenoma in 23% (19,20), more close to our results.

Follicular cysts are the most common cystic structures seen on the normal ovary (21). Follicular cyst is the most common functional cyst (15) and most of them are asymptomatic. More than 70-80% resolves spontaneously (22). Corpus luteum cyst develop from mature postovulatory follicle. Two to 3 days after ovulation spontaneous bleeding fills the cavity of corpus luteum and enlarging the size, cause pain (21).

It is confirmed again that if the guidelines of operation were easy in management of a cyst associated with pain, it would change the histopathology of cases in favor to functional cyst (mostly luteal). If there is more strict criteria and if a period of observation and pain relief to rule out torsion is considered, histopathology of operated cases would change in favor of neoplastic and persistent ones. Dermoid cyst represented 62% of all ovarian neoplasms younger than 40 years of age (23-25).

In our study, the most common benign neoplastic histology of ovary was serous cystadenoma (13%) followed by dermoid cyst (10%) which was similar to general literature consideration (23). However, in one study dermoid cyst represented 66% of benign tumors in women younger than 40 years of age: serous tumors accounted for only 20% (23).

A limitation of this research should be noted. The histologic diagnoses of cases in this study were made in numerous locations by many different pathologists. Since there was no referral pathologic review in this study, we cannot exclude the possibility that some of the histologic diagnoses may be incorrect.

## Conclusion

Benign adnexal cysts are frequently encountered in pre and postmenopausal patients and most of them are functional, resolving spontaneously just by observation. In case of mild pain, analgesia and observation would avoid surgery in functional

cysts. To rule out torsion in suspicious cases, as an emergency setting, laparoscopy would aid. Nearly high distribution of functional ovarian cysts in surgical histopathology of benign ovarian masses in this study, that is 57%, in comparison to 18.8%, 19.3% and 32% in Italy, Netherlands and Lahore, respectively maybe an index of need to management improvement and less surgical decisions in ovarian tumors.

## Acknowledgements

Cost of this research have been paid by the authors. The authors declare that they have no conflicts of interest.

## References

1. Valentin L, Ameye L, Jurkovic D, Metzger U, Lecuru F, Van HS, et al Which extrauterine pelvic masses are difficult to correctly classify as benign or malignant on the basis of ultrasound findings and is there a way of making a correct diagnosis? *Ultrasound Obstet Gynecol* 2006;27(4):438-44.
2. Borgfeldt C, Andolf E. Transvaginal sonographic ovarian findings in a random sample of women 25-40 years old. *Ultrasound Obstet Gynecol* 1999;13(5):345-50.
3. Modesitt SC, Pavlik EJ, Ueland FR, DePriest PD, Kryscio RJ, van NJ, Jr. Risk of malignancy in unilocular ovarian cystic tumors less than 10 centimeters in diameter. *Obstet Gynecol* 2003;102(3):594-9.
4. Oyelese Y, Kueck AS, Barter JF, Zalud I. Asymptomatic postmenopausal simple ovarian cyst. *Obstet Gynecol Surv* 2002;57(12):803-9.
5. Wolf SI, Gosink BB, Feldesman MR, Lin MC, Stuenkel CA, Braly PS, et al Prevalence of simple adnexal cysts in postmenopausal women. *Radiology* 1991;180(1):65-71.
6. Conway C, Zalud I, Dilella M, Maulik D, Schulman H, Haley J, et al Simple cyst in the postmenopausal patient: detection and management. *J Ultrasound Med* 1998;17(6):369-72.
7. Andolf E, Jorgensen C. Simple adnexal cysts diagnosed by ultrasound in postmenopausal women. *J Clin Ultrasound* 1988;16(5):301-3.
8. Aubert JM, Rombaut C, Argacha P, Romero F, Leira J, Gomez-Bolea F. Simple adnexal cysts in postmenopausal women: conservative management. *Maturitas* 1998;30(1):51-4.
9. Bailey CL, Ueland FR, Land GL, DePriest PD,

Gallion HH, Kryscio RJ, et al The malignant potential of small cystic ovarian tumors in women over 50 years of age. *Gynecol Oncol* 1998;69(1):3-7.

10. Barney SP, Muller CY, Bradshaw KD. Pelvic masses. *Med Clin North Am* 2008;92(5):1143-61, xi.

11. De WR, Bordt J, Hesselting M, Vancaillie T. Ovarian cystostomy. *Acta Obstet Gynecol Scand* 1989;68(4):363-4.

12. Curtin JP. Management of the adnexal mass. *Gynecol Oncol* 1994;55(3 Pt 2):S42-S46.

13. Arab M, Khayamzadeh M, Mohit M, Hosseini M, Anbiaee R, Tabatabaefar M, et al Survival of ovarian cancer in Iran: 2000-2004. *Asian Pac J Cancer Prev* 2009;10(4):555-8.

14. Eriksson L, Kjellgren O, von SB. Functional cyst or ovarian cancer: histopathological findings during 1 year of surgery. *Gynecol Obstet Invest* 1985;19(3):155-9.

15. MacKenna A, Fabres C, Alam V, Morales V. Clinical management of functional ovarian cysts: a prospective and randomized study. *Hum Reprod* 2000;15(12):2567-9.

16. Stany MP, Hamilton CA. Benign disorders of the ovary. *Obstet Gynecol Clin North Am* 2008;35(2):271-84, ix.

17. de Kroon CD, van der Sandt HA, van Houwelingen JC, Jansen FW. Sonographic assessment of non-malignant ovarian cysts: does sonohistology exist? *Hum Reprod*

2004;19(9):2138-43.

18. Guerriero S, Alcazar JL, Pascual MA, Ajossa S, Gerada M, Bargellini R, et al Diagnosis of the most frequent benign ovarian cysts: is ultrasonography accurate and reproducible? *J Womens Health (Larchmt)* 2009;18(4):519-27.

19. Wasim T, Majrroh A, Siddiq S. Comparison of clinical presentation of benign and malignant ovarian tumours. *J Pak Med Assoc* 2009;59(1):18-21.

20. Gupta N, Bisht D, Agarwal AK, Sharma VK. Retrospective and prospective study of ovarian tumours and tumour-like lesions. *Indian J Pathol Microbiol* 2007;50(3):525-7.

21. Mishell DRJ. *Comprehensive gynecology*. 4 ed. ST louis : Mosby; 2001.

22. Tanos V, Schenker JG. Ovarian cysts: a clinical dilemma. *Gynecol Endocrinol* 1994;8(1):59-67.

23. Koonings PP, Campbell K, Mishell DR, Jr., Grimes DA. Relative frequency of primary ovarian neoplasms: a 10-year review. *Obstet Gynecol* 1989;74(6):921-6.

24. Kozłowski KJ. Ovarian masses. *Adolesc Med* 1999;10(2):337-50, vii.

25. DiSaia P, Creasman W. *Clinical Gynecologic Oncology*. 7th ed. ST louis : Mosby; 2007.