

Case Report

Endometrial Stromal Nodule

Safia Rana¹, Zeeba Jairajpuri¹, Rashmi Tiwari²

1. Dept. of Pathology, Hamdard Institute of Medical Sciences and Research, New Delhi, India

2. Dept. of Pathology, Kasturba Hospital, New Delhi, India

ABSTRACT

The endometrial stromal nodule is a benign tumor composed of differentiated endometrial stromal cells arranged as a well circumscribed nodule with smooth non-invasive margins. They are rare neoplasms, diagnosed in most instances by microscopy. Although nodules are benign in nature, hysterectomy is the treatment of choice to enable evaluation of the tumor margins which are well demarcated in endometrial stromal nodule and infiltrative in low grade endometrial stromal sarcoma. We present here a case of a 46 year old female with history of menorrhagia and a preoperative clinical diagnosis of uterine leiomyoma followed by a definitive diagnosis of endometrial stromal nodule. Experience with endometrial stromal nodule is limited, hence we emphasize on the fact that these are rare and benign tumours which should be distinguished from other invasive malignant stromal tumors with a more sinister prognostic course.

Keywords: Endometrial Stromal Tumor, Case Report, India

Introduction

Endometrial stromal tumors (EST) are very rare mesenchymal tumors of the uterus and are divided according to the recent WHO classification into three groups including benign endometrial stromal nodule (ESN), low grade endometrial stromal sarcoma (LGESS) and undifferentiated endometrial sarcoma (UES) (1). They are among the least common

neoplasms of the uterine corpus accounting for 2 per million women (1-3). Benign ESN is a rare subtype accounting for one fourth of EST which consist of less than 5% of uterine tumors (4,5). It is composed of well differentiated endometrial stromal cells arranged as a circumscribed nodule with smooth non-invasive margins. They are rare neoplasms, diagnosed in most instances by light microscopy. Diagnosis of the uterine mesenchymal tumors is challenging, particularly

Received: 09 February 2012

Accepted: 07 July 2012

Address communications to: Dr Safia Rana, Department of Pathology, Hamdard Institute of Medical Sciences and Research, New Delhi, India

Email: safia_rana2000@yahoo.com

with respect to prediction of their biological behavior. More so, overlapping morphology of ESN and LGESS warrants careful differentiation between the two. It is emphasized that ESN is an indolent disease which needs to be distinguished from other stromal sarcomas, hence influence the final prognosis (2).

Case Report

A 46 year old lady presented with menorrhagia and dull abdominal pain of 2 months duration. Complete blood count and hematological investigations were normal. Serum T3 T4 and TSH were within normal limits. Abdominal ultrasound showed a heterogenous but a well circumscribed mass, measuring 4.6×4.8 cm and a diagnosis of intramural leiomyoma was made. Laparotomy was performed to evaluate the nature of the mass. Abdominal hysterectomy was done, considering clinical diagnosis of leiomyoma and the age of the patient, salpingo-oophorectomy was not done. Grossly, uterus showed a well circumscribed intramural nodule measuring 5x5cm² which on cut section showed homogenous, yellowish white, soft to firm area (Fig. 1). It was well demarcated with defined margins with respect to the adjoining myometrium. Microscopically, tumor showed well delineated margins, compressing the surrounding myometrium (Fig. 2). Lesion showed cells with uniform, small round nuclei with granular chromatin and inconspicuous nucleoli resembling normal proliferative phase endometrial stromal cells. Areas of epitheloid like structures, specified by sex cord pattern were also identified (Fig. 3). Based on the characteristic histopathological findings a diagnosis of ESN was made. Since limited resources are available at our institute, Immunohistochemistry (IHC) was referred at another centre. Due to constraints of limited availability of relevant antibodies and financial support, only CD10 marker was done which showed diffuse positivity, consistent with ESN.

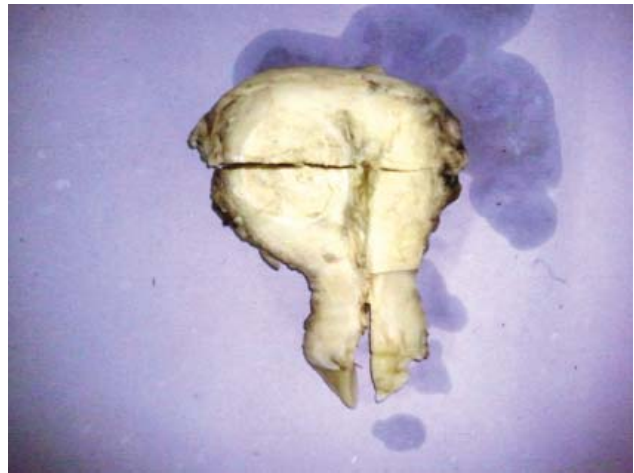

Fig. 1- Gross picture of hysterectomy specimen showing a well circumscribed, intramural, yellowish white nodule (Original)

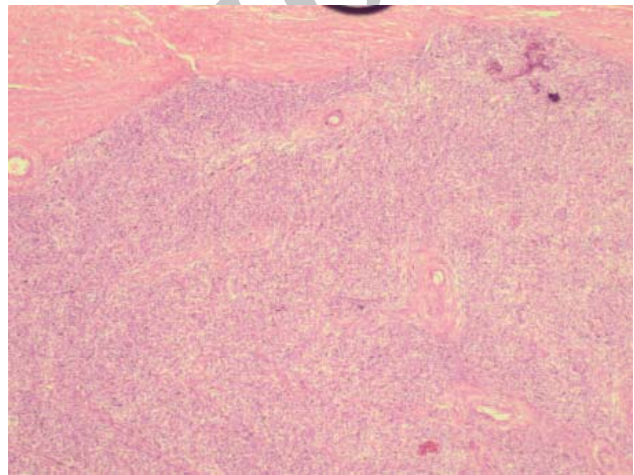


Fig. 2- Microphotograph showing expansile margin, and sharp demarcation between ESN and the adjoining myometrium (H&E, ×10) (Original)

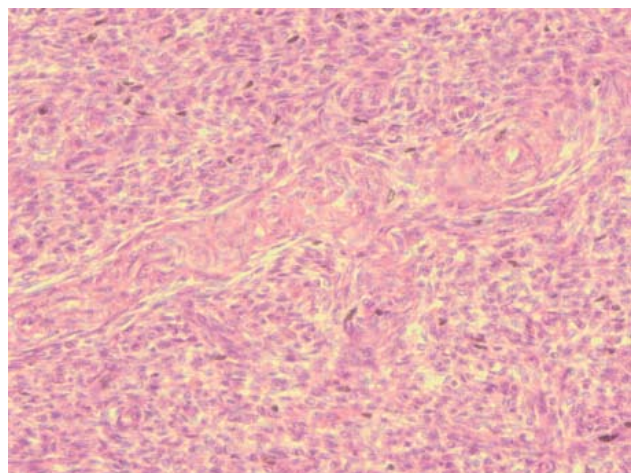


Fig. 3- Microphotograph showing epitheloid differentiation, specified by sex cord pattern (H&E, ×40) (Original)

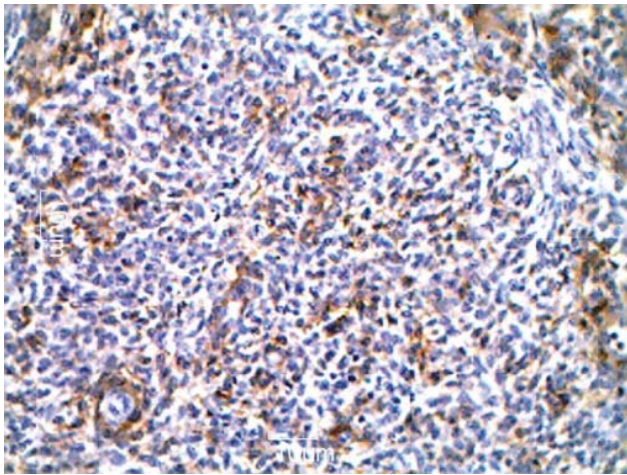


Fig. 4- Microphotograph showing diffuse CD10 positivity (IHC×10) (Original)

Discussion

Endometrial stromal tumors are mesenchymal tumors of the uterus with cytological and architectural features reminiscent of endometrial stromal cells. ESN is a rare subtype. The lesion although having been known for years, has rarely been reported in literature. By definition, ESN are circumscribed stromal tumors composed of cells with uniform nuclei, occasional mitosis and scant cytoplasm, resemblance to cells of normal proliferative phase of endometrial stroma is prominent. Stromal cells showing areas of epithelial like structures reminiscent of an ovarian sex cord stromal tumor may also be seen (6). The present case fitted well into the definition and showed sex cord stromal tumour epithelial like structures as well. Similarly, Elagoz *et al.* described three cases of ESN with similar well circumscribed smooth and expansile margin as other studies (2-4, 6). Although classically described as a well circumscribed lesion, focal irregularities or finger like projections into the myometrium are known to occur with minimal infiltration not exceeding 2 to 3 mm (6-8). Although such irregularities were not seen in the discussed case, Elagoz *et al.* have reported one such case (3). It has been recommended that such tumors should be diagnosed as EST with limited

infiltration and separated from conventional ESN and LGESS. Three such cases have been reported by Dionigi *et al.* (6).

ESNs are known to occur primarily in the peri and postmenopausal age group; one study reported a mean age of 47 years while others have described it to be 53 years (6, 8). Our patient, a 46 year old female too, was in the perimenopausal age group. In another report, a 49 year old presented with abdominal pain and menorrhagia (9). Clinically, the presentation is varied and nonspecific at times with majority of the patients presenting as abnormal bleeding along with abdominal discomfort or pain, anemia being a common complication (4, 8). The clinical presentation of our case too was that of menorrhagia with dull abdominal pain, however anemia was not seen. Contrary to this, Alauli Fdili *et al.* reported a painless abdominal mass without abnormal bleeding (2).

Our patient had a clinical suspicion of leiomyoma as had also been seen in other reports (2-4). The most common preoperative diagnosis in EST is of leiomyoma and adnexal masses (3).

Differential diagnosis of an ESN depends primarily on the microscopic findings, comprising mainly of LGESS and cellular leiomyoma (9). Both ESN and LGESS tumors have similar presentation, vaginal bleeding is the most common however LGESS may present with extra uterine spread (10). Microscopic appearances of LGESS and ESN are similar; however difference between the two is of utmost importance keeping in view the clinical behavior. ESN is a grossly well delineated tumor with expansile growth at its margins (8), minor irregularities are common but without invasion. It is composed of small uniform closely packed cells with cytological atypia and mitosis being minimal, while, LGESS has an infiltrating border with myometrial invasion and metastasis beyond the uterus and/

or with recurrence (5). Myometrial and vascular invasion are the two most important features to distinguish these two tumors. In most cases it is impossible to differentiate between an ESN and LGESS on the basis of curettage specimens thus a confident diagnosis can only be made on hysterectomy specimen. More so, authors have recommended that ESN with little irregularity need to be distinguished from LGESS with limited infiltration an entity described recently (6). Extensive sampling is necessary to avoid an erroneous diagnosis. Knowledge of clinical behavior is limited hence currently these are best reported as LGESS with invasion but may behave in a more benign manner (6).

Cellular leiomyomas, another important differential diagnosis, grossly have an appearance that closely overlaps with those of ESN. They have a yellow tan appearance with soft consistency similar to ESN. Microscopically, cellular leiomyomas are composed of spindle shaped cells, fascicular growth, thick walled vessels, cleft like spaces and merging with myometrium. These features are lacking in ESN. The discussed case too had a yellowish gross appearance but the microscopic findings were characteristically those of ESN. Since both the lesions are benign distinguishing between the two is not significant in hysterectomy specimen, However in curettage specimens distinction between the two is impossible, hence in order to avoid missing EST, ancillary diagnostic technique, immunohistochemistry allows positive identification. Cellular leiomyomas express h-caldesmon and desmin whereas CD10 and inhibin expression is a feature of stromal cells (1, 11). Immunohistochemical alone is not diagnostic and results should always be correlated with the histological appearance and interpreted accordingly (10). In our case, although the clinical findings and preoperative diagnosis were of leiomyoma, typical gross and microscopic findings were of ESN. Extensive tis-

sue sampling was done to establish a confident diagnosis.

Since hysterectomy is the treatment of choice, women of reproductive age who desire to preserve fertility, diagnostic imaging or hysteroscopy may be used to follow up tumor growth. In some cases, hormonal therapy with local excision may be successful. However, since the majority of the women are beyond child bearing age, a hysterectomy is usually required to permit thorough evaluation.

To summarize, ESN is an uncommon benign mesenchymal tumor with no reliable pre-operative diagnostic procedure. Clinical presentation is non-specific and hysterectomy is the treatment of choice. In most instances the diagnosis may be established on morphology alone. The margins of the tumor must be sampled adequately to differentiate it from tumor with similar morphology i.e. invasive stromal tumor and cellular leiomyoma. ESN is considered as a benign tumor with excellent prognosis when diagnosis is definite.

Acknowledgement

The authors declare that there is no conflict of interest.

References

1. Tavassoli FA, Devilee P. Pathology and genetics of the breast and female genital organs. Lyon: IARC Press; 2003.
2. Alaoui Fdili FZ, Chaara H, Bouguern H, Melhouf MA, Fatemi H, Belmlih A, *et al.* Endometrial Stromal Nodule: Report of a case. *Case Report Med* 2011; (2011):260647. doi:10.1155/2011/260647.
3. Elagoz S, Kivanc F, Aker H, Arici S, Ozer H, Guvenal T, *et al.* Endometrial stromal tumors- a report of 5 cases. *Aegean Pathol J* 2005;2:140-5.
4. Ryuko K, Takahashi K, Miyakazi K. A case of endometrial stromal nodule. *Shimane J Med Sci*

1996;14:27-8.

5. Silverberg SG, Kurman RJ. Tumors of the Uterine Corpus and Gestational Trophoblastic Disease. Atlas of Tumor Pathology. 3rd Series. Washington:AFIP;1992.

6. Dionigi A, Oliva E, Clement PB, Young RH. Endometrial stromal nodules and endometrial stromal tumors with limited infiltration: a clinicopathologic study of 50 cases. Am J Pathol 2002;26(5):567-81.

7. Kim KR, Jun SY, Park IA, Ro JY, Nam JH. Endometrial stromal tumor with limited infiltration and probable extrauterine metastasis: report of a case. Ann Diag Pathol 2005;9(1):57-60.

8. Tavassoli FA, Norris HJ. Mesenchymal tumors of the

uterus.VII. A clinicopathological study of 60 endometrial stromal nodules. Histopathology 1981;5(1):1-10.

9. Geetha V, Rupashree S, Bhatt SS. Endometrial stromal nodule with smooth muscle differentiation. Indian J Pathol Microbiol 2008;51:76-7.

10. Baker P, Oliva E. Endometrial stromal tumors of the uterus: a practical approach using conventional morphology and ancillary techniques. J Clin Pathol 2007;60:235-43.

11. Zhu XQ, Shi YF, Chang XD, Zhua CL, Wu YZ. Immunohistochemical markers in differential diagnosis of endometrial stromal sarcoma and cellular leiomyoma. Gynecol Oncol 2004;92(1):71-9.

Archive of SID