

Case Report

Endobronchial Metastasis of Pheochromocytoma 25 Years after Primary Tumor

Maryam Kadivar¹, Pegah Babaheidarian¹, Ali Zare Mirzae¹, Mohammadreza Fakhraie²

1. Dept. of Pathology, Tehran University of Medical Sciences, Tehran, Iran

2. Surgery Ward, Atieh Hospital, Tehran, Iran

ABSTRACT

There are few reported cases of endobronchial metastasis of pheochromocytoma in pathology literature. We present here a 56-year old woman who underwent left lower lobectomy of lung, following pneumonia with unresolved chest radiographs. Computed tomography showed a lobulated soft tissue mass, measuring, 38×27 mm, at the perivascular space of anterior mediastinum. The resected specimen, showed lobulated tumor arranged in nesting pattern within arcuate vascular network. Immunohistochemistry showed intense positive staining of epitheloid cell (chief cells) for chromogranin and synaptophysin which were negative for cytokeratin. Sustentacular cells were strongly positive for S-100. Although very rare, physicians should keep in mind the possibility of endobronchial metastasis in patients with a history of pheochromocytoma.

Keywords: Pheochromocytoma, Lung, Metastasis

Introduction

Pheochromocytoma usually comes from chromaffin cells located in adrenal medulla or sympathetic chain, whereas malignant pheochromocytoma is referred to the presence of chromaffin cells in a place where

they are usually absent (1, 2). On the other hand, extra adrenal paraganglioma occurs more in head and neck and endobronchial involvement by paraganglioma or pheochromocytoma are very rare (3). To our knowledge, there are three cases reported of endobronchial metastasis of pheochromocytoma so far (1).

Received: 17 February 2012

Accepted: 07 July 2012

Address communications to: Dr Maryam Kadivar, Department of Pathology, Tehran University of Medical Sciences, Tehran, Iran

Email: pegah.heidarian@yahoo.com

Case Report

A 56-year old female underwent lobectomy of left lower lobe of lung following two episode of pneumonia over two months with unresolved control computerized tomography changes. She had fever, and dyspnea, but no history of hemoptysis. She had history of pheochromocytoma of right adrenal 25 years ago. Complete blood count was in normal limit. Serum and urine metanephrine and catecholamines were not checked, because she had not any symptoms after then and clinician did not think about pheochromocytoma as a differential diagnosis.

During these past years, she was on medication, included diltiazem, losartan and sustac and her blood pressure was under control until she visited the hospital. A computerized tomography revealed consolidation with air bronchogram in superior and basal segments of left lower lobe, more likely a tumoral mass adjacent to lower lobe bronchus and a lobulated soft tissue mass, measuring, 38×27 mm, at the perivascular space of anterior mediastinum. Bronchoscopy showed total obstruction of left bronchus. Biopsy or cytological washing was not undertaken. The patient underwent left lower lobectomy and resection of bronchial lesion.

The resected samples which included lower lobe of lung and bronchial mass were fixed in 10% formalin, stained with hematoxylin and eosin and examined by light microscopy. Immunohistochemistry was performed on formalin fixed paraffin blocks. The primary antibodies used were thyroid transcription Factor-1(TTF1), anticytokeratin, chromogranin A, Synaptophysin, and S-100.

On gross examination, lower lobe of left lung was gray-brown, spongy, with no tumor involvement. One lymph node, 0.5 cm in diameter was seen near bronchus which was free of tumoral

involvement. Separated bronchial lesion was an ovoid tan to orange soft mass, measuring. 2.5×2×0.5 cm.

Histologically, lung parenchyma showed intraalveolar hemorrhage and mild emphysematous changes. No tumor infiltration was identified.

Bronchial lesion, showed submucosal lobulated tumor surrounded partially by bronchial cartilage with no infiltration. The tumor composed of epithelioid cells arranged in anastomosing trabecular or nesting pattern (zellballen) within arcuate vascular network (Fig. 1). These cells contained round or oval vesicular nuclei with speckled chromatin and variable amount of eosinophilic granular cytoplasm. There was no evidence of necrosis. Rare mitosis was noted. Immunohistochemical stains showed that epithelioid cells (chief cells) stained intensely positive for chromogranin (Fig. 2), synaptophysin (Fig. 3), and faint staining for S-100; they were negative for cytokeratin. Nests of cells were surrounded by stellate spindle sustentacular cells positive for S-100 protein (Fig. 4). These cells did not stain with the other antibodies. Expression of thyroid transcription factor-1 was not observed.

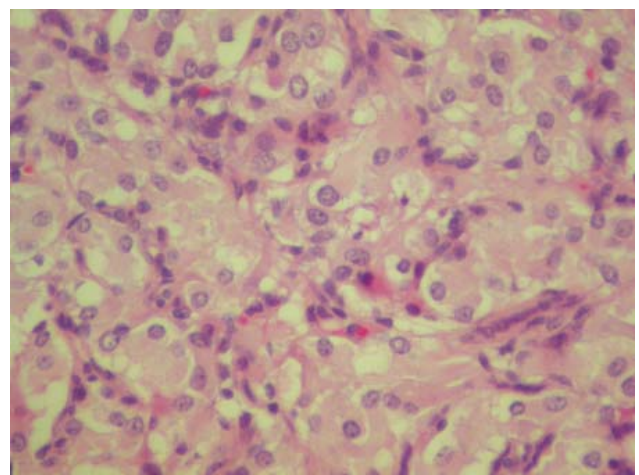


Fig. 1- Well defined nests of cuboidal cells (zellballen) with pink abundant cytoplasm and round nuclei, are separated by highly vascularized fibrous septa (H&E ×400)

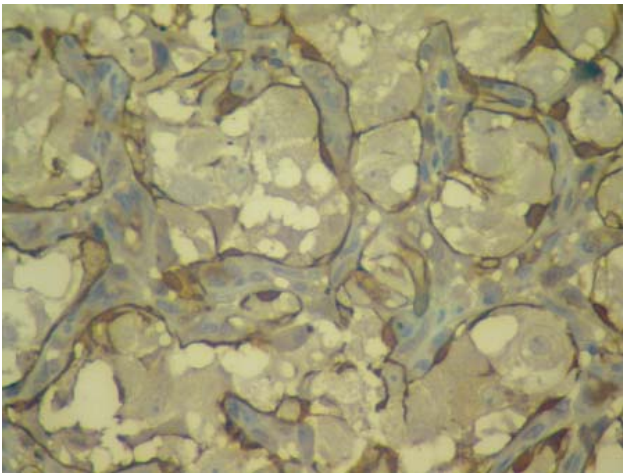


Fig. 2- Immunoreactivity for chromogranin in the tumor epithelial cells (IHC $\times 400$)

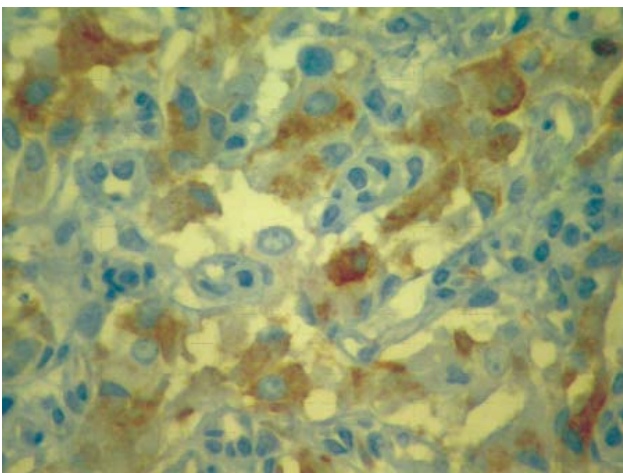


Fig. 3- Intense immunoreactivity for synaptophysin in the tumor epithelial cells (IHC $\times 400$)

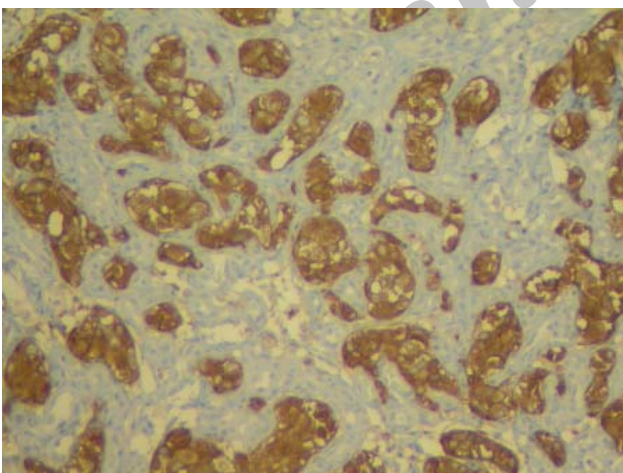


Fig. 4 - Sustentacular cells immunostained for S100 protein at the periphery of the tumor nests (IHC $\times 400$)

Discussion

Although the lung is a favor soil for extra pulmonary metastasis, endobronchial metastasis is occasionally reported. The most common extrathoracic malignancy associated with endobronchial metastasis is breast, renal and colorectal carcinoma (2). Endobronchial metastasis was defined as bronchoscopically visible lesions histopathologically identical to primary lesion in patient with extra pulmonary malignancy. While the most common manifestation of thoracic metastasis of malignant pheochromocytoma is multiple pulmonary nodules, endobronchial involvement from adrenal pheochromocytoma is rare (3). The mean interval from first diagnosis to development of extra adrenal metastasis is 9 years. Apparently, only three cases of pheochromocytoma metastasizing to the bronchus exist in the English language literature. The first case was reported in a 37 year old woman 25 years after initial diagnosis which had history of pheochromocytoma at age 8 (3). Over next 25 years, she experienced multiple local recurrences which required surgical excision and then presented with endobronchial metastasis. The second one was reported 92 months after primary one (4, 5). The third one was reported in a 61 year old man who died because of endobronchial metastasis which proved to be pheochromocytoma on autopsy (1). But our case, had the history of pheochromocytoma 25 years before, during these years, she had not been followed up. She had no symptoms until she experienced dyspnea.

The differential diagnosis of this tumor includes carcinoid tumor, and primary endobronchial paraganglioma. Histological evidence suggests that bronchial carcinoid which derives from kultchitskey cells of bronchial epithelium, can be almost similar to pheochromocytoma and paraganglioma which arises from the chromaffin cells (6). Overlap in the histomorphologic

features of these two tumors warrants the use of immunohistochemistry staining to differentiate these tumors. Up to 80% of carcinoids stain with cytokeratin whereas few exceptional cases of paraganglioma or pheochromocytoma are immunoreactive for it, S-100 protein could be seen in both tumors (6, 7). Recently, thyroid transcription factor-1 has been shown to be expressing in pulmonary carcinoid tumor, but not in paraganglioma. Negative keratin and TTF1 immunoreactivity in association with intense positive staining of epithelial cells with chromogranin and synaptophysin render the diagnosis of paraganglioma/pheochromocytoma more possible rather than carcinoid tumor.

The presented neoplasm with zellballen pattern throughout the tumor within an arcuate vascular channel and typical immunohistochemical profile is similar in both metastatic pheochromocytoma and primary endobronchial paraganglioma. Presence of past history of pheochromocytoma 25 years ago which was morphologically similar to endobronchial metastatic lesion meet the clinical diagnosis of metastasis pheochromocytoma and discriminate this lesion from primary endobronchial paraganglioma which is morphologically similar to it. As a whole, primary paraganglioma of bronchus is rare, and only 2 cases have been reported in English literature (8-10).

Since the interval between pheochromocytoma and its metastasis is long and symptoms plus radiologic findings are similar to primary lung tumor, endobronchial metastasis from pheochromocytoma should be considered in differential diagnosis of any primary lung cancer in the patients with past history of this disease.

Acknowledgements

The authors declare that there is no conflict of interest.

References

1. Ota K, Satoh H, Lin SY, Fujita J, Ohara G, Kurishima K, *et al.* Endobronchial metastasis from adrenocortical carcinoma. *Intern Med* 2009;48(13):1161-4.
2. Akoglu S, Uçan ES, Çelik G, Şener G, Sevinc C, Kılınc O. Endobronchial metastases from extrathoracic malignancies. *Clin and Exp Metastasis* 2005;22(7):587-591.
3. Sandur S, Dasgupta A, Shapiro JL, Arroliga AC, Mehta AC. Thoracic Involvement With Pheochromocytoma: a review. *Chest* 1999;115(2):511.
4. Kwon HJ, Park JH, Jin GY, Chung MJ, Lim ST, Kim MH, *et al.* Posterior mediastinal paraganglioma with bilateral adrenal pheochromocytoma. *Respir Med* 2004;98(6):574-576.
5. Skødt V, Jacobsen GK, Helsted M. Primary paraganglioma of the lung Report of two cases and review of the literature. *APMIS* 1995;103(7-8):597-603.
6. Kee AR, Forrest CH, Brennan BA, Papadimitriou JM, Glancy RJ. Gangliocytic Paraganglioma of the bronchus: a case report with follow-up and ultrastructural assessment. *Am J Surg Pathol* 2003;27(10):1380-5.
7. Shibahara J, Goto A, Niki T, Tanaka M, Nakajima J, Fukayama M. Primary pulmonary paraganglioma: report of a functioning case with immunohistochemical and ultrastructural study. *Am J Surg Pathol* 2004;28(6):825-9.
8. Goodman ML, Laforet EG. Solitary primary chemodectomas of the lung. *Chest* 1972; 61(1):48.
9. Erickson D, Kudva YC, Ebersold MJ, Thompson GB, Grant CS, van Heerden JA, *et al.* Benign paragangliomas: clinical presentation and treatment outcomes in 236 patients. *J Clin Endocrinol Metab* 2001;86(11):5210-6.
10. Aubertine CL, Flieder DB. Primary paraganglioma of the lung. *Ann Diag Pathol* 2004;8(4):237-41.