

Case Report

Ewing's Sarcoma of Hand

S Shamshad Ahmad¹, Sufian Zaheer¹, Khaliqur Rahman¹, Latif Zafar Jilani²,
Amit Kumar¹, Mohd Jaseem Hassan¹, Rana K Sherwani¹

1. Dept. of Pathology, J.N. Medical College, AMU, Aligarh, INDIA

2. Dept. of Orthopedics, J.N. Medical College, AMU, Aligarh, INDIA

ABSTRACT

Ewing's sarcoma (ES) is a highly malignant neoplasm of childhood and adolescence seen commonly in both axial and appendicular skeleton but uncommonly in acral region. Ewing's tumor in the hand is extraordinarily rare. Radiological features are variable and can mimic other common lesions. We present a case of 13 year old female, with complaints of pain and swelling in right hand, which on X-ray showed periosteal reaction, giving a sun burst appearance and provisional diagnosis of osteosarcoma was made. The patient was operated and histopathological diagnosis of ES was confirmed. Histopathological examination remains the mainstay of diagnosis, supported by immunochemistry and cytogenetic studies. Surgical extirpation with chemotherapy is the therapeutic regimen of choice. We intend to report this case, because it is very rare location and the radiological features can mimic other lesions which commonly occur in this location like chronic osteomyelitis so it can be easily missed especially at preliminary evaluations.

Key words: Ewing's Sarcoma, Hand, Neoplasm, India

Introduction

Ewing sarcoma (ES), a highly anaplastic primary bone tumor derived from red bone marrow, was first described by James Ewing in 1921 (1). It commonly occurs in the first two decade of life, involving the diaphysis or metaphyseal-diaphyseal part of long bones, pelvis or rib. Skull, vertebrae, scapula and

short tubular bones of hand and feet are rarely involved (2).

Reported incidences of ES of small bones of hand and foot are about 0.3% (3) so it is very rare. In a report from the Intergroup Ewing Sarcoma Study, which included 377 patients, 10 had a lesion of the foot and there were two with lesion of the hand (4).

Received: 09 March 2012

Accepted: 25 September 2012

Address communications to: Dr Sufian Zaheer, 4/1129, Sir Syed Nagar, Aligarh. 202002. UP, India

Email: sufianzaheer@gmail.com

Pain and swelling are the main presenting features. Radiological features are similar to ES of long bones with some variations like expansion of bone with cystic spaces and absence of periosteal reaction. Pathological findings show small round cells with vacuolation in the cytoplasm, which are evidence of glycogen production. Immunocytochemistry and cytogenetic analysis are important to differentiate it from other small round cell tumors (5). Lesions in the hand are prone to metastasize, but have an excellent prognosis with respect to survival rate and morbidity (6). Surgical extirpation along with chemotherapy is preferable for these distal lesions which avoids the side effects of radiotherapy in young patients (7).

A case report of 13 yr female with Ewing's sarcoma of hand is discussed because it is very rare location for this tumor and the radiological features can mimic other lesions which commonly occur in this location like chronic osteomyelitis so it can be easily missed especially at preliminary evaluations of the patient.

Case report

A 13 year female presented to the orthopedics OPD with complaints of pain and swelling in the right hand for 15 months. Hemogram showed an Hb - 9.2 gm/dl, TLC -6800, DLC - P₆₀, L₃₆ and E₀₄ as well as ESR as 54 mm in first h.

The swelling was small to start with and by the time patient presented to us there was a huge swelling of about 10×11 cm involving the dorsal as well as ventral aspect of right hand present between the thumb and index finger (Fig. 1A). Overlying skin was stretched and shiny. Temperature over the swelling was raised and it was firm and tender. Movements were painful somewhat restricted. Plain radiographs showed destructive lesion of the 2nd metacarpal with marked periosteal reaction, giving a sunray appearance and huge soft tissue component (Fig. 1B). A radiological diagnosis of osteosarcoma was provided. X ray chest and USG abdomen were unremarkable.

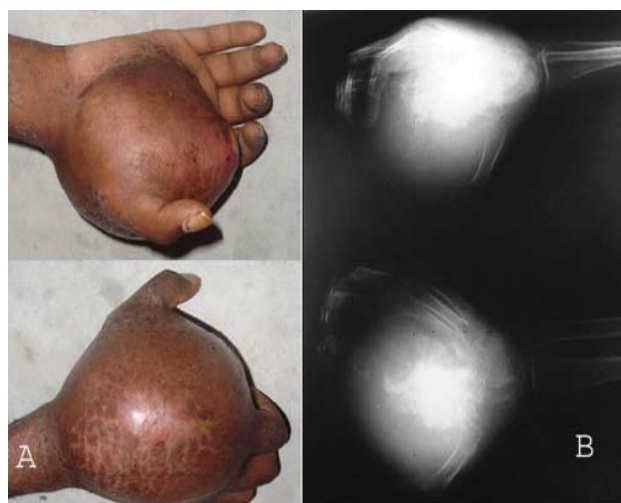


Fig. 1- Photographs shows presence of a huge swelling in the hand involving both the dorsal as well as ventral aspect of hand (A). X- Ray showing destructive lesion of the 2nd metacarpal with marked periosteal reaction, giving a sunray appearance and huge soft tissue component (B).

Fine needle aspiration (FNA) cytology, showed cellular smear with small round cells having scant amount of cytoplasm (Fig. 2A). Some of the cells were showing cytoplasmic vacuolation. A diagnosis of small round cell tumor with Ewing's sarcoma, small cell osteosarcoma and lymphoma as differentials was provided.

Incisional biopsy of the tumor showed small round cells arranged in sheets (Fig. 2B) and small islands, along intermixed second population of cells with comparatively larger nuclei. The tumor cells showed PAS positive reaction (Fig. 2C). There was membranous positivity for CD 99 (Fig. 2D) and was negative for CD45 (LCA), TdT, CD3, and CD20 on Immunohistochemistry. A final diagnosis of Ewing's sarcoma was made. Below elbow amputation was planned. Intraoperatively a grayish white tumor involving the second metacarpal with soft tissue involvement was seen. It was sent to for histopathological evaluation where the diagnosis of Ewing's sarcoma was confirmed.

The patient was sent for chemotherapy where she is undergoing six cycles of chemotherapy and doing fine for last four months.

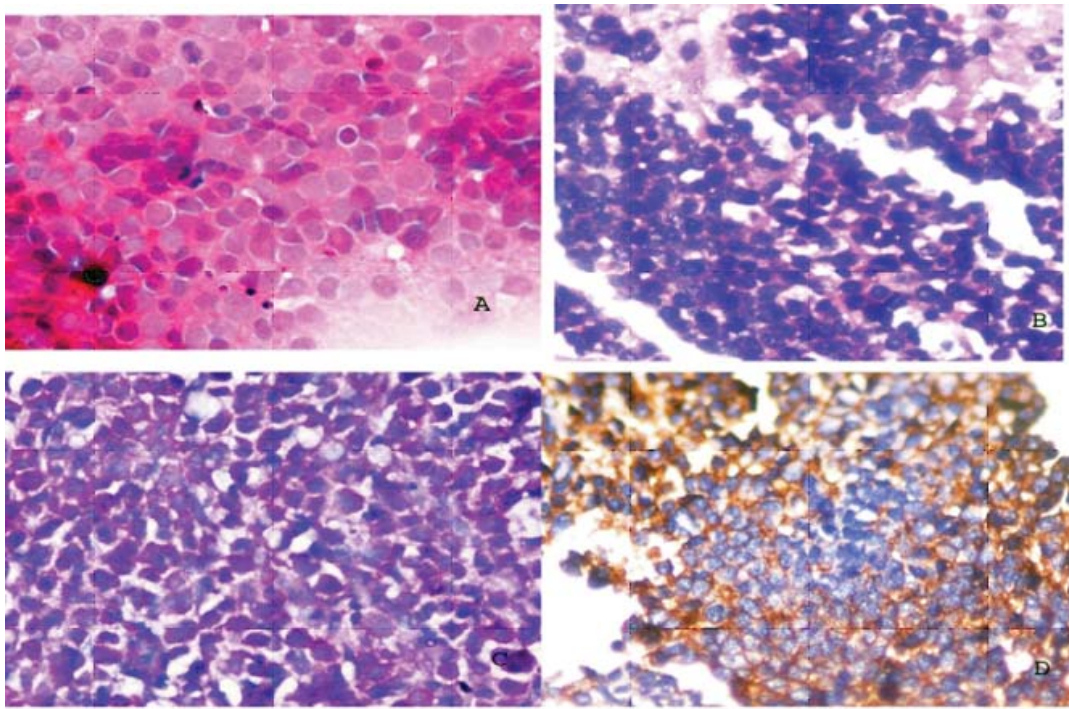


Fig. 2- Aspiration smear from the swelling shows small round cells having very scant amount of cytoplasm. Mitotic figures are appreciated (A; H&E, ×40). Section shows sheets of small round to oval nuclei with very scant cytoplasm (B; H&E, ×40). They are showing presence of PAS positive reaction in their cytoplasm (C; PAS, ×40). Immunostaining showed positivity for CD99 (D; Immunostain, ×40).

Discussion

Ewing's sarcoma is a highly malignant tumor derived from the bone marrow and is frequently diagnosed as a monostotic lesion in the diaphysis of long bones of the extremities. It occurs very rarely in small bones of hand and feet where the reported incidence is not more than 0.3% (3).

When occurring in hand, it is more common in metacarpal than in phalanges. In the present case the tumor arose from the 2nd metacarpal bone of right hand. Patient usually presents with pain and swelling of the extremities. There may be fever, malaise, weight loss or night sweat and raised ESR or elevated LDH levels, and the condition is usually mistaken for a local infection including acute as well as chronic osteomyelitis (4, 8, 9).

Ewing's sarcoma of hand is extremely rare; by the year 1992 only 27 cases had been reported in English language medical literature. Review of data from the Intergroup Ewing's Sarcoma Study

(IESS) shows that ES is rare in bones of the hands and feet. Only 12 of 377 evaluable patients in the first two IESS studies had a primary tumor in these small, distal bones. So ES of hand and foot can be easily missed out especially on clinical examination and radiological findings, and sometimes even on fine needle aspirate or histopathology if the sample material is scant, in which case it can be easily missed, until and unless the surgeon, radiologist and the pathologist keeps in mind this entity while evaluating this entity.

Radiological feature of ES of hand is variable and varies from permeative, mottling, and sclerotic to cystic lesion. The characteristic periosteal reaction is seen as onion skin appearance (5, 8), however sclerosis, soft mass and cystic change are surprisingly common in ES of small bones (8). In the present case, there was spiculated type of periosteal reaction that was perpendicular to the bone surface and masqueraded as sun ray appearance of osteosarcoma making the radiological diagnosis difficult.

FNA is of much help if the characteristic cell population along with glycogen expression is seen. But many a times it is misleading and final diagnosis rests on histopathological finding.

A homogeneous population of small round cells with high nuclear to cytoplasmic ratios, arranged in sheets with scant cytoplasm, and showing PAS positivity for the cytoplasmic glycogen, which is characteristic (2). But in approximately, 30% of the cases PAS is negative so immunohistochemistry should be used to confirm the diagnosis.

Immunohistochemistry showing positivity for CD99 (MIC2), which is a trans-membrane glycoprotein, and is the product of the pseudo autosomal MIC2 gene located on short arms of sex chromosomes. Numerous studies have shown that over 90% of ES/PNETs express MIC2 with a membranous pattern.

t (11; 22)(q24; q12) is seen in almost all the cases and helps on differentiating it from other round cell tumors (4).

Treatment of ES remains controversial (4, 5). In the present case, surgical intervention in the form of below elbow amputation along with chemotherapy was put forth. This was done because a wide surgical excision could be performed easily owing to the acral location of tumor. Apart from it, the side effects of radiation like chances of radiation induced sarcoma, growth plate arrest and joint contractures could also be avoided. Similar strategy was supported by Bacci *et al.* (7).

ES of hand has high chances of metastasis. But fortunately our patient did not have any evidence of metastasis and is also doing fine after 4 months of surgery (7, 8).

This paper emphasized the fact that ES must be kept in mind for acral lesions where radiographs can simulate any other possibility and also when the sample material on FNAC or biopsy is limited in which case the scant amount of small cells may be confused with lymphocytes with disastrous results for the patient, hence a

meticulous pathological examination helps in appropriate and timely surgical intervention in the form of wide surgical excision of these distal lesions.

Acknowledgements

The authors declare that there is no conflict of interest.

References

1. Ewing J. Diffuse endothelioma of bone. Proc NY Pathol Soc 1921; 21: 17–24.
2. Oshigome S, Machinami R, Sorensen PH. Ewing's Sarcoma/ Primitive Neuroectodermal Tumor. In WHO Classification of tumor. Pathology and Genetics of Tumors of Soft Tissue and Bone. Ed by Fletcher CDM, Unni KK and Mertens F. Lyon. IARC Press. 2002.
3. Kissane JM, Askin FS, Foulkes M, Stration LB and Shireley SF. Ewing's Sarcoma of the Bone, Clinico-Pathologic Aspects of 303 Cases for the Intergroup Ewing's Sarcoma Study. Hum Pathol 1983;14(9):773-9.
4. Escobedo EM, Ann G. Bjorkengren AG, Moore SG. Ewing's sarcoma of the hand. AJR Am J Roentgenol 1992(1);159:101-2.
5. Iwamoto Y. Diagnosis and Treatment of Ewing's Sarcoma. Jpn J Clin Oncol 2007; 37(2):79-89.
6. Terrence JJ, Varghese M, Sankaran B, Thirumagal. Ewing's Sarcoma Of The Distal Phalanx Of Little Finger. The Internet Journal of Oncology. 2007;4(1); DOI: 10.5580/2156.
7. Bacci G, Toni A, Avellam M, Manfrini M, Sudanese A, Ciaroni D, *et al.* Long-term results in 144 localized Ewing's sarcoma patients treated with combined therapy. Cancer 1989;63(8):1477–86.
8. Shirley SK, Askin FB, Gilula LA, Vietti TJ, Thomas PR, Siegal GP, *et al.* Ewing's sarcoma in bones of the hands and feet: a clinicopathologic study and review of the literature. J Clin Oncol 1985;3(5):686-97.
9. Mohan V, Gupta RP. Ewing's sarcoma of the small bones of hands and feet. Indian J Radiol Imaging 2002;12(3):403-5.