

Original Article

The Effects of Vitamin E on the Liver Integrity of Mice Fed with Acrylamide Diet

Sedigheh Siahkoohi¹, Morteza Anvari^{1,2}, Mahmood Akhavan Tafti³,
Mohammad Hosseini-sharifabad⁴

1. Dept. of Biology and Anatomical Sciences, Shahid Sadoughi University
of Medical Sciences, Yazd, Iran

2. Research and Clinical Center for Infertility, Shahid Sadoughi University
of Medical Sciences, Yazd, Iran

3. Dept. of Pathology, Shahid Sadoughi University of Medical Sciences, Yazd, Iran

4. Dept. of Anatomy, Shahid Sadoughi University of Medical Sciences, Yazd, Iran

ABSTRACT

Background and Objectives: Acrylamide is a monomer which is formed in foodstuffs containing carbohydrates altered to asparagine during thermal processing. Vitamin E is a component in human diet considered as the most effective lipid-soluble antioxidant found in the biological system. It prevents initiation of oxidative tissue damage. The aim of this study was to investigate the potential role of vitamin E on hepatic biochemical and histological integrity in male mice fed with acrylamide.

Materials and Methods: Twenty-eight adult male mice were randomly divided into four groups comprised of seven mice each. The first group served as control fed on ad-libitum diet; second group received 10 mg/kg/day acrylamide in drinking water; in third group, 100 mg/kg/day vitamin E was injected intraperitoneal, and fourth received a combination of acrylamide/vitamin E for 35 days. After cutting liver, liver injury was assessed by hematoxylin and eosin, and reticulin staining.

Results: Following acrylamide consumption, the serum levels of liver enzymes significantly increased and light microscopy showed lymphocytes infiltration, inflammation of portal space and central vein, apoptosis, chromatolysis and fibrous expansion in some portal areas in acrylamide-treated mice. There was a statistically considerable difference between biochemical parameters, index apoptosis and histological features when the acrylamide plus vitamin E-treated group was compared with acrylamide-treated group.

Conclusion: Acrylamide induced disturbance in hepatocytes activity and increased the serum levels of liver and structural changes in the liver. Administration of vitamin E significantly reduced the increased level of serum aminotransferase and the pathological changes, also effectively suppressed the acrylamide-induced liver injury.

Keyword: Acrylamide, Vitamin E, Liver, Mice

Received: 30 March 2013

Accepted: 18 August 2013

Address Communications to: Dr. Sedigheh Siahkoohi, Department of Biology and Anatomical Sciences, Shahid Sadoughi University of Medical Sciences, Yazd, Iran.

Email: ssiakhkoohi@yahoo.com

Introduction

Acrylamide (AA) is water-soluble used in many industrial and laboratory processes, such as treatment of water, paper making and cosmetics (1). But, it has mutagenic and neurotoxic effects in both animals and humans, and exposure to AA causes tumors of tunica vaginalis of testes and thyroid, mammary fibroadenomas in rats (2). Exposure to AA via the diet has become a worldwide concern, because of its generation in various foods and also can occur in workplaces or in the environment through air, water, land and during its production or use (3, 4). It is formed in foodstuffs contain asparagines (an amino acid) when heated to high temperatures. Moreover, in foods with plant material, the reaction between asparagine and fructose produces the most acrylamide. After consumption, the blood circulation absorbs acrylamide and then distributes to different organs where it can react with hemoglobin, neurons, DNA, and essential enzymes (5, 6). Besides, AA is metabolized to glycidamide (GA) by P450, binds to DNA, this metabolite is more reactive toward DNA and proteins than acrylamide and it can cause genetic damage (7). Besides, formation of glycidamide-DNA adducts may be involved in acrylamide-induced toxicity, mutagenicity, and carcinogenicity (8).

Liver is a vital organ for detoxifying chemicals of body and able to regulate the blood concentration of most metabolites, particularly glucose and amino acids. It has important role in storing, synthesizing, secreting, regulating, transforming, and breaking down of several of material in the body (9). Transforming and clearing are the functions of liver to make it efficient to xenobiotics, drug toxicity and oxidative stress (10). Recently, the formation of oxidants, explained as reactive oxygen species (ROS). It is produced by normal physiological processes and performs vital func-

tions at minimum or moderate concentrations, in the body and essential for the maturation process of cellular structures. Transforming and clearing are the functions of liver to make it efficient to xenobiotics, drug toxicity and oxidative stress. Dysfunction of liver results in destruction of energy metabolism and intracellular oxidant stress with excessive formation of ROS. Oxidative stress causes imbalance between the production of destructive ROS, and cellular natural anti-oxidative defenses. This ROS-mediate damage could produce alterations of cellular macromolecules such as membrane lipids, DNA, and proteins (10, 11).

Antioxidants are the main defense factors against oxidative stress induced by free radicals. Vitamin E is a lipid-soluble antioxidant known in the biological system as scavenges ROS (12). Eight fat-soluble compounds are categorized under the "Vitamin E", such as tocopherols and tocotrienols; α -tocopherol is an important lipid-soluble antioxidant and the most biologically active form of vitamin E. It functions through the glutathione peroxidase pathway protecting cell membranes from oxidation by reacting with lipid radicals produced in lipid peroxidation (LPO) chain reaction, thereby preventing LPO and the initiation of oxidative tissue damage. This protective role emanates from its efficient breaking property for ROS chain reactions by allowing ROS to abstract a hydrogen atom from the antioxidant molecule rather than from polyunsaturated fatty acids, resulting in the information of an unreactive α -tocopheroxyl radical (13,14). Vitamin E is an integral component of plasma lipoproteins, scavenges of lipid peroxy radicals in biological membranes thus prevents formation of reactive lipid peroxidation products, which has both mutagenic and carcinogenic properties. Oxidative stress is a characteristic of many chronic human liver diseases associated with a significant dimi-

nution in hepatic levels of vitamin E, including chronic hepatitis virus infections, cirrhosis and cancer and might represent a common mechanism for liver injury by diverse etiology (15).

The aim of this study was to investigate the potential role of vitamin E on hepatic biochemical and histological integrity in male mice fed with acrylamide diet.

Material and Methods

Chemical

Acrylamide monomer ($\text{CH}_2=\text{CHCONH}_2$) is solid, dry, odorless and white crystals with chemical purity (Merk chemical CO, Germany).

Animals and treatment

Twenty-eight NMRI male mice (Pasteur Institute, Tehran, Iran) were preserved in the animal house of the medical university of Shahid Sadooghi (Yazd, Iran) with controlled temperature ($22\text{-}24^\circ\text{C}$) and a cycle of 12h-12h light/dark. They were randomly divided into four groups with 7 animals each, including three experimental groups and one control group. Group I (control) got usual mouse food and water ad-libitum, But group II were fed on water solutions containing acrylamide 10 mg/kg/day, group III 100 mg/kg/day vitamin E were injected intraperitoneal (IP), group IV with combination of acrylamide/vitamin E for 35 days. This study was approved by ethics committee of our institution.

Assessment of biochemical markers

At the end of experiment, in order to measure the plasma levels of liver enzymes, animals were anaesthetized and blood samples collected from atrium of mice for serum separation and allowed to coagulate at room temperature then centrifuged at 2800 rpm for 20 min to get the serum. The clear non-hemolyzed sera were quickly removed and stored at -20°C for subsequent biochemical analysis. Analysis of some liver enzymes such as alanine transaminase (ALT), and aspartate trans-

aminase (AST) were determined by monitoring the concentrations of pyruvate and oxaloacetate, respectively, according to Reitman & Frankel method. Alkaline phosphatase (ALP) activities were estimated by using Bessey method (16).

Histopathological determination

For histopathological studies after Liver resection, anterior lobe was immediately separated and fixed in 10% neutral buffered formalin for 24 h. The tissue was washed to remove the excess of fixative and then dehydrated in ascending grades of ethyl alcohol 50,70,95% for 2 min each, then this was followed by clearing in two changes of xylene for 10 min each. Next was embedded in paraffin, sectioned with a microtome at 4 to $5\mu\text{m}$, dewaxed, hydrated and subsequently stained with Hematoxylin & Eosin (H&E), reticulin. The histological sections were studied under light microscope at 400 magnifications and photographed and graded and staged semiquantitatively by an experienced pathologist based on a modified scoring system and is very close to the recent modification of Knodell.

The scoring system takes into account three of the most common features seen in acrylamide treatment, namely piecemeal necrosis, lobular inflammation, and portal inflammation (17,18).

Graded Features

Periportal or periceptal interface hepatitis (piecemeal necrosis): 0=none; 1=mild (focal few portal areas); 2=mild/moderate (focal, most portal areas); 3=moderate; 4=severe. Lobular activity (spotty necrosis, apoptosis and focal inflammation): 0= none; 1= one focus or less per $10\times$ objective; 2=two or four foci per $10\times$ objective; 3= five or ten foci per $10\times$ objective. Portal inflammation : 0=none; 1=mild ; 2= moderate ; 3=moderate/marked ; 4=marked, all portal areas(18, 19).

Staging Features

The fibrosis score was extended to take account of the intermediate degree of fibrosis seen so

frequently in these slides. Fibrosis: 0=none; 1= fibrosis expansion of some portal areas ,with or without short fibrous septa; 2= fibrosis expansion of most portal areas ,with or without short fibrous septa; 3= fibrosis expansion of most portal areas, with occasional portal to portal (P-P) bridging; 4= fibrosis expansion of most portal areas with marked bridging portal to portal(P-P) as well as portal to central (P-C) ; 5=marked bridging (P-P and/or P-C) with occasional nodules (incomplete cirrhosis); 6=cirrhosis, probable or definite (18,19).

Apoptosis by TUNEL assay

After deparaffinized sections in xylene and ethanol, in order to inhibition of androgen peroxidase enzyme used 3% H₂O₂ in methanol for 15 min. For increase membrane permability used proteinase K 20 µg/ml of PBS and histological sections incubated for 1 h at 37 °C. Sections covered with TUNEL labeling solution, and incubated for 1 h at 37 °C. Then convertor POD for 40 min at 37 °C and DAB substrate for 10-15 min used respectively .After each stage performed washing with PBS. Finally, dehydration of sections was performed by ascendant ethanol and xylene. Apoptotic cells were identified by a brown stain over the nuclei. Apoptotic index (AI) was determined the percentage of labeled cells (TUNEL positive) with respect to the total number of cells counted using. Positive labeling results were obtained with tissue pretreated with DNAase (R&D System, Minneapolis, MN), and negative (not detectable) labeling results were obtained when

the terminal deoxynucleotidyl transferase was omitted from the TUNEL enzymatic reaction. TUNEL assay kit was purchased from Roche (Basel, Switzerland).

Statistical analysis

The results were expressed as mean ±SD. Post hoc testing was performed for intergroup comparisons using the least significant difference (LSD) test. A value corresponding to *P*<0.05 was considered statistically significant. Data were subjected to one way analysis of variance (ANOVA) followed by Bonferroni’s post-hoc test for multiple comparisons of the means between treatments and the negative control. The correction method was applied and statistical probabilities *P*<0.05 were considered significant. Changes in hepatic lesions analyzed by the Kruskal-Wallis *H* test was used to evaluate mean differences between groups.

Results

Effects of acrylamide and Vitamin E on liver marker enzymes

Administration of acrylamide alone in drinking water caused increase (*P*<0.001) in the serum level of AST, ALT, ALP to that of the control group (Table 1). Vitamin E supplemented in combination with acrylamide revealed a significant decrease (*P*<0.05) in the level of ALT, AST, ALP as compared to acrylamide group, while mean values of the enzymes did not change (*P*<0.05) in the vitamin E treatment alone compared with the control group.

Table 1- Effect of Acrylamide on liver marker enzymes and apoptosis index in mice

Variable	Control	Vitamin	Acrylamide	Vitamin + Acrylamide
ALT****	76.14±20.17	44.85±6.46***	148.14±15.78*	88.14±16.32
AST*****	106.57±39.92	69.57±7.56***	216.28±19.26*	173.0±22.97**
ALP*****	86.85±14.06	50.28±7.15***	135.42±46.71*	84.00±10.87
Apoptosis Index	11.0±2.1	6.00±1.52***	36.1057±8.52*	13.00±6.11

*Mean ±SD (n=7).0.05, ***P*<0.05 vs. the control group< *P* ****P*<0.05 vs. the acrylamide group
 ****Alanine aminotransferase; *****Aspartate aminotransferase; *****Alkaline phosphatase

Assessment of apoptotic cell death

Histological sections of these livers were evaluated for apoptotic cells together with TUNEL assay to support morphologic finding. A cell apoptosis detection kit was used to assess apoptosis in liver tissues. The number of apoptotic hepatocytes was counted in 6 random high power fields ($\times 40$ objective).the degree of apoptosis was accessed using apoptosis index. Apoptosis index= (the number of apoptotic hepatocytes/total number of hepatocytes) $\times 100\%$.

As shown in Fig.1, the number of TUNEL-positive cells was observed in the livers obtained from mice pretreated with acrylamide as compared to control group. In addition, the effect of vitamin E on DNA fragmentation was also (figure1) which indicated that vitamin E could inhibit ($P < 0.05$) hepatocyte apoptosis induced by acrylamide in mice. In addition, mean values of apoptosis index did not change ($P < 0.05$) in vitamin E treatment alone compared with the control group (Table 1).

Histopathological finding

The liver sections of mice treated with vehicle showed normal hepatic architecture and normal hepatocytes with well cytoplasm, prominent nucleus, central and portal vein with no sign of inflammation or necrosis. However, the livers exposed to acrylamide, lesions involved the areas of

portal inflammation, central vein and hepatocellular necrosis which were randomly distributed throughout the parenchyma and increase infiltration of inflammatory cells, fibrosis and collapse in some portal areas. Formation of apoptotic cells such as cellular shrinking with cytoplasm acidophilia, condensation, and margination of the chromatin, chromatolysis and pyknosis were noticed ($P < 0.05$). These alterations were ameliorated the acrylamide+ vitamin E group. Moreover, these changes were hardly observed in vitamin E group and these results indicated that vitamin E could ameliorate the severity of liver damage and protect liver from acrylamide- induced injury effectively (Fig. 2, 3). Also, mean values of pathological changes did not differ ($P < 0.01$) in vitamin E treatment alone compared with control group. The frequency of individually assessed histological features (Periportal, portal and lobular inflammatory changes and fibrosis) is shown in Table 2. Histopathological studies demonstrated that acrylamide (compared to normal) induced apoptic bodies in hepatocytes and lymphocytic infiltration in portal areas. Also, fibrosis and collapse in some portal areas were frequently presented (Fig. 2,3). Vitamin E+AA treated livers showed significant recovery. In histopathological examination, apoptotic bodies in hepatocytes and lymphocytic infiltration in portal areas were scarce.

Table 2- Effect of Acrylamide on histological features in mice

Variables	Control	Vitamin	Acrylamide	Vitamin + Acrylamide
Piecemeal necrosis	0.57 \pm 0.53	0.15 \pm 0.17**	1.57 \pm 0.53*	0.64 \pm 0.73****
Lobular inflammation	0.42 \pm 0.53	0.142 \pm 0.37***	1.5 \pm 0.01*	0.53 \pm 0.57
Portal inflammation	0.42 \pm 0.53	0.142 \pm 0.37***	2.28 \pm 0.48*	0.78 \pm 0.99****
Fibrosis	0.42 \pm 0.53	0.142 \pm 0.37***	0.71 \pm 0.48	0.35 \pm 0.48

Mean \pm SD (n=7).

* $P < 0.05$, ** $P < 0.01$ vs. the control group

*** $P < 0.01$ vs. acrylamide group

**** $P < 0.05$ vs. acrylamide group

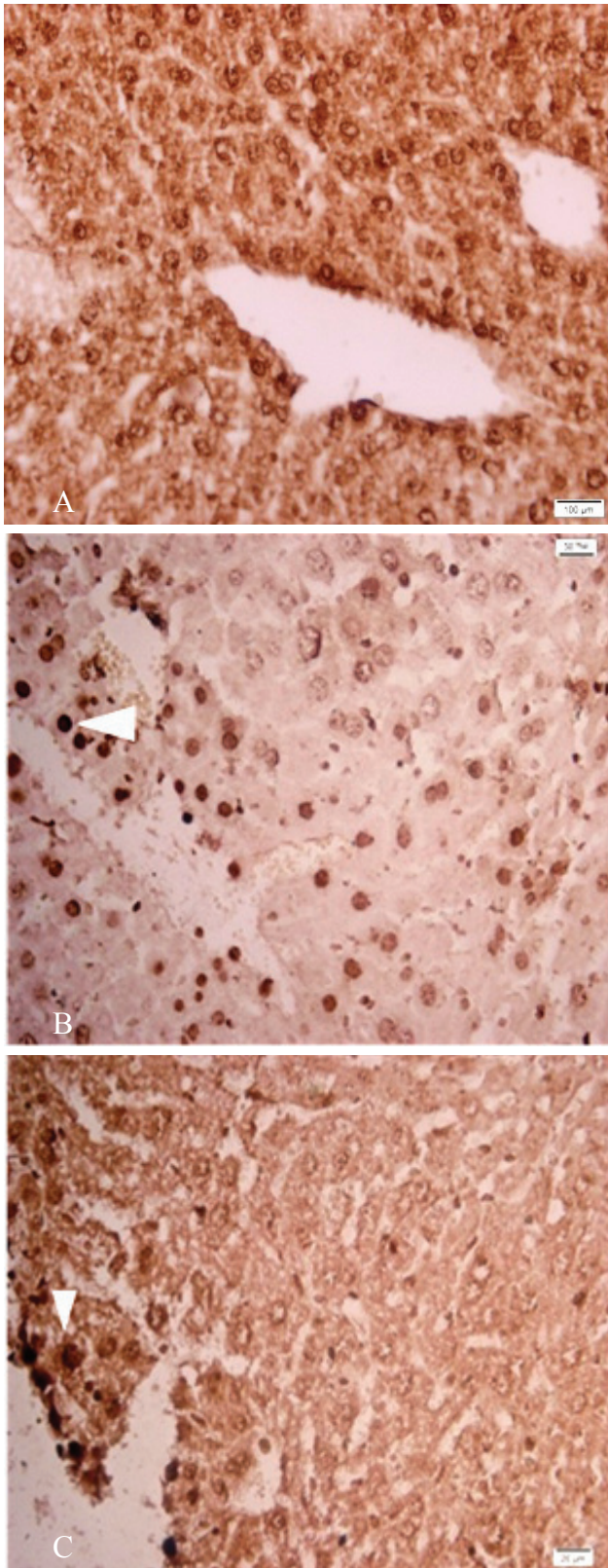


Fig.1: TUNEL staining of livers. (Hepatocellular apoptosis significantly decreased within vitamin E therapy (original magnification $\times 400$)
 A: Control group B: Apoptotic cells were formed in group Acrylamide (Head of arrow) C: Acrylamide + vitamin E group.

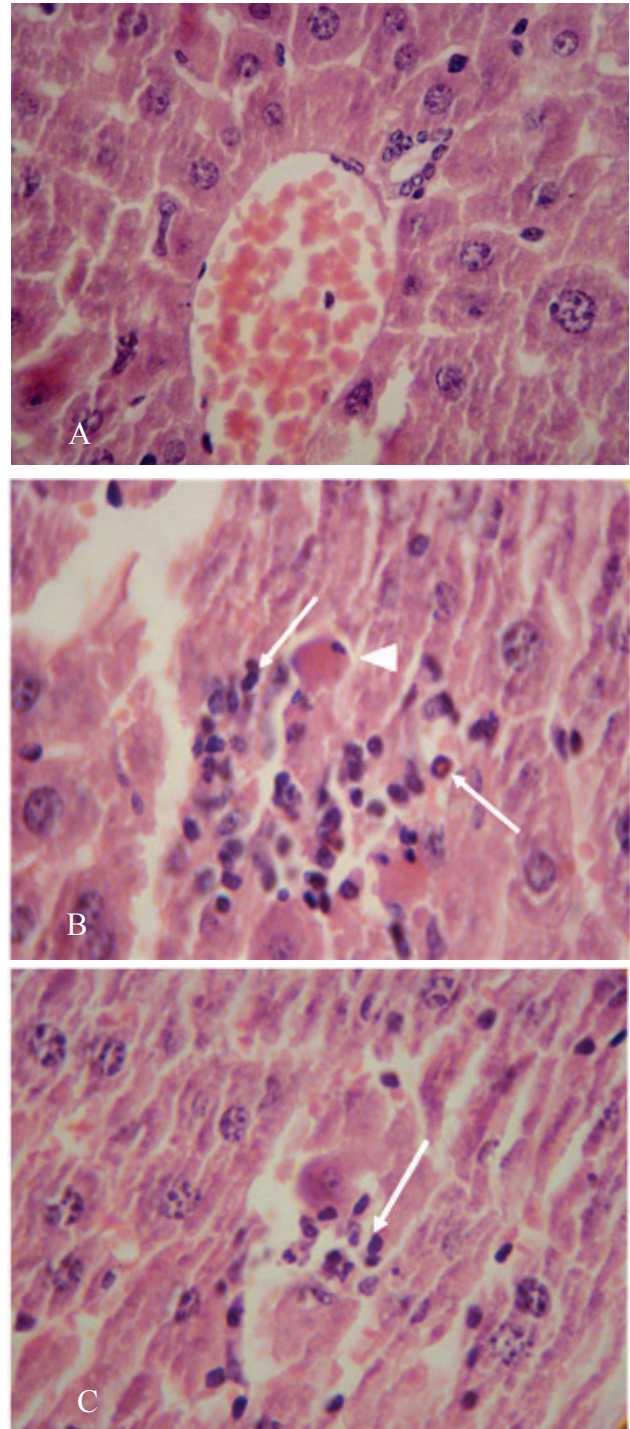


Fig.2: Typical images were chosen from the different experimental groups (H&E, original magnification $\times 400$) A: Control group: The structures of lobules of liver and hepatocyte are normal and clear. B: Acrylamide group: There are areas of portal inflammation (arrow) and hepatocellular necrosis and apoptotic cells (Head arrow) were formed in group Acrylamide. C: The injury of Acrylamide + Vitamin E group reduced compared with group acrylamide.

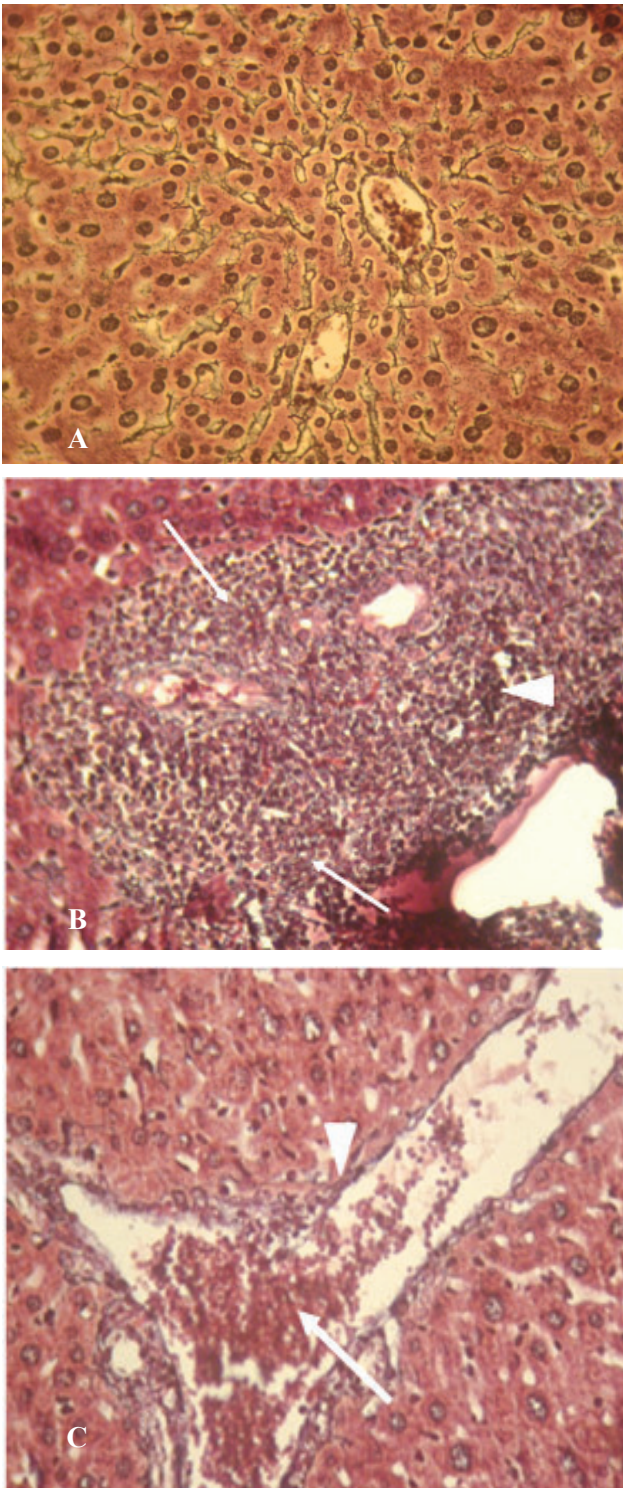


Fig.3: Reticulin staining. A: control group; B: There is collapse in portal space (arrow), fibrosis (Head arrow) in Acrylamide group; C: Acrylamide + Vitamin E group (original magnification $\times 400$).

Discussion

This study revealed that acrylamide to mice at concentration of 10 mg/kg for 35 days induced

elevation of activities compared to the control group. Estimating the activities of serum marker enzymes, like AST, ALT, and ALP can make assessment of liver function. When liver cell membrane integrity is damaged as a result of toxemia, a variety of enzymes normally are released into the blood stream. Their estimation in the serum is a useful quantitative marker of the extent and type of hepatocellular damage. Transaminase and Phosphates are critical enzymes in biological processes; they perform detoxification, metabolism and biosynthesis of energetic molecules for different essential functions. Dysfunction of these enzymes causes biochemical impairment and lesions of the tissue and cellular function. The increased enzymes observed in acrylamide-treated mice in our study generally reflect cellular damage induced by toxin (20, 21). Yousef and EI-Demerdash reported significant elevation of these enzymes in plasma post acrylamide intoxication. They believe that biochemical parameters are sensitive index to changes due to xenobiotics and can constitute important diagnostic tool in toxicological studies (21).

The increased serum levels of aminotransferase in our study have been resulted to damaged structural integrity of the liver, because they are located in cytoplasm and released into blood stream after acrylamide induced cellular damage which manifested histological by our histopathological findings which revealed necrotic changes such as granular eosinophilic cytoplasm and karyolysis of some nuclei, round cell infiltration, apoptotic bodies in portal and interstitial tissue and fibrosis and collapse in some portal areas. These changes were significantly attenuated by vitamin E. This vitamin might have a potential protective effect against acrylamide-induced liver injury. Also, Khlood *et al.* evaluated the effect of different doses of acrylamide on histopathological changes and showed necrotic changes represented by granular eosinophilic cytoplasm and karyolysis of some nuclei, round cell infiltration in portal

and cloudy swelling. Activity of AST and ALT increased in the serum of acrylamide- treated rats (6).

In addition, disruption of pattern of hepatic cords and central canal wall, lymphocytes infiltration, inflammation, vacuolization of hepatocytes and necrosis was reported in rats exposed to acrylamide (22). The result of oxygen radical formation is damage to an array of biomolecules found in tissue, including nucleic acids, membrane lipids, enzymes, and receptors. Membrane-associated polyunsaturated fatty acids are rapidly attacked by OH in a process that leads to peroxidation of lipids, which can disrupt membrane fluidity and cell compartmentation, resulting in cell lysis. Moreover acrylamide toxicity in rats showed that hepatic tissue produce large amounts of free radical such as ROS which exerts the peroxidation of polyunsaturated fatty acid in the membrane of cell of liver. ROS directly attacks lipids, proteins in the biological membranes and cause their function (23). Peroxidation of lipid membranes, disintegration of cytoskeleton and cellular compartments by ROS might lead to the disturbances of digestive and lysosomal enzymes transport within the cell leading to the cell damage. It may cause significant increases in the hepatic malondialdehyde levels, end products of lipid peroxidation, where function of these organ were also impaired as demonstrated by increase ALT, AST (18, 24, 25). Apoptosis has been regarded as a central mechanism responsible for the injury induced by AA.

Jason *et al.* evaluated of subcutaneous vitamin E administration markedly enhanced hepatic and mitochondrial α -tocopherol concentration and reduced both chemical and histological liver injury from AA. The potential therapeutic benefits of oral vitamin E supplementation have been evaluated in several chronic liver diseases, including viral and autoimmune hepatitis, alcoholic liver disease, nonalcoholic steatohepatitis, and cholestatic liver diseases (26, 27). Pretreatment with IP vitamin E successfully reduced oxidative liver injury in

rodent models of ischemia/ reperfusion injury and N-nitrosodiethylamine toxicity (28). Both high dose of vitamin E supplementation (high dose, 450mg/ kg diet) and deficiency (0 mg/ kg diet) cause to enhance the growth of hepatic focal lesions (29). This vitamin plays a vital protective role for preventing the production of lipid peroxides by scavenging free radicals which are toxic for biological membranes (30). Also, vitamin E could improve the degree of oxidative stress, necrosis and vacuolization of hepatocytes (28). Acrylamide is metabolized by hepatic P450 CYP2E1 to glycidamide: approximately 50% of orally administered acrylamide is metabolized via this pathway and glycidamide binds to DNA and induces DNA adducts and mutations (31, 32). Assays of mutagenicity in vivo have demonstrated that administration of acrylamide or glycidamide in the drinking water increases mutant frequencies in lymphocyte Hprt and liver and lung CII genes of adult Big Blue mice by inducing primarily G: C to T: A transversion (33).

Conclusion

Vitamin E protects against acrylamide- induced liver injury, which prevents oxidative stress, apoptosis. This study provides evidence that vitamin E may be useful as a potential pharmacological alternation to manage these liver pathologies, but further investigation is needed in human.

The protective potential of vitamin E that consequently ameliorated these changes induced with AA. It is suggested that mechanism of vitamin E action is probably through scavenging of free radicals. The administration of vitamin E alone or in combination with acrylamide significantly lowered serum activity and liver injury. So, we recommend restriction of acrylamide exposure either occupationally or in food containing product.

Acknowledgments

This study was supported by the Vice-chancellor for Research of Shahid Sadoughi University of

Medical Sciences. The authors would like to express their gratitude to the biological lab staffs in research and clinical center for infertility and Shahid Sadoughi University of medical science, Iran. Yazd. The work is part of the thesis by S. Siahkhoohi. The authors declare that there is no conflict of interest.

References

1. Friedman M. Chemistry, biochemistry, and safety of acrylamide. A review. *J Agric Food Chem* 2003;51(16):4504-26.
2. Friedman MA, Dulak LH, Stedham MA. A lifetime oncogenicity study in rats with acrylamide. *Fundam Appl Toxicol* 1995;27(1):95-105.
3. Dearfield KL, Douglas GR, Ehling UH, Moore MM, Sega GA, Brusick DJ. Acrylamide: a review of its genotoxicity and an assessment of heritable genetic risk. *Mutat Res* 1995;330(1):71-99.
4. Yang H-J, Lee S-H, Jin Y, Choi J-H, Han D-U, Chae C, et al. Toxicological effects of acrylamide on rat testicular gene expression profile. *Reprod Toxicol* 2005;19(4):527-34.
5. Lignert H, Grivas S, Jägerstad M, Skog K, Törnqvist M, Åman P. Acrylamide in food: mechanisms of formation and influencing factors during heating of foods. *Nutr Res*. 2002;46(4):159-72.
6. Sabik LM. Acrylamide-induced genotoxic, biochemical and pathological perturbations in male rats liver. *J Am Sci* 2011;7(1):1092-1096.
7. Besaratinia A, Pfeifer GP. A review of mechanisms of acrylamide carcinogenicity. *Carcinogenesis* 2007;28(3):519-28.
8. Ghanayem BI, McDaniel LP, Churchwell MI, Twaddle NC, Snyder R, Fennell TR, et al. Role of CYP2E1 in the epoxidation of acrylamide to glycidamide and formation of DNA and hemoglobin adducts. *Toxicol Sci* 2005;88(2):311-8.
9. Akharaiyi F, Boboye B, Adetuyi F. Hepatoprotective Effect of Ethanol Leaf Extract of *Cnestis ferruginea* on Swiss Albino Mice Induced with Paracetamol. *Int Res J Pharmaceuticals* 2012;2(04), pp.120-126
10. Islam M, Parvin M, Islam M. Antioxidant and hepatoprotective activity of an ethanol extract of *Syzygium jambos* (L.) leaves. *Drug Discov Ther* 2012;6(4):205.
11. Kehrer JP, Jones DP, Lemasters JJ, Farber JL, Jaeschke H. Mechanisms of hypoxic cell injury: Summary of the Symposium Presented at the 1990 Annual Meeting of the Society of Toxicology. *Toxicol Appl Pharmacol* 1990;106(2):165-78.
12. Agarwal A, Prabakaran SA, Said TM. Prevention of oxidative stress injury to sperm. *J Androl* 2005;26(6):654-60.
13. Wefers H, Sies H. The protection by ascorbate and glutathione against microsomal lipid peroxidation is dependent on vitamin E. *Eur J Biochem* 1988;174(2):353-7.
14. Evstigneeva R, Volkov I, Chudinova V. Vitamin E as a universal antioxidant and stabilizer of biological membranes. *Membr Cell Biol* 1998;12(2):151.
15. Factor VM, Laskowska D, Jensen MR, Weitach JT, Popescu NC, Thorgeirsson SS. Vitamin E reduces chromosomal damage and inhibits hepatic tumor formation in a transgenic mouse model. *Proc Natl Acad Sci USA* 2000;97(5):2196-201.
16. Venukumar M, Latha M. Hepatoprotective effect of the methanolic extract of *curculigo*. *Indian J Pharmacol* 2002;34:269-75.
17. Nema AK, Agarwal A, Kashaw V. Hepatoprotective activity of *Leptadenia reticulata* stems against carbon tetrachloride-induced hepatotoxicity in rats. *Indian J Pharmacol* 2011;43(3):254.
18. Soden JS, Devereaux MW, Haas JE, Gumprich E, Dahl R, Gralla J, et al. Subcutaneous vitamin E ameliorates liver injury in an in vivo model of steatocholestasis. *Hepatology* 2007;46(2):485-95.
19. Brunt EM. Grading and staging the histopathological lesions of chronic hepatitis: the Knodell histology activity index and beyond. *Hepatology* 2000;31(1):241-6.
20. Rawi S. Studies on the activities of sulphur-containing compounds to block diabetogenic effect of alloxan in albino rats. *Proc Zool Soc (Egypt)* 1995;26:244-59.
21. Yousef M, El-Demerdash F. Acrylamide-induced oxidative stress and biochemical perturbations in rats.

Toxicology 2006;219(1):133-41.

22. Khan MR, Afzaal M, Saeed N, Shabbir M. Protective potential of methanol extract of *Digera muricata* on acrylamide induced hepatotoxicity in rats. *Afr J Biotechnol* 2011;10:8456-64.

23. Yamamoto Y, Niki E, Eguchi J, Kamiya Y, Shimasaki H. Oxidation of biological membranes and its inhibition. Free radical chain oxidation of erythrocyte ghost membranes by oxygen. *Biochim Biophys Acta* 1985;819(1):29-36.

24. Jaworek J, Leja-Szpak A, Nawrot-Porabka K, Bonior J, Szklarczyk J, Kot M, *et al.* Effect of neonatal endotoxemia on the pancreas of adult rats. *J Physiol Pharmacol* 2008;59(4):87-102.

25. Tozan-Beceran A, Şehirli AÖ, Eksioğlu-Demiralp E, Şener G, Omurtag GZ. Melatonin protects against acrylamide-induced oxidative tissue damage in rats. *Marmara Pharma J* 2012.

26. Medina J, Moreno-Otero R. Pathophysiological basis for antioxidant therapy in chronic liver disease. *Drugs* 2005;65(17):2445-61.

27. Giakoustidis D, Papageorgiou G, Iliadis S, Giakoustidis A, Kostopoulou E, Kontos N, *et al.* The protective effect of α -tocopherol and GdCl₃ against hepatic ischemia/reperfusion injury. *Surg Today* 2006;36(5):450-6.

28. Bansal AK, Bansal M, Soni G, Bhatnagar D. Protective role of Vitamin E pre-treatment on N-nitrosodiethylamine induced oxidative stress in rat liver. *Chem Biol Interact* 2005;156(2):101-11.

29. Kolaja KL, Klaunig JE. Vitamin E Modulation of Hepatic Focal Lesion Growth in Mice. *Toxicol Appl Pharmacol* 1997;143(2):380-7.

30. Yue D, Yan L, Luo H, Xu X, Jin X. Effect of Vitamin E supplementation on semen quality and the testicular cell membranal and mitochondrial antioxidant abilities in Aohan fine-wool sheep. *Anim Reprod Sci* 2010;118(2):217-22.

31. Sumner SC, MacNeela JP, Fennell TR. Characterization and quantitation of urinary metabolites of [1, 2, 3-¹³C] acrylamide in rats and mice using carbon-13 nuclear magnetic resonance spectroscopy. *Chem Res Toxicol* 1992;5(1):81-9.

32. Calleman CJ. The metabolism and pharmacokinetics of acrylamide: implications for mechanisms of toxicity and human risk estimation. *Drug Metab Rev* 1996;28(4):527-90.

33. Manjanatha MG, Aidoo A, Shelton SD, Bishop ME, McDaniel LP, Lyn-Cook LE, *et al.* Genotoxicity of acrylamide and its metabolite glycidamide administered in drinking water to male and female Big Blue mice. *Environ Mol Mutagen* 2006;47(1):6-17.