

Case Report

Primary Lymphoma of Appendix: Report of Three Cases and Review of Literature

Katayoun Ziari, Kamyab Alizadeh,
Omid Rahmani, Mohammad-Reza Kazemi

Dept. of Pathology, Be'sat Hospital, AJA University of Medical Sciences, Tehran, Iran

ABSTRACT

Lymphomatous involvement of the appendix is rare and most of them are found accidentally from appendectomies to treat appendicitis. Here we report three cases of primary lymphoma of appendix of 10 year-old boy, 23-year-old man and 24-year-old woman that presented with abdominal pain to our hospital and the tumors were discovered during routine appendectomy for suspected "appendicitis". Our cases underwent chemotherapy regimen and they were asymptomatic respectively at 14, 17, and 18 months following-up. In the literature review of the tumors of the appendix, most of the begin tumors of appendix are treated with surgery alone. Lymphoma requires CHOP-like chemotherapy and carcinoid tumor treated according to the size of the tumor <2 with appendectomy alone and >2 with right hemicolectomy. The preferred treatment for adenocarcinoma of appendix is right hemicolectomy and the role of chemotherapy is unclear but when lymph node involvement is present, chemotherapy seems to be accepted.

Keywords: Appendix, Lymphoma, Case Report

Introduction

An appendiceal neoplasm can be presented unexpectedly at any elective or emergency abdominal operation. Although most of them presented as acute appendicitis (about 50%), variable presentation have been reported (1). The pathological types and

behavior of appendiceal neoplasm are diverse and both the classification and terminology have been confusing (2). In many cases, an appendiceal neoplasm is identified only after histopathological analysis of appendectomy specimen (3). The majority of appendiceal neoplasms are carcinoid, while the remaining 10-20% is mucinous

Received: 02 February 2013

Accepted: 15 July 2013

Address communications to : Dr. Kamyab Alizadeh, Department of pathology, Be'sat Hospital, Basij highway, Tehran, Iran.

Email: Kamyab_alizadeh@yahoo.com

cystadenocarcinoma, adenocarcinoma, lymphoma, paragangelioma, and granular cell tumor. In most of cases, appendectomy alone is sufficient treatment (4). Malignant lymphoma comprises approximately 4% of all the gastrointestinal malignant neoplasms. Primary appendicular lymphomas are even more uncommon with an incidence of 0.015% reported in a large series of 710,000 appendicular specimen (5).

The aim of this review is to summarize the incidence, classification, presentation, and management of the appendiceal neoplasm and to report three cases of appendiceal Burkitt's lymphoma.

Case report

Case 1

A 10- year- old boy had 3- month history of fatigue and vague abdominal pain localized to the right lower quadrant for two weeks. The lab

data showed leukocytosis ($12.8 \times 10^3/\text{mL}$) and ultrasound imaging of the abdomen showed slight effusion in the pelvic fossa. The patient with suspected appendicitis underwent laparotomy appendectomy. The appendix appeared moderately hyperemic with slight enlargement of the two thirds of the distal portion. The morphological and immunohistochemical examination showed lymphoma cells with numerous mitotic figures, apoptotic bodies and unclear molding (Fig. 1) and immunohistochemistry were positive for CD20, CD79a, CD10, and ki 67 and the final diagnosis was Burkitt's lymphoma.

Further examination including colonoscopy, gastroscopy and abdominal MRI revealed that the lymphoma was limited to the distal two- third of the appendix (stage Ia). The patient was put on CHOP-like chemotherapy regime. At a recent follow-up, 14 months after surgery the patient had no evidence of recurrence (Fig. 1).

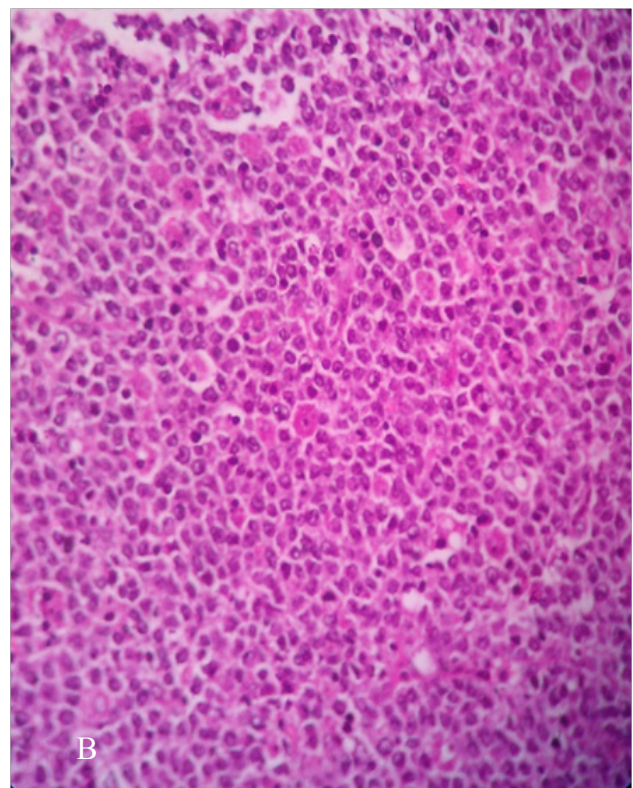
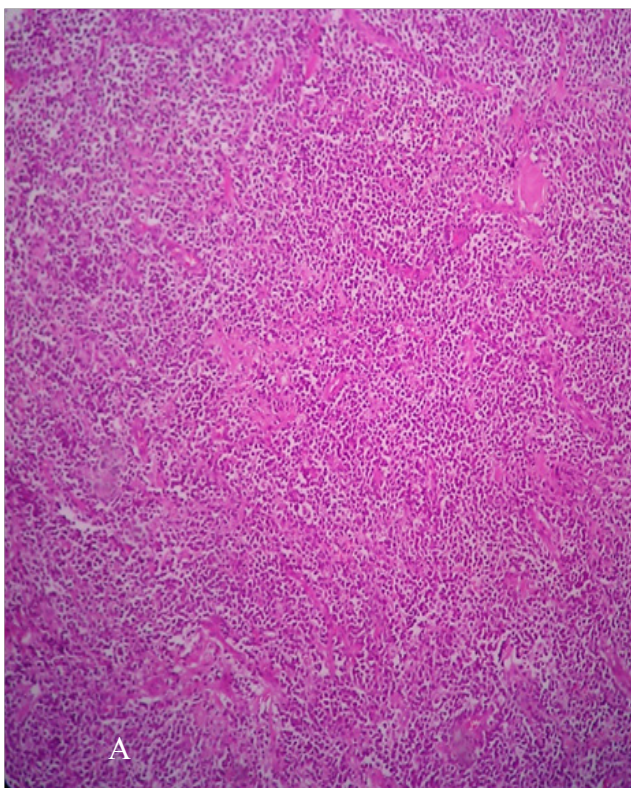


Fig. 1: **A)** low power; **B)** High power view showing lymphoma cells with numerous mitotic figures and apoptotic bodies (Hematoxylin & Eosin $\times 400$). Sheets and cords of highly neoplastic lymphoblasts with high N/C ratio, hyperchromasia, apoptotic bodies.

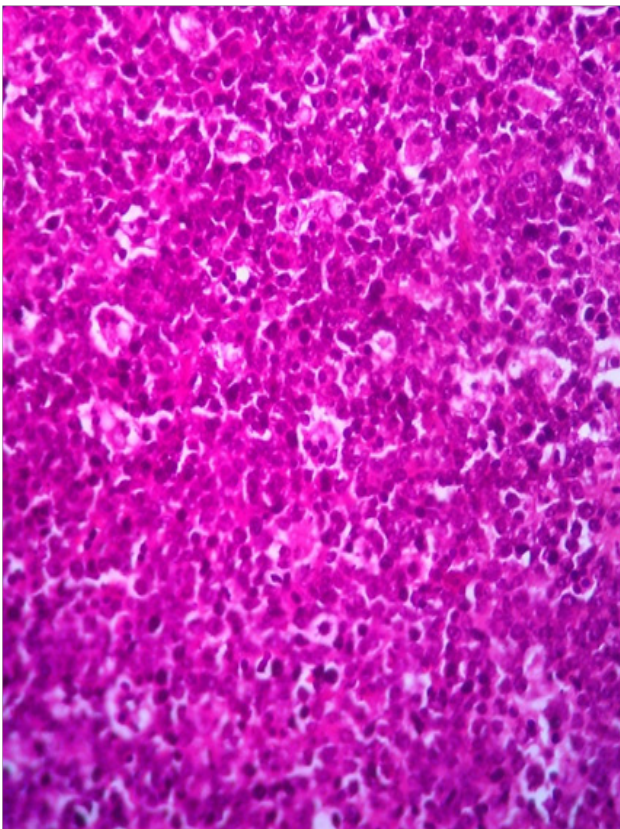
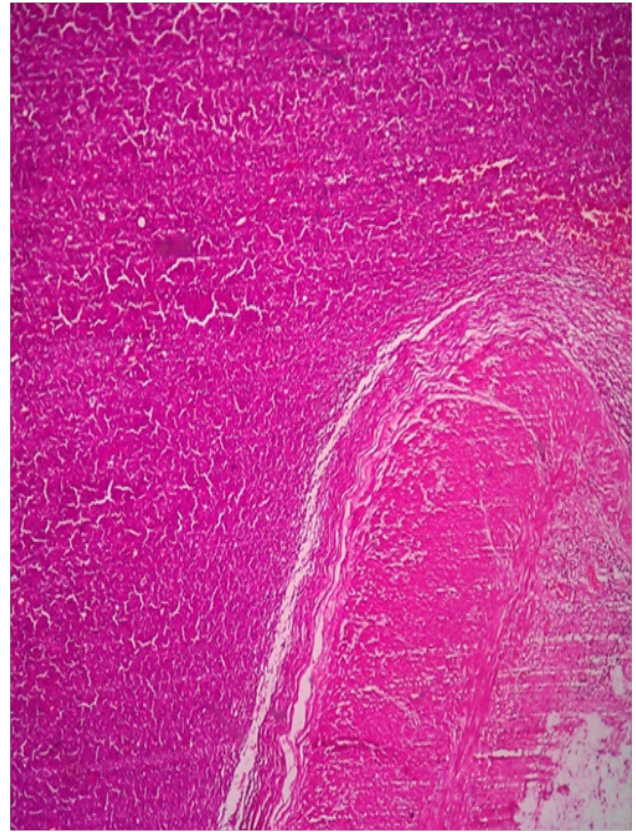
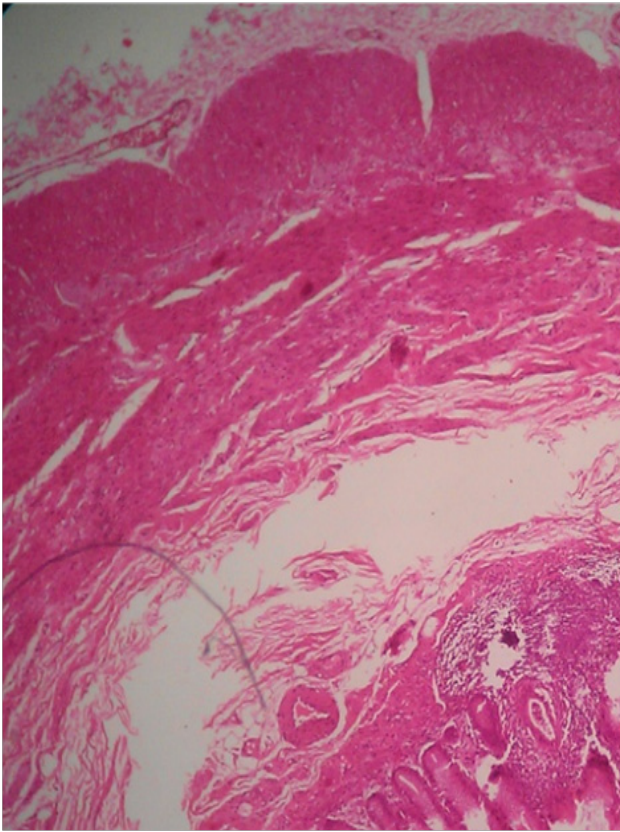


Fig. 2:

A) Low power (Hematoxylin & Eosin $\times 40$);
B) lymphoma cells infiltrated along the wall of the appendix (Hematoxylin & Eosin $\times 100$);
C) High power view showing lymphoma cells with numerous mitotic figures and apoptotic bodies (Hematoxylin & Eosin $\times 400$). Sheets and cords of highly neoplastic lymphoblasts with high N/C ratio, hyperchromasia, apoptotic bodies.

Case 2

A 23-year-old male presented with fever, abdominal pain, vomiting, diarrhea and slight leukocytosis ($11.8 \times 10^3/\text{mL}$). Ultrasonography and abdominal CT-scan showed an appendicular mass and features which were strongly suggestive of appendicular abscess. The patient underwent

laparotomy surgery.

During the surgery, a 7×4 cm tumor was revealed in the body of the perforated appendix. The

cecum was normal in appearance, the resected appendix distended by a gray-white mass that infiltrated along the wall of the appendix. The

Archive of SID

morphological and immunohistochemical examination showed typical finding of Burkitt's lymphoma including positive for CD20, CD79a, CD10, and ki67 (expressed in about 90% of lymphoma cells). Further extensive investigation including staging (scans of the chest, abdomen and pelvis) and MRI did not reveal any residual of malignancy. The patient was treated with CODOX-M/IVAC chemotherapy regime. At recent follow up, 17 months after surgery, the patient had no local recurrence, metastasis, or lymphadenopathy (Fig 2).

Case 3

A 24-year-old women presented with increasing colicky pain in right lower abdomen for the past 3 days, associated with low-grade fever and two episodes of vomiting, and a right lower quadrant tenderness in clinical examination. Para clinical tests were unremarkable except for increased erythrocyte sedimentation rate (55 mm/h). Abdominal ultrasound showed features of an appendicular mass which features were strongly suspicious for appendicular abscess. The patient underwent laparotomy appendectomy. The appendix measured 8×7×4 cm and the mass arising in the mid-third of the appendix measured 3×2 cm.

The histological and immunohistochemical studies showed lymphoma cells with numerous mitotic figures, apoptotic bodies and nuclear moldings and immunohistochemistry were positive for CD20, CD79a, CD10, and ki67 (expressed about 90% of lymphoma cells) and final diagnosis of appendicular Burkitt's lymphoma was made. Further studies including formal staging revealed that tumor was limited to the appendix. The patient was put on CODOX-M/IVAC chemotherapy regime. The patient in post-operative follow-up was uneventful and had no

evidence of recurrence nearly 18 months after surgery and chemotherapy.

Review of Literature

Appendix cancers are found in less than 1% of appendectomy specimens (1). According to the report published by the National Cancer Institute of Iran using the Surveillance, Epidemiology and End Results (SEER) database from 1973 to 1988, the incidence of appendiceal cancer was 0.12 cases per 100,000 people per year and the most common histology was mucinous adenocarcinoma (6). Recent immunohistochemical, molecular, and genetic evidences support an origin in the appendix in most cases with secondary involvement of the peritoneum or ovaries (7). Recently, the appendiceal carcinoma classified separately from colorectal tumor, in the seventh edition of the American joint committee on cancer staging manual (8). An analysis from 1973 to 2004 according to SEER database of appendiceal cancers (n=2791) showed that adenocarcinoma accounted for 65.4% of appendiceal cancers, followed by neuroendocrine neoplasms (9). The incidence of neuroendocrine neoplasms seemed to be stable whereas that of adenocarcinoma increased 2.6 fold during the study period. The reported 5 years survival was 47.9% for adenocarcinoma, 47.7% for mucinous adenocarcinoma, 59.5% for mucinous cyadenocarcinoma, 20.3% for signet ring cell carcinoma, and 1.7% for lymphoma (9).

Appendiceal tumors can be broadly classified as epithelial and non-epithelial tumors (10). There are many existing classifications of epithelial appendiceal neoplasms and this reflects the lack of consensus among pathologists (2, 7, 11, 12). Misdraji and Young in 2004 adapted and clarified classification of appendiceal neoplasm (Table 1) (2).

Table 1- Classification of appendiceal neoplasms*

Primary
Epithelial
Benign
Hyperplastic polyp and diffuse mucosal hyperplasia
Serrated adenoma
Colonic type adenomas
Malignant
Low-grade mucinous neoplasms
Adenocarcinoma/high-grade mucinous neoplasms
Non-epithelial
Carcinoid tumors
Classical carcinoid
Goblet cell carcinoids/adenocarcinoids
Mesenchymal tumors
Gastrointestinal stromal tumors
Neuroma
Leiomyoma/sarcoma
Kaposi's sarcoma
Lymphoma
Secondary
Ovarian
Colonic
Rare, such as melanoma

*Adapted from Misdraji and Young's 2004 classification of epithelial lesions of the appendix³.

Non-epithelial tumors of the appendix

Carcinoid tumors can arise from the neuroendocrine cells of any part of the gastrointestinal tract and are the most common primary neoplasm in the appendix (1, 13, 14). Although, in recent years the incidence and prevalence of carcinoid tumors have conflicting statistics, in many of the older articles, incidence was stated as one to two in 100,000 (15, 16). Newer data shows that the incidence may be double and some recent studies show adenocarcinoma incidence increased compared to carcinoid tumor (9). In summary, appendicular carcinoid are detected in 1-2 /100,000 of appendectomy specimens and most commonly present as appendicitis or as an incidental lesion at appendectomy, laparotomy or laparoscopy (4). A carcinoid of the appendix is most likely to be located in the tip or distal third of the appendix,

and is usually small, round, well demarcated, and bulbous swelling (1, 17, 18). Small carcinoid of the appendix rarely metastasizes (16). Adverse prognostic features with an increased risk of metastasis include tumors greater than 2 cm (1, 17, 18) and mesoappendiceal extension (18). Tumor proliferation indices (ki 67) may play a role as a guide to prognosis in the future (19, 20).

The extent of surgery is based upon the size of the tumor, but since the majority of carcinoid tumors are found incidentally on simple appendectomies, a second surgery is sometimes required. The National Comprehensive Cancer Network (NCCN) guidelines for treatment of carcinoid tumors state that tumors less than 2 cm and confined to the appendix can be treated with simple appendectomy without any follow up (4). For tumors greater than 2 cm, or those with extra appendiceal invasion, an appendectomy with right hemicolectomy and cytoreductive surgery is necessary. In addition, a post-operative follow-up, 3 month after surgery which includes a history and physical examination, CT of abdomen and testes for markers (5-HIAA and chromogranin A) should be completed (4). Generally, the prognosis is very good for carcinoid tumor confined to the appendix. If the tumor is confined to the appendix, the disease is said to have a 5-year survival rate of 94% (16). Goblet cell carcinoid tumor is a rare variant of appendiceal carcinoid which has histological features of adenocarcinoma as well as carcinoid tumor, otherwise known as adenocarcinoid or mucinous carcinoid. They can secrete mucus and are prone to spread beyond the appendix (3). Right hemicolectomy is therefore recommended for these neoplasms if they have spread beyond the appendix (21).

Epithelial lesion of the appendix

Benign epithelial lesion

Mucocele or retention cyst: A dilated appendix resulting from non-neoplastic obstruction lumen, measuring less than 2 cm that usually appeared an incidental findings (3).

Archive of SID

Hyperplastic polyp: It is an incidental findings occasionally presenting with appendicitis without cellular atypia (22). Adenomatous polyp and serrated adenoma (Mixed hyperplastic-adenomatous) rarely may be seen in appendix presented an incidental finding or diagnosed in patients who suspected with appendicitis or lower quadrant mass (22).

Benign lesion of the appendix can generally be treated by simple appendectomy or limited cecal resection if the base of appendix is involved (3).

Malignancy epithelia lesion

These malignant neoplasms are ranged from low-grade mucinous neoplasm to frank adenocarcinomas. Often the true classification these neoplasm over the time with considering patient survival can be clarified (3). Rennett *et al.* (11, 22) have classified appendiceal mucinous neoplasms into three groups: disseminated peritoneal adenomucinosis, peritoneal mucinous carcinomatosis, and intermediate group. Others have classified mucinous neoplasms into low-grade mucinous neoplasms and adenocarcinoma (high-grade neoplasm) (23, 24). In view of the difficulties in pathological classification, every team specializing in treatment of appendiceal malignancy should establish a clear communication with pathologist to have a common language when classifying the appendix tumor (7).

Low-grade mucinous neoplasms

A variety of terms have been classified in this group including cytadenomas, mucinous tumor of unknown/uncertain potential, disseminated peritoneal adenomucinosis, malignant mucocele and borderline appendiceal tumors (2, 22). These tumors may spread to the peritoneal cavity, producing mucinous intraperitoneal ascites, resulting in a syndrome called pseudomyxoma peritonei (24-26). One alternative view is that any production of mucin by epithelium outside the appendix indicates a mucinous carcinoma,

varying from low-grade to high-grade mucinous adenocarcinoma (22). Perforated low-grade mucinous neoplasm with extraappendiceal mucin always result in pseudomyxoma peritonei syndrome that are best treated with macroscopic tumor remove (cytoreduction) combined with an intraperitoneal chemotherapy regimen (26, 27).

Appendiceal adenocarcinoma

Appendiceal adenocarcinomas are rare, with reported incidence varying from 0.08% to 0.1% of all appendectomy specimen (6). It is becoming apparent that adenocarcinoma of the appendix may be more common than previously reported (7). Mucinous carcinomas are more common in the appendix than the colon and account for 40% to 67% of all appendiceal adenocarcinomas (28) compared with 11% to 30% of colorectal carcinomas (29). They can produce extracellular mucin and a pseudomyxoma peritonei type syndrome. It can be difficult to distinguish, either clinically or pathologically, patients with disseminated mucinous adenocarcinoma from those with true pseudomyxoma peritonei secondary to low-grade mucinouse neoplasm (3). Intestinal type adenocarcinoma and signet-ring cell adenocarcinoma of the appendix are less common (3), but if the histologic type has significant prognostic factor or not is controversial (28, 30). Adenocarcinoma of the appendix has been traditionally treated with right hemicolectomy with improved survival in patients undergoing right hemicolectomy compared with appendectomy alone (31), but if pseudomyxoma peritonei syndrome is present, right hemicolectomy should not be performed unless as part of a complete cytoreduction combined with intraperitoneal chemotherapy (32). The role of chemotherapy in adenocarcinoma without lymph node involvement not clear (4).

Lymphoma

The gastrointestinal tract is the most common site for extranodul lymphoma. The stomach is

the most common site, followed by small intestine, pharynx, colon and esophagus (4). Lymphoma of the appendix is almost exclusively non-Hodgkin's B-cell lymphoma, more specifically Burkitt's lymphoma has been estimated 0.015% of appendectomy specimen (5). Men are more likely to develop appendiceal lymphoma over women by 1.5:1 with a median age onset of 18 years (33).

Similar to many other primary tumors of the appendix, patients typically present with symptoms similar to acute appendicitis. Other symptoms that patients presented with them includes right iliac fossa pain for a few months or palpable mass in right lower quadrant (4).

When imaging is done, the appendix demonstrates prominent enlargement, while remains the vermiform appendix shape (4). As with all lymphoma's, for treatment, chemotherapy is required. The classic combination of cyclophosphamide, doxorubicin, vincristine and prednisone (CHOP) is accepted treatment and recently rituximab, a monoclonal antibody against CD20 has been added (34) that complete response to chemotherapy due to this drug increased (34). The combination of CHOP and rituximab is standard of care for large B-cell lymphoma in the US (4). For Burkitt's lymphoma, a more aggressive chemotherapy regimen is required (4).

Primary signet ring cell carcinoma

This cancer is very rare and have poor prognosis and high percentage of distance disease at the time of presentation (4). The most common presentation is acute appendicitis and treatment is right hemicolectomy. The role of chemotherapy as a treatment in signet ring cancers of the appendix is not clear (34).

Ganglioneuroma

It is an extremely rare cancer associated with neurofibromatosis, MEN 2b, congenital defects, carcinomas and various polyp forming disease (4). All of the three reported cases, treated with

surgical removal.

Discussion

Malignant lymphoma comprises approximately up to 1% to 4% of the gastrointestinal malignant neoplasms (35). Primary appendicular lymphoma is even rarer and often a postoperative diagnosis with the reported incidence of approximately 0.015% in a large series of 710,000 human appendectomy specimens (5). The most common presenting symptom was pain in the right iliac fossa occurring over a period of few months and frequently associated with a palpable mass (4). Muller *et al.* reported four cases of lymphoma presenting as acute appendicitis (36). Our cases also presented with abdominal pain and all underwent laparotomy surgery with suspicion to appendicitis.

Men are more likely to develop appendiceal lymphoma over women by 1.5:1 with a median age onset of 18 years (33). Two of our reported cases were male that is compatible with other studies. Although, there are numerous reports of acute surgical presentations of appendicular Burkitt's lymphoma, all of the cases have been reported in children and young adults (5, 33). Similarly, in our cases, the first case was a child and the other two patients were young adults. Although, there are no classical imaging features of appendiceal lymphoma, enlargement of appendix beyond 1.5 cm in diameter on CT-scan should be viewed with suspicion, and a diameter above 2.5 cm should be even more concerning (37). In the appendiceal lymphoma, as with all lymphoma, chemotherapy for treatment is required.

Appendix cancer is rare and most commonly found incidentally in an appendectomy specimen that performed for an unrelated condition (4). The classification and management are confusing and there are few substantial reports in the literature (3). The main histological types are carcinoid, adenocarcinoma, adenocarcinoid, cystadenoma, and cystadenocarcinomas (4). Most patients with carcinoid tumors have localized disease and the

prognosis is excellent, but reoperation and right colectomy is recommended for tumors larger than 2 cm or those with mesoappendiceal invasion (4, 16). Appendectomy alone is sufficient therapy for benign appendiceal mucocoeles, cystadenomas, and some cystadenocarcinoma (3). Right hemicolectomy performed for cystadenocarcinoma, with mesenteric or adjacent organ involvement and complicated mucocoeles with involvement of the terminal ileum or cecum (31). Pseudomyxoma peritonei symptoms treated with macroscopic tumor remove cytoreduction combined with an intraperitoneal chemotherapy regimen (26, 27).

Finally, the appendiceal adenocarcinoma can be treated with appendectomy alone or right hemicolectomy, but the role of chemotherapy is not clear. However, it seems to be accepted in adenocarcinoma with lymph node involvement (3, 31, 32). Our three cases were Burkitt's lymphoma, that is highly aggressive B-cell non-Hodgkin lymphoma and children and immunocompromised patients are most often affected by disease.

Conclusion

Appendiceal neoplasm is uncommon and consists of a heterogeneous group of pathologies and many present as appendicitis, but may be encountered as an unexpected finding at laparoscopy or laparotomy, or on pre- or post-operative imaging. Knowledge of the different types of neoplasm and appropriate treatment allows the surgeon to provide patients with optimal care and referral to a specialist center if appropriate.

Acknowledgements

The authors declare that there is no conflict of interest.

References

1. Connor SJ, Hanna GB, Frizelle FA. Appendiceal tumors: retrospective clinicopathologic analysis of appendiceal tumors from 7,970 appendectomies. *Dis Colon*

Rectum 1998;41(1):75-80.

2. Misdraji J, Young RH. Primary epithelial neoplasms and other epithelial lesions of the appendix (excluding carcinoid tumors). *Semin Diagn Pathol* 2004;21(2):120-33.

3. Murphy EM, Farquharson SM, Moran BJ. Management of an unexpected appendiceal neoplasm. *Br J Surg* 2006;93(7):783-92.

4. Ruoff C, Hanna L, Zhi W, Shahzad G, Gotlieb V, Saif MW. Cancers of the appendix: review of the literatures. *ISRN Oncol* 2011;2011:728579.

5. Collins DC. 71,000 Human Appendix Specimens. A Final Report, Summarizing Forty Years' Study. *Am J Proctol* 1963;14:265-81.

6. McCusker ME, Cote TR, Clegg LX, Sobin LH. Primary malignant neoplasms of the appendix: a population-based study from the surveillance, epidemiology and end-results program, 1973-1998. *Cancer* 2002;94(12):3307-12.

7. Shankar S, Ledakis P, El Halabi H, Gushchin V, Sardi A. Neoplasms of the appendix: current treatment guidelines. *Hematol Oncol Clin North Am* 2012;26(6):1261-90.

8. Yaguchi C, Oi H, Kobayashi H, Miura K, Kanayama N. A case of intravenous leiomyomatosis with high levels of hyaluronan. *J Obstet Gynaecol Res* 2010;36(2):454-8.

9. Gustafsson BI, Siddique L, Chan A, Dong M, Drozdov I, Kidd M, Modlin IM. Uncommon cancers of the small intestine, appendix and colon: an analysis of SEER 1973-2004, and current diagnosis and therapy. *Int J Oncol* 2008;33(6):1121-31.

10. Misdraji J. Appendiceal mucinous neoplasms: controversial issues. *Arch Pathol Lab Med* 2010;134(6):864-70.

11. Ronnett BM, Zahn CM, Kurman RJ, Kass ME, Sugarbaker PH, Shmookler BM. Disseminated peritoneal adenomucinosis and peritoneal mucinous carcinoma: a clinicopathologic analysis of 109 cases with emphasis on distinguishing pathologic features, site of origin, prognosis, and relationship to "pseudomyxoma peritonei". *Am J Surg Pathol* 1995;19(12):1390-408.

12. Williams RA, Whitehead R. Non-carcinoid epithelial tumours of the appendix--a proposed classification. *Pathology* 1986;18(1):50-3.

13. Bucher P, Mathe Z, Demirag A, Morel P. Appendix

- tumors in the era of laparoscopic appendectomy. *Surg Endosc* 2004;18(7):1063-6.
14. Carr NJ, Sobin LH. Neuroendocrine tumors of the appendix. *Semin Diagn Pathol* 2004;21(2):108-19.
15. Godwin JD, 2nd. Carcinoid tumors. An analysis of 2,837 cases. *Cancer* 1975;36(2):560-9.
16. Modlin IM, Sandor A. An analysis of 8305 cases of carcinoid tumors. *Cancer* 1997 Feb 15;79(4):813-29.
17. Moertel CG, Dockerty MB, Judd ES. Carcinoid tumors of the vermiform appendix. *Cancer* 1968;21(2):270-8.
18. Roggo A, Wood WC, Ottinger LW. Carcinoid tumors of the appendix. *Ann Surg* 1993;217(4):385-90.
19. Goede AC, Caplin ME, Winslet MC. Carcinoid tumour of the appendix. *Br J Surg* 2003;90(11):1317-22.
20. Sokmensuer C, Gedikoglu G, Uzunalimoglu B. Importance of proliferation markers in gastrointestinal carcinoid tumors: a clinicopathologic study. *Hepatogastroenterology* 2001;48(39):720-3.
21. Gordon R, Burns K, Friedlich M. Goblet cell carcinoid of the appendix. *Can J Surg* 2005;48(3):251-2.
22. Carr NJ, McCarthy WF, Sobin LH. Epithelial non-carcinoid tumors and tumor-like lesions of the appendix. A clinicopathologic study of 184 patients with a multivariate analysis of prognostic factors. *Cancer* 1995 Feb 1;75(3):757-68.
23. Miner TJ, Shia J, Jaques DP, Klimstra DS, Brennan MF, Coit DG. Long-term survival following treatment of pseudomyxoma peritonei: an analysis of surgical therapy. *Ann Surg* 2005;241(2):300-8.
24. Moran BJ, Cecil TD. The etiology, clinical presentation, and management of pseudomyxoma peritonei. *Surg Oncol Clin N Am* 2003;12(3):585-603.
25. Hinson FL, Ambrose NS. Pseudomyxoma peritonei. *Br J Surg* 1998;85(10):1332-9.
26. Sugarbaker PH, Ronnett BM, Archer A, Averbach AM, Bland R, Chang D, *et al.* Pseudomyxoma peritonei syndrome. *Adv Surg* 1996;30:233-80.
27. Sugarbaker PH, Chang D. Results of treatment of 385 patients with peritoneal surface spread of appendiceal malignancy. *Ann Surg Oncol* 1999;6(8):727-31.
28. Ito H, Osteen RT, Bleday R, Zinner MJ, Ashley SW, Whang EE. Appendiceal adenocarcinoma: long-term outcomes after surgical therapy. *Dis Colon Rectum* 2004;47(4):474-80.
29. Papadopoulos VN, Michalopoulos A, Netta S, Basdanis G, Paramythiotis D, Zatagias A, *et al.* Prognostic significance of mucinous component in colorectal carcinoma. *Tech Coloproctol* 2004;8 Suppl 1:s123-5.
30. Kabbani W, Houlihan PS, Luthra R, Hamilton SR, Rashid A. Mucinous and nonmucinous appendiceal adenocarcinomas: different clinicopathological features but similar genetic alterations. *Mod Pathol* 2002;15(6):599-605.
31. Lo NS, Sarr MG. Mucinous cystadenocarcinoma of the appendix. The controversy persists: a review. *Hepatogastroenterology* 2003;50(50):432-7.
32. Gonzalez-Moreno S, Brun E, Sugarbaker PH. Lymph node metastasis in epithelial malignancies of the appendix with peritoneal dissemination does not reduce survival in patients treated by cytoreductive surgery and perioperative intraperitoneal chemotherapy. *Ann Surg Oncol* 2005;12(1):72-80.
33. Stewart RJ, Mirakhur M. Primary malignant lymphoma of the appendix. *Ulster Med J* 1986;55(2):187-9.
34. Khanna M, Buddhavarapu SR. Primary Burkitt's Lymphoma Of The Appendix Presenting As Acute Abdomen: A Case Report. *J Radiol Case Rep* 2008;2(5):9-14.
35. Pasquale MD, Shabahang M, Bitterman P, Lack EE, Evans SR. Primary lymphoma of the appendix. Case report and review of the literature. *Surg Oncol* 1994;3(4):243-8.
36. Muller G, Dargent JL, Duwel V, D'Olne D, Vanvuchelen J, Haot J, *et al.* Leukaemia and lymphoma of the appendix presenting as acute appendicitis or acute abdomen. Four case reports with a review of the literature. *J Cancer Res Clin Oncol* 1997;123(10):560-4.
37. Pickhardt PJ, Levy AD, Rohrmann CA, Jr., Abbondanzo SL, Kende AI. Non-Hodgkin's lymphoma of the appendix: clinical and CT findings with pathologic correlation. *AJR Am J Roentgenol* 2002;178(5):1123-7.