

# Case Report

## Retroperitoneal Anaplastic Neuroblastoma 3-Year-Old Female: A Rare Case Report

Shravasti Roy, Indranil Das, Ayandip Nandi, Soma De

*Dept. of Pathology and Paediatric Oncology, Saroj Gupta Cancer Centre  
and Research Institute, Kolkata, India*

### ABSTRACT

Neuroblastoma is the most common extracranial solid tumor in childhood. In different classification of neuroblastomas, a subset of undifferentiated or poorly differentiated tumors with bizarre histological features has been mentioned. A 3-year-old girl presented with abdominal pain. Her haematological and biochemical parameters were normal except her urinary vanilylmandelic acid level was elevated five times the normal value (64.4 IU/ml). On computed tomography scan, a retroperitoneal contrast-enhancing mass was visible around D12-D13 region (60×52×47mm). Sections of CT guided trucut biopsy revealed large cells with pleomorphic nuclei, abundant cytoplasm and occasional multinucleated giant cells. Immunohistochemistry showed the cells reactive for neuron specific enolase, chromogranin-A, synaptophysin, non-reactive for cytokeratin, desmin and glial fibrillary acid protein and Alk-1. A diagnosis of anaplastic neuroblastoma was made. The child is currently under chemotherapy and doing well.

**Keywords:** Neuroblastoma; Retroperitoneal Space, Case Report

### Introduction

**N**euroblastoma is the most common extracranial solid tumor in childhood (1). Eighty percent of the cases occur under

the age of 4 years; median age at diagnosis is 21 month. There is no sex predilection. The usual presentation is abdominal mass noticed by parents (2). Neuroblastoma comprises 6-10% of all childhood cancers, and 15% of cancer deaths in

---

*Received: 18 December 2013*

*Accepted: 27 June 2014*

*Address Communications to:*

*Dr. Ayandip Nandi, Department of Pathology and Paediatric Oncology, Saroj Gupta Cancer Centre and Research Institute, Mahatma Gandhi road, Thakurpukur, Kolkata, India.*

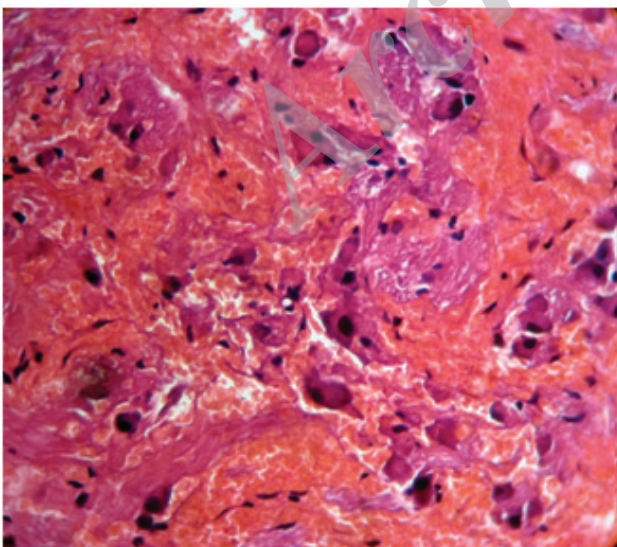
*Email: ayandipnandi@gmail.com*

children. The annual mortality rate is 10 per million children in the 0- to 4-year-old age group, and 4 per million in the 4- to 9-year old age group (3). In different classification of neuroblastomas, a subset of undifferentiated or poorly differentiated tumors with bizarre histological features has been mentioned but very few cases have been reported so far(4). The exact incidence of anaplastic neuroblastoma is difficult to predict because of widely scattered case reports. Recently, Toroczky et al. reported the clinical course, biologic and pathologic aspects of a group of 7 such cases, which they named large cell neuroblastomas(5). The marked pleomorphism and anaplastic features of the cells in these tumors were associated with a more aggressive clinical behavior.

Here we are presenting a case, which showed histological features of anaplasia under microscope. We evaluated the immunohistochemical features of the tumor and followed the response to therapy and prognosis.

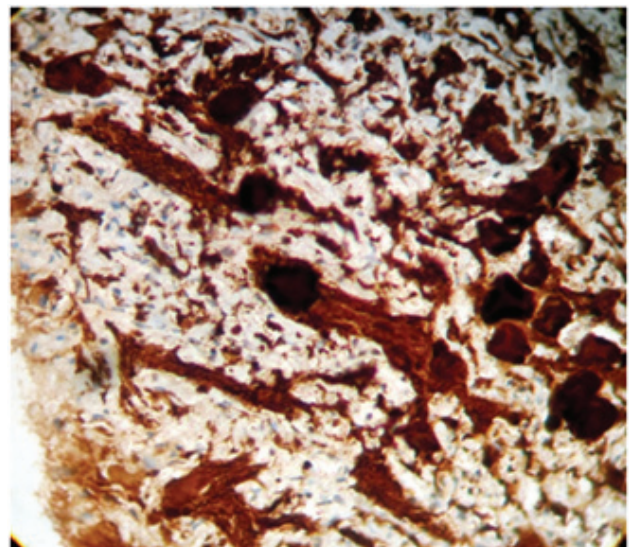
### Case History

A 3 year old Muslim girl from Bangladesh presented with complaints of abdominal pain.

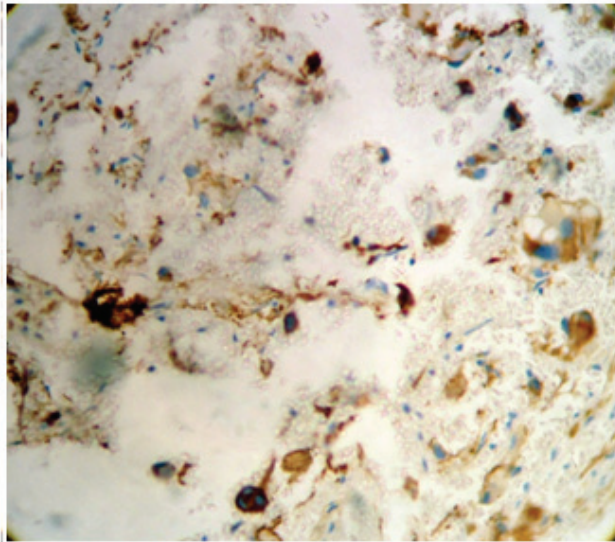


**Fig. 1:** Histopathology of trucut biopsy showing large multinucleated giant cell (H&E, ×400)

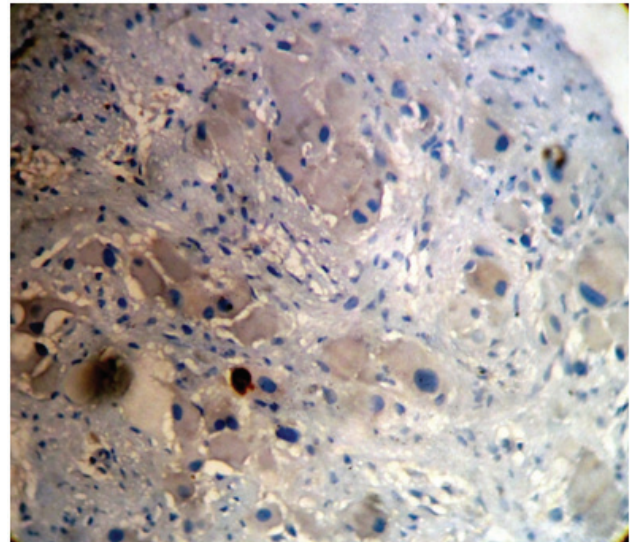
On examination, no mass was palpable per abdomen. Her haematological and biochemical parameters were within normal limits except her urinary vanillylmandelic acid level was elevated 5 times the normal value (64.4 IU/ml). On computed tomography (CT scan) a retroperitoneal contrast-enhancing mass was visible around D12-D13 region (60×52×47mm). CT guided trucut biopsy was done and sections revealed large cells with pleomorphic nuclei, abundant well defined cytoplasm and occasional multinucleated giant cells (Fig.1). Calcific bodies were present in the background. Wide areas of hemorrhage, necrosis and prominent desmoplasia in stroma were accompanying features. Immunohistochemistry showed the cells were reactive for synaptophysin (Fig.2 showing cytoplasmic positivity in tumour cells), chromogranin-A, Neuron Specific enolase (Fig.3 shows cytoplasmic granular reactivity in tumour cells proving their neural differentiation), non-reactive for cytokeratin, desmin and glial fibrillary acid protein. Alk-1 was negative (Fig.4). A diagnosis of anaplastic neuroblastoma was made. The child is currently under chemotherapy regimen and doing well.



**Fig. 2:** synaptophysin reactivity in tumour cell (Synaptophysin, ×400)



**Fig. 3:** Neuron specific enolase reactivity in tumour cell(NSE,×400)



**Fig. 4:** Alk-1 negative tumour cells (Alk-1,×400)

### Discussion

The present case meets the morphologic and immunohistochemical, criteria of an undifferentiated neuroblastoma (Schwannianstroma poor) anaplastic variant, following the guidelines of the new 'The International Neuroblastoma Pathology Classification'(INPC)(4).

Neuroblastoma is a common childhood cancer that arises in the tissues of the sympathetic nervous system(6). Several morphologic features indicate poor outcome such as high mitosis-karyorrhexis index as well as lack of differentiation. MKI is determined by using 5000 tumour cells as denominator. Neuroblastomas having a neuropil background are referred to as poorly differentiated if only 5% or less tumour cell population show features of differentiation toward ganglion cells. These findings correlate with outcome(7). In our study also, macronucleoli and marked pleomorphism was a prominent feature. The differential diagnosis from the morphologic point of view should include all the abdominal malignancies of childhood that could present cell pleomorphism, e.g., primitive rhabdomyosarcoma, anaplastic Wilmstumour, atypical Ewing sarcoma-PNET, desmoplastic small round cell sarcoma, rhabdoidtumour,

and/or lympho-hematopoietic neoplasms. Immunophenotypic results lead to the diagnosis of neuroblastoma; absence of muscle(desmin), epithelial(Epithelial membrane antigen), lymphoid (CD45) factors as well as the negativity of CD99 excludes the above mentioned tumors. We did not evaluate the genetic alterations in this case, though there were some genetic alterations that had prognostic implications. Recurrent genetic changes were identified in primary cells and cell lines derived from neuroblastomas in children. The most frequently observed karyotype change observed in tumours and cell lines was deletion or unbalanced reciprocal translocations involving chromosome 1p. Unbalanced rearrangements involving chromosome 17, frequently with chromosomes 1 and 11, loss of heterozygosity for 1p, 4p, 11q, 14q, and 17p; and extra copies of 17q also have been reported (8). Amplification of the N-myc oncogene also frequently occurs, with the additional copies of the gene, normally on chromosome 2, found associated with multiple chromosomes both in double minute extrachromosomal chromatin bodies and in integrated homogeneously staining regions. The occurrence of 1p deletion and N-myc amplification are correlated with poor prognosis. Extra copies of 17q also have recently been

correlated with poor outcome. In contrast, expression of the *trk-A* protooncogene, which encodes the high-affinity nerve growth factor (NGF) receptor, is associated with favourable prognosis and inversely correlates with *N-myc* amplification(9). Recently, anaplastic lymphoma kinase (ALK) gain-of-function mutations have been described in both familial and sporadic neuroblastoma(10). Although there is currently no clinically approved treatment for ALK mutations in neuroblastoma, on-going clinical trials are expected to determine the potential usefulness of ALK- targeted therapies (crizotinib) for use in the future.

We reviewed the literature and also re-evaluated the immunohistochemical analysis. Standard guideline of treatment has been formulated for this rare entity. This differential diagnosis has to be remembered in diagnosis of small round cell tumours of childhood and immunohistochemistry is essential for the diagnosis.

### Conclusion

Anaplastic neuroblastoma should be considered in differential diagnosis of retroperitoneal mass with bizarre nuclear feature in children.

### Acknowledgements

The authors declare that there is no conflict of interests.

### References

1. Abramowsky CR, Katzenstein HM, Alvarado CS, Shehata BM. Anaplastic large cell neuroblastoma. *Pediatr Dev Pathol* 2009;12(1):1-5.
2. Esiashvili N, Goodman M, Ward K, Marcus RB Jr, Johnstone PA. Neuroblastoma in adults: Incidence and survival analysis based on SEER data. *Pediatr Blood Cancer* 2007;49(1):41-6.
3. Castleberry RP. Neuroblastoma. *Eur J Cancer* 1997;33(9):1430-7.
4. Peuchmaur M, d'Amore ES, Joshi VV, Hata J, Roald B, Dehner LP, et al. Revision of the International Neuroblastoma Pathology Classification: confirmation of favorable and unfavorable prognostic subsets in ganglioneuroblastoma, nodular. *Cancer* 2003;98(10):2274-81.
5. Tornóczky T, Kálmán E, Kajtár PG, Nyári T, Pearson AD, Tweddle DA, et al. Large cell neuroblastoma: a distinct phenotype of neuroblastoma with aggressive clinical behavior. *Cancer* 2004;100(2):390-7.
6. Maris JM. Recent advances in neuroblastoma. *N Engl J Med* 2010;362(23):2202-11.
7. Ambros IM, Zellner A, Roald B, Amann G, Ladenstein R, Printz D, et al. Role of ploidy, chromosome 1p, and Schwann cells in the maturation of neuroblastoma. *N Engl J Med* 1996;334(23):1505-11.
8. Morowitz M, Shusterman S, Mosse Y, Hii G, Winter CL, Khazi D, et al. Detection of single-copy chromosome 17q gain in human neuroblastomas using real-time quantitative polymerase chain reaction. *Mod Pathol* 2003;16(12):1248-56.
9. Caron H, van Sluis P, de Kraker J, Bökkerink J, Egeler M, Laureys G, et al. Allelic loss of chromosome 1p as a predictor of unfavorable outcome in patients with neuroblastoma. *N Engl J Med* 1996;334(4):225-30.
10. Janoueix-Lerosey I, Lequin D, Brugières L, Ribeiro A, de Pontual L, Combaret V, et al. Somatic and germline activating mutations of the ALK kinase receptor in neuroblastoma. *Nature*. 2008;455(7215):967-70.