

# Are Osteopontin and Ki67 Expressions Different in Various Histologic Grades of Meningioma? An Iranian Experience

Forough Hashemi<sup>1</sup>, Pegah Babaheidarian<sup>1</sup>, Soheila Dabiran<sup>2</sup>

1. Dept. of Pathology, Iran University of Medical Sciences, Tehran, Iran

2. Dept. of Social Community Medicine, Tehran University of Medical Sciences, Tehran, Iran

## KEY WORDS

Meningioma  
Ki67 Antigen  
Osteopontin

## ABSTRACT

**Background:** Meningioma is among the most common slow growing central nervous neoplasms, which recurs locally despite the benign histologic features. The aim of this study was to evaluate osteopontin and ki67 expressions in different histologic grades of meningioma in a group of Iranian people.

**Methods:** In this cross-sectional study, first, the paraffin blocks with the definite pathological diagnosis of meningioma in 70 patients were cut by microtome, in 4-5 micron sizes and stained for immunohistochemical markers of osteopontin and ki67. Then, all samples were evaluated for positive immunoreactivity and contributing factors.

**Results:** Among 70 patients studied, the mean for the Ki67 level was  $8.6 \pm 12.3$  and the mean for the osteopontin IHC score was  $45.2 \pm 77.9$ . There was a high correlation between markers, tumor recurrence and grade ( $P < 0.001$ ). In addition, there was a significant direct correlation between ki67 and osteopontin levels ( $P < 0.001$ ,  $r = 0.760$ ). In other words, as OPN and ki67 expressions increased, the chance of tumor recurrence increased.

**Conclusion:** ki67 and osteopontin expressions in patients with meningioma can be used as good prognostic markers for tumor recurrence and for distinguishing the grade of meningiomas.

©Iran J Pathol. All rights reserved.

## ARTICLE INFO

Received 25 May 2014;

Accepted 27 Sep 2014;

**Corresponding Information:** Dr. Pegah Babaheidarian, Rasoul Akram hospital, Nyayesh St. Sattarkhan Ave, Tehran, Iran.

Email: [pegah.heidarian@yahoo.com](mailto:pegah.heidarian@yahoo.com)

## Introduction

Meningioma is a common tumor of central nervous system, seen in 15% of cases. Its origin may be arachnoidal specialized cells. The most important contributing factor of tumor progression is histological grade defined according to WHO criteria (1-3). However, surgical treatment of these tumors, despite bone and dura matter involvement, may completely suppress the

recurrence of tumors; but in some cases of low-grade tumors unexpected recurrence are seen that may be present in 20% of cases with complete surgical removal and 80% of incomplete surgical removal (4).

This matter has led to study of contributing factors of recurrence in meningioma as reported in different investigations (5-7). Among these markers are osteopontin (OPN) that bind to integrin and may be involved in tumor

progression via apoptosis and production, adhesion, and migration of tumoral cells. The role of this marker on other cancers such as breast cancer has been evaluated. Osteopontin induces oncogenic and metastatic potential of several cancers by upregulating various signaling cascades. Osteopontin via integrin activates PI3K/AKT signalling that confers cytoprotection and promotes cancer cell survival. However, there is little knowledge about its involvement in progression of meningioma. On the other hand; Ki-67 is a nuclear marker responsible for cellular proliferation. It has been used for grading of meningioma and has association with different histological grades of meningioma; showing more proliferative activity in malignant cases rather than benign tumors (8-10).

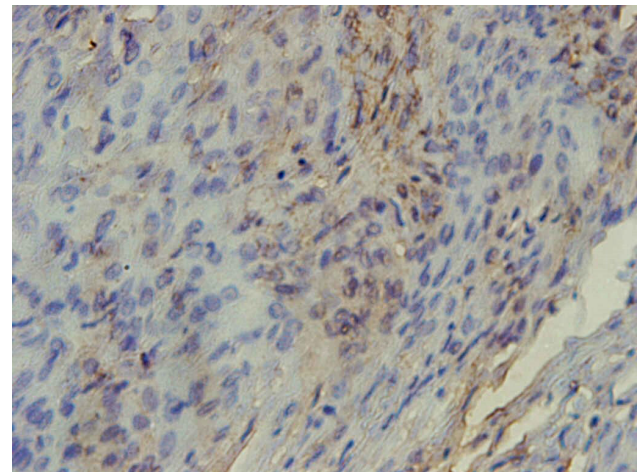
In this study, we investigated the OPN expression for meningioma in different histologic grades, correlation with ki67 and its role for predicting the tumor recurrence.

## Methods and Materials

In this cross-sectional study in two academic hospitals of Rasoul Akram and Firouzgar, during 2006-2010, 70 consecutive cases of meningioma with different histologic grades were enrolled and their medical documents were evaluated. The insufficient samples, the patients with simultaneous tumors and impossibility of following up the patients, were exclusion criteria. Initially the paraffin blocks and slides of those with diagnosis of meningioma were selected and reevaluated. Then some 4-5 micron slices were developed by microtome and were stained immunohistochemically for osteopontin and ki-67. In all slides, the intensity and extent of immunoreactivity were explored as stained cells percent. Mouse monoclonal antibody Anti-OPN (ab53) catalog number, 69498 with 1:1000 dilution from ABCAM Company and monoclonal antibody Ki-67 catalog number, 7240 with 1:100 dilution from Dako Company were

used by complex of biotin-avidin-peroxidase under manufacturer instructions.

For osteopontin staining, it was performed by hand in room temperature. Endogenous peroxidase and non-selective background was blocked by incubation slides with hydrogen peroxide 10%. After washing with phosphate buffer saline for 5 min, the slides were washed by normal saline for 20 min. The slides were incubated with Anti-OPN for 60 min. After washing with phosphate saline buffer for 5 min, the biotinylated secondary antibody was used for incubation with 20 min duration. Again, after washing with phosphate buffer saline for 5 min, the slides were incubated with avidin-biotin complex for 30 min and rewashed. Chromogen dilution was performed with mixing the 3, 3 DAB/THC in tris buffer for two minutes. All samples were counterstained by hematoxyline for 30 seconds. The psammomas meningioma was considered as positive control of staining due to presence of psammoma body. The intensity grading for osteopontin was rated from 0 to 4 (cytoplasmic reaction from none to strong reaction) and for more accuracy the percent of positive cells were also calculated and IHC score

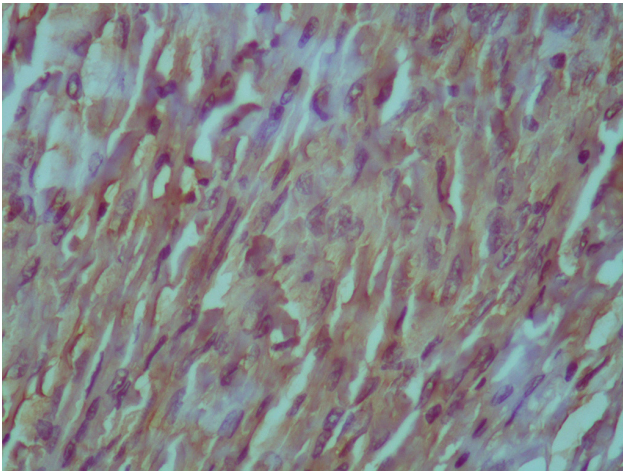


**Fig. 1**  
Weak osteopontin cytoplasmic staining ( $\times 400$ )

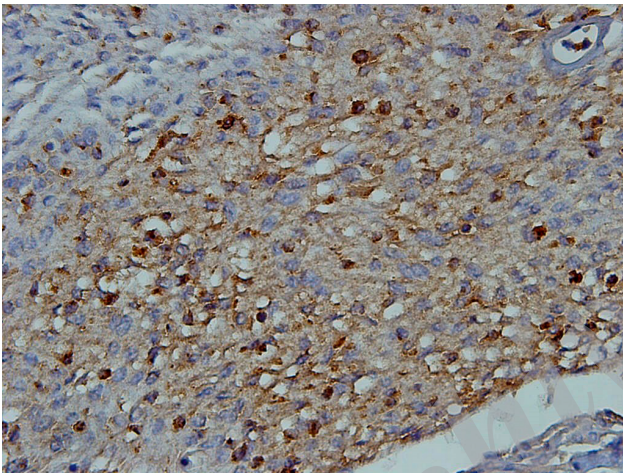
reported from zero to 400 (Fig. 1, 2, 3). For Ki-67 also the percent was used for expression of nuclear staining of cells.

Data analysis was performed by SPSS,

(version16) software [Statistical Procedures for Social Sciences; Chicago, Illinois, USA].



**Fig. 2**  
Weak to moderate osteopontin cytoplasmic staining ( $\times 400$ )



**Fig. 3**  
Moderate to strong osteopontin cytoplasmic staining ( $\times 400$ )

Independent-sample t and ANOVA tests were used for comparisons and were considered statistically significant at P values less than 0.05.

## Results

Among 70 patients studied, the mean age was  $48.8 \pm 10.28$  yr. Twenty-two patients (31.4%) were male. Twenty-seven patients (38.6%) had short-term recurrence (average 34 months). Among the cases, 75.7% were grade I, 20% atypical and 4.3% anaplastic. Between grade I,

36 (67.9%) were classic meningothelial type, 6 (11.3%), fibroblastic, and 11 (20.8%) were transitional. The mean Ki-67 and osteopontin IHC score were  $8.6 \pm 12.3$  and  $45.2 \pm 77.9$ , respectively. The mean ki67 index and IHC score of different grades of meningioma are shown

**Table 1**  
Mean Ki-67 and Osteopontin in different grades of meningioma

Parameteres	Ki67	Osteopontin
Mean	8.6143	42.2429
Median	2.0000	8.0000
Std.deviation	12.31741	77.92814
Minimum	0.00	0.00
Maximum	50.00	320.00
Percentile	25	1.0000
	50	2.0000
	75	12.7500
	90	30.0000
		156.0000

(Table 1).

Both Ki-67 index and osteopontin IHC score were significantly higher in atypical and

**Table 2**  
Mean Ki67 and Osteopontin in recurrent and non recurrent cases

Recurrence	Mean	Std.deviation
Osteopontin	Present	94.63689
	Absent	19.07730
Ki67	Present	14.56413
	Absent	5.00255

anaplastic meningiomas than in benign ones

( $P < 0.001$ ). In addition, the recurrent cases had higher osteopontin IHC score and Ki-67 index (Table 2).

There was no association between Ki-67 index and gender ( $P > 0.05$ ); but the osteopontin level was significantly higher in female subjects ( $P = 0.003$ ). Additional and interesting finding was that, the pathological type of tumors in grade I, had no association with levels of Ki-67 index and osteopontin IHC score ( $P > 0.05$ ). However, the age was not related to none of them ( $P > 0.05$ ). Discriminant analysis, found that, Ki-67 index and osteopontin IHC score were interrelated. ( $P < 0.001$ ,  $r = 0.760$ )

## Discussion

Although, grading the meningioma according to WHO criteria, usually easy, some times we encounter the unusual cases, difficult to grade; especially in tumors seem to be grade I, do not fulfill criteria for higher grades, but behave in aggressive fashion and recur more than the other benign meningiomas. Till now; many factors among proliferating markers are being investigated in meningioma.

Tseng et al. similarly reported association of recurrence and osteopontin level (1). Besides Takei et al. reported that Ki-67 was related to higher recurrence rate (4) as well as our study. Higher level of Ki-67 was associated with higher grade and also recurrence but not pathological type of tumor (11). A review study by Abry et al. reported significant association between Ki-67 level with recurrence and grade of meningioma as well our study (12).

Kolles et al. similarly demonstrated non-significant association between pathological type of tumor with Ki-67 but significant with grade (13). This matter was also reported by Akyildiz et al. (14). The association of Ki-67 level with recurrence and survival of meningioma patients is also shown by Bruna et al. (15).

However, according to our knowledge, there is

no clear cut off point for ki67 index suggested for meningioma, which is suitable for predicting its behavior. In this study, we investigated the OPN expression and correlation with ki67, as widely accepted marker for tumor recurrence. These two markers were interrelated but age and gender had no significant association with them. Pavelin et al. demonstrated the association of Ki-67 and P53 with tumor grade that this matter was true in our study about Ki-67 and osteopontin (16).

In our study, we investigated whether OPN expression was effective predictor of tumor recurrence in different histologic grades of meningioma, not just for meningioma grade I, reported by Arikök et al. (17). The more expressed OPN, the more possibility of tumor recurrence even in high-grade tumors. There was also no significant difference between OPN expressions in different subtypes of meningioma grade I. It seems that other factors are responsible for the progression of these tumors.

## Conclusion

ki67 and osteopontin levels in patients with meningioma of different grades may be good prognostic markers for tumor recurrence and also are related to grade of tumors. Therefore, these findings let us suppose these markers for grading meningioma as parallel as WHO criteria, although more comprehensive studies with larger samples including more high grade tumors as well, seems mandatory.

## Acknowledgment

The authors declare that there is no conflict of interest.

## References

1. Tseng KY, Chung MH, Sytwu HK, Lee HM, Chen KY, Chang C, et al. Osteopontin expression is a valuable marker for prediction of short-term recurrence in WHO grade I benign meningiomas. *J Neurooncol* 2010;

100(2):217-23.

2. Hancq S, Salmon I, Brotchi J, De Wihe O, Gabius HJ, Heizmann CW, et al. S100A5: a marker of recurrence in WHO grade I meningiomas. *Neuropathol Appl Neurobiol* 2004; 30(2):178-87.

3. Arrieta O, Garcia E, Guevara P, Garcia-Navarrete R, Ondarza R, Rembao D, et al. Hepatic growth factor is associated with poor prognosis of malignant glioma and is a predictor for recurrence of meningioma. *Cancer* 2002; 94(12):32108.

4. Takei H, Meenakshi B, Bhattacharjee, Rivera A, Yeongju dancer, Powell SZ. New immunohistochemical markers in the evaluation of central nervous system tumors: A review of 7 selected adult and pediatric brain tumors. *Arch pathol lab Med* 2007; 131(2):234-41.

5. Barresi V, Caffo M, Ieni A, Alafaci C, Tuccari G. Osteoblastic meningiomas: clinico-pathological and immunohistochemical features of an uncommon variant. *J Neuro-Oncol* 2011; 105(2):225-32.

6. Rodriguesa LR, Lopesb N, Sousab B, Vieira D, Milanezi F, Marie P, et al. Significance of Osteopontin Expression in Human Invasive Breast Tumour Stroma. *The Open Breast Cancer Journal* 2009; 1:1-9.

7. Rodrigues LR, Teixeira JA, Schmitt FL, Paulsson M, Lindmark-Månsson H. The role of osteopontin in tumor progression and metastasis in breast cancer. *Cancer Epidemiol Biomarkers Prev* 2007; 16(6):1087-97.

8. Coppola D, Szabo M, Boulware D, Muraca P, Alsarra M, Chambers AF, et al. Correlation of Osteopontin Protein Expression and Pathological Stage across a Wide Variety of Tumor Histologies. *Clin Cancer Res* 2004; 10:184.

9. Mairui F, De caro Mdel B, Esopoisto F, Cappabianca P, Strazzullo V, Petinti G, et al. Recurrences of meningioma: predictive value of pathological features and hormonal and growth factors. *J Neurooncol* 2007; 82:63-8.

10. Vankalakunti M, Vasishta RK, Das Radorta B,

Khosla VK. MIB-1 immunolabeling: A valuable marker in prediction of benign recurring meningioma. *J Neuropathol* 2007; 27(5):407-12.

11. Babu S, Uppin SG, Uppin MS, Panigrahi MK, Saradhi V, Bhattacharjee S, et al. Meningiomas: correlation of Ki67 with histological grade. *Neurol India* 2011; 59(2):204-7.

12. Abry E, Thomassen IØ, Salvesen ØO, Torp SH. The significance of Ki-67/MIB-1 labeling index in human meningiomas: a literature study. *Pathol Res Pract* 2010; 206(12):810-5.

13. Kolles H, Niedermayer I, Schmitt C, Henn W, Feld R, Steudel WI, et al. Triple approach for diagnosis and grading of meningiomas: histology, morphometry of Ki-67/Feulgen stainings, and cytogenetics. *Acta Neurochir (Wien)* 1995; 137(3-4):174-81.

14. Akyildiz EU, Oz B, Comunoglu N, Aki H. The relationship between histomorphological characteristics and Ki-67 proliferation index in meningiomas. *Bratisl Lek Listy* 2010; 111(9):505-9.

15. Bruna J, Brell M, Ferrer I, Gimenez-Bonafe P, Tortosa A. Ki-67 proliferative index predicts clinical outcome in patients with atypical or anaplastic meningioma. *Neuropathology* 2007; 27(2):114-20.

16. Pavelin S, Becic K, Forempoher G, Mrklic I, Pogorelic Z, Titic M, et al. Expression of Ki-67 and p53 in meningiomas. *Neoplasma* 2013; 60(5):480-5.

17. Arıkök AT, Onder E, Seçkin H, Kacar A, Fesil R, Oquz AZ, et al. Osteopontin expressions correlate with WHO grades and predict recurrence in meningiomas. *Brain Tumor Pathol* 2013 Jun 21. [In Press]

#### How to cite this article:

Hashemi F, Babaheidarian P, Dabiran S. Are Osteopontin and Ki67 Expressions Different in Various Histologic Grades of Meningioma? An Iranian Experience. *Iran J Pathol*. 2015; 10(4): 253 - 257.