

<http://www.ijp.iranpath.org/>

Cystic Hygroma in an Adult Male: A Diagnostic Challenge

Varsha Bhatia, Rahul Taksande, Divyaja Sondankar

1. Dept. of Pathology, Grant Government Medical College and Sir JJ Group of Hospitals, Byculla, Mumbai, Maharashtra, India

KEY WORDS

Cystic Hygroma
Case Report

ABSTRACT

Cystic Hygroma is a well-recognized lesion in paediatric patients but it is very rare in adults. We report here a case of Cervical Cystic Hygroma in a 45 yr old male. The reasons to present this case are 1) Its rarity in adults 2) Unusual age of presentation 3) Simulates various benign and malignant lesions at this site 4) Is a diagnostic challenge and 5) Role of histology for definitive postoperative diagnosis.

ARTICLE INFO

Received 30 April 2014;

Accepted 27 Sep 2014;

©Iran J Pathol. All rights reserved.

Corresponding Information: Dr. Varsha Bhatia, A/201, New Income Tax Colony, Opposite Dindoshi Bus Depot, Goregoan (East), Mumbai-63, Maharashtra, India. Email: drvarshabhatia@gmail.com

Introduction

Cystic Hygromas (lymphangiomas) are soft tissue tumor of disputed pathogenesis originally reported by Redenbacker in 1828 and the name "Cystic Hygroma" was coined by Werner in 1834 (1). There are two histogenic theories: Firstly, cystic hygroma is due to congenital blockage of lymphatic system or secondly it is a true neoplasm (1). It mainly occurs in the head and neck region but can be present at other anatomical locations like thorax, shoulder, abdomen, pharynx and mediastinum. These cysts vary in size from a few millimeter to more than several centimeters in diameter (2, 3). They are classified into septate (multiloculated) or nonseptate (single cavity)

cystic lesions.

Although common in childhood, occurrence in adults is quite uncommon and fewer than 150 reports of adult cervicofacial cystic hygromas have been reported in the literature (4, 5). It presents a diagnostic challenge in adults as compared to children and definitive diagnosis is usually based on post-operative histology (4).

Case Report

A 45-year-old male came to Surgery Department with complaint of swelling on right side of neck since 2 years. Patient was asymptomatic 2 years back after which he noticed a swelling in the neck; which was initially

single and small and had gradually increased. Patient also complained of pain in right ear and difficulty in deglutition. Patient did not give any history of trauma or upper respiratory tract infection. On examination, there was a large swelling in the cervical region on the right side of neck measuring 15x9 cm. The swelling was non-tender, nonfluctuant, brilliantly translucent extending into both anterior and posterior triangle of the neck. The patient underwent a Computed Tomography (CT) scan of neck and thorax (plain + contrast) and ultrasonography (USG) which showed a large non enhancing

hypodense multiloculated thin walled cystic lesion on the right side of the neck extending from submandibular to supraclavicular region involving anterior as well as posterior triangle with mass effect. A preoperative diagnosis of lymphatic malformation suspicious of cystic hygroma was made.

The patient underwent surgical exploration of the right side of neck and excision of the mass was done. The mass was sent for histopathological examination. The surgeons also performed total thyroidectomy as they were suspecting the lesion to be thyroid malignancy or metastasis. We

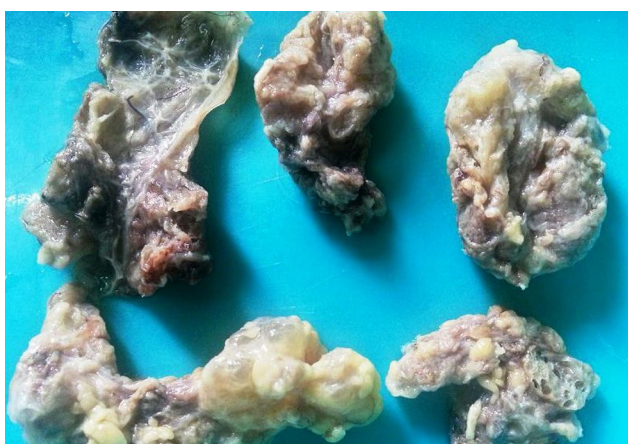


Fig. 1
Gross photograph showing multiple variable size cystic cavities with smooth inner lining

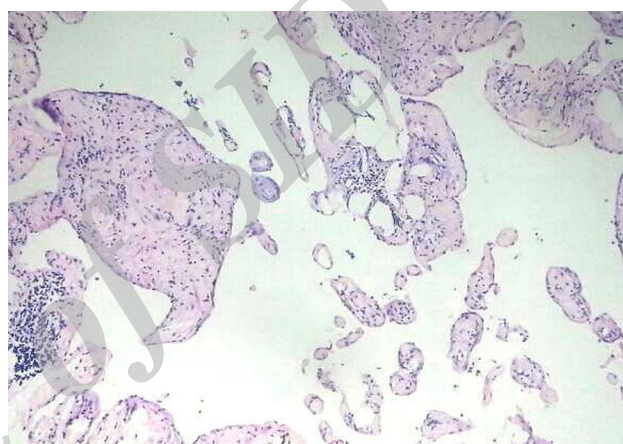


Fig. 2
The microphotograph shows large, irregular dilated lymphatic channels lined by attenuated bland endothelial cells with variable thick collagenous wall and lymphoid aggregates. (H&E, $\times 200$)

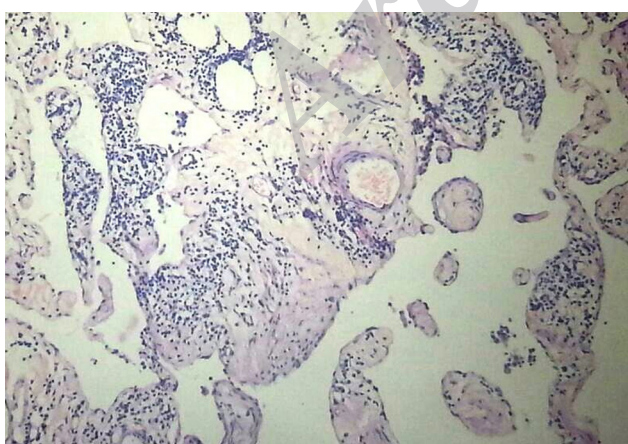


Fig. 3
The microphotograph shows collagenous wall showing lymphoid aggregates. (H&E, $\times 400$)

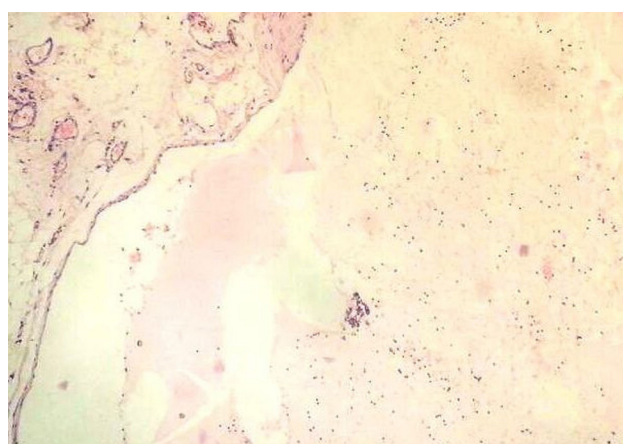


Fig. 4
The microphotograph shows lymphatic channel with eosinophilic coagulum containing lymphocytes. (H&E, $\times 400$)

received five ill-defined tissue masses measuring 8x4x3 cm, 7x5x4 cm, 5x4x2.5cm, 4x3x1.5 cm, 3x1.5x1cm. Externally they were irregular, soft in consistency, gray white and congested. After cutting open, they were large cystic masses with multiple small cysts within i.e. multiloculated and containing serous colourless fluid with smooth inner lining (Fig.1). The wall of the cyst was thin as well as thick without any solid component. We also received total thyroidectomy specimen, which showed normal lobes of thyroid on external and cut surface. Histopathology revealed large, irregular, dilated lymphatic channels lined by a single layer of benign flattened endothelium separated by collagenous stroma (Fig. 2). The stroma showed a dense lymphocytic infiltration with formation of lymphoid follicles (Fig. 3). Few cysts contain eosinophilic coagulum with occasional lymphocytes (Fig. 4). The diagnosis was given as Cystic Hygroma. Histopathology of both lobes of thyroid revealed normal thyroid follicles filled with colloid. There was no evidence of malignancy.

Discussion

Cystic hygroma is a benign congenital malformation of the lymphatic system. Almost 80% to 90% of cystic hygromas present itself before the end of second year of life. It is considered as an uncommon differential diagnosis of a progressively enlarging neck mass in adulthood (6). It can be misdiagnosed with other cystic neck swellings in adults like branchial cleft cyst, dermoid cyst, lipomas, hemangiomas, thyroid mass, tumours and metastatic disease (4, 6). Although after clinical and radiological examination, the above-mentioned diagnosis may look similar to cystic hygroma but histopathology plays a critical role in differentiating it from others.

Gow et al. (4) described in his case report the most common adult presentation as asymptomatic painless swelling with trauma

and upper respiratory tract infection as possible precipitating factors for onset of cystic hygroma. In our case, the patient had asymptomatic painless swelling with no identifiable cause. Kalsotra et al. (7) in their case report described that massive enlargement of hygroma very rarely compresses major structures of neck such as larynx, trachea, oesophagus, branchial plexus and great vessels (4,7) and give rise to clinical symptoms. In our case, it was a large swelling causing mass effect with patient complaining of difficulty in deglutition and pain in the right ear.

Morsley SE (8) proposed in his case report that it is essential to evaluate intrathoracic extension of cystic hygroma, which might be seen in 10% of cases, and this is done by USG/CT/Magnetic Resonant Imaging (MRI) (9). Our patient also underwent CT scan/USG but swelling was restricted to supraclavicular region involving anterior and posterior triangle causing mass effect.

The treatment of choice for cystic hygroma is surgical excision without which there is a danger of infection and fistula formation. Saxena et al. (6) described that cystic hygroma might infiltrate in to adjacent structures which can lead to recurrence in 10-15% of cases, if complete excision is not done.

In addition, total thyroidectomy was carried out on the patient as surgeons suspected this cystic swelling as thyroid mass/metastatic lesion. The gross and histological examination of thyroid was normal with no evidence of malignancy. Thus, this case report emphasizes the utility and the role of histopathological diagnosis of cervical cystic lesions in suspected cases of malignancy on clinical examination.

There are three histological subtypes of cystic hygroma- capillary lymphangioma (composed of small lymphatics), cavernous lymphangioma (Composed of large lymphatics), cystic lymphangioma (cystic hygroma -composed of large lymphatics spaces with collagen and smooth muscle) (10). Our case was of cystic

lymphangioma.

Cystic hygroma is not commonly seen in clinical practice in adult patients. The paucity of literature and atypical presentation pose a diagnostic challenge due to rarity of this lesion. This case was unusual because a large cervical cystic hygroma presented denovo in an adult with no history of trauma or upper respiratory tract infection. Complete excision was done and follow up of the patient was uneventful.

The authors would also like to emphasize the importance of clinical, pathological and radiological correlation for the management of such rare lesions.

Acknowledgements

The authors declare that there is no conflict of interests.

References

1. Thawley SE, Panje WR, Batsake JG, Lindeberg RD. Comprehensive management of head and neck tumours. Saunders:New York;1999.
2. Veeraraghavan G, Denny C, Lingappa A. Cystic Hygroma in an Adult; a case report. Libyan J Med 2009;4(4):160-1.
3. Hamoir M, Plouin-Gaudon I, Rombaux P, Francois

G, Cornu AS, Desuter G et al. Lymphatic malformation of head and neck, a reteroscopic review and a support for staging. Head Neck 2001; 23(4):326-37.

4. Gow L, Gulati R, Khan A, Mihaimed F. Adult onset cystic hygroma: a case report and review of management. Grand rounds 2011;11:5-11.

5. Kraus J, Plzák J, Bruschini R, Renne G, Andrlé J, Ansarin M, et al. Cystic Lymphangioma of the neck in adults: a report of three cases. Wien Klin Wochenschr. 2008;120(7-8):242-5.

6. Saxena P, Chandra D. Cystic Hygroma of neck in an adult female: Case Report & literature review. Int J Surg 2010;22(2).

7. Kalsotra P, Prusty A, Gupta A, Manhas M. Cervical cystic hygroma in an Adult. JK Science 2001;3(4):191-3.

8. Morley SE, Ramesar KC, Macleod DA. Cystic Hygroma in an adult: a case report. J R Coll Surg Edinb 1999;44(1):57-8.

9. Karakas O1, Karakas E, Boyaci FN, Yildizhan M, Demir S, Saglam MA et al. Cervicomedial Giant Cystic Hygroma: A Case Report. J Clin Med Res 2013;5(1):61-3.

10. Guner Ali, Aydin A, Celik F. Cystic Hygromas in Adults: Reports of Two cases. Medical Journal of Bakirkoy 2006;2(3):101-3.

How to cite this article:

Bhatia V, Taksande R, Sondankar D. Cystic Hygroma in an Adult Male: A Diagnostic Challenge. Iran J Pathol. 2015; 10(4): 310 - 313.