

<http://www.ijp.iranpath.org/>

The Adverse Effects of Pregnancies Complicated by Hemoglobin H (HBH) Disease

Maryam Rabiee¹, Jalal-Aldin Shams², Nafiseh Zafargandie¹

1. Dept. of Obstetrics and Gynecology, Faculty of Medicine, Shahed University, Tehran, Iran

2. Dept. of Oncology and Hematology, Faculty of Medicine Shahed University, Tehran, Iran

KEY WORDS

Hemoglobin H
Pregnancy
Iran

ABSTRACT

Hemoglobin (Hb) H disease is a moderate form of α -thalassemia resulting from various genetic defects. HbH disease is not necessarily a benign disorder as has been generally thought. We present hereby a 25-year-old Iranian pregnant woman whom referred to our hospital for blood transfusion. She exhibited the clinical and hematological manifestation of HbH disease. Her father carries a common α -thalassemia deletion while her mother was normal in the hematological profile. The object of this report was to provide information about pregnancies affected by HbH disease.

ARTICLE INFO

Received 11 Jun 2014;

Accepted 27 Sep 2014;

©Iran J Pathol. All rights reserved.

Corresponding Information: Dr. Maryam Rabiee, Dept. of Obstetrics and Gynecology, Faculty Of Medicine, Shahed University, Tehran, Iran.

Tel: 00989121096591 Email: dr_rabi_maryam@yahoo.com

Introduction

Inherited hemoglobin disorders are one of the most common human monogenic diseases. Among them α - and β -thalassemias are two common forms (1, 2).

The four classic α -thalassemias, most common in Asians, are α -thalassemia -2 trait, in which one of the four α -globins' loci deleted, α -thalassemia -1 trait with two deleted loci, HbH disease, with three loci deleted; and hydrops fetal is with Hb bart's with all four loci deleted. Non-deletion form of α -thalassemia also exists. For each syndrome, a close correlation has been established between clinical severity and degree

of synthesis impairment. In HbH disease, HbA production is only 25-30% normally. Impairment fetuses accumulate some un-pairs B-chains; these unpaired B chains accumulate and form B4 tetramers called HbH. Patient with HbH disease have thalassemia intermediate characterized by moderately severe hemolytic anemia but milder ineffective erythropoiesis (1, 3, 4). HbH is highly un-stable, resulting in an increased destruction of circulating red blood cell (2). HbH disease often is caused by the deletion of the three α -goblin genes ($-\alpha$). This group of disorders is sometimes known as deletional HbH disease. In southeast Asia, the deletion of two α -globins' genes, plus the inactivation of the third α -globins'

gene by a non deletional mutation are present in approximately 20% of patients with HbH disease ($--|\alpha Ta$ or $--|\alpha \alpha T$).

The disease is not always benign especially during the neonatal period, in infancy and during pregnancy and it has been associated with hydrops fetalis (1, 5). In addition, anemia can necessitate transfusion and result in age-dependent iron overload (not necessarily related to the transfusions), hepatosplenomegaly and osteopenia (3). Jaundice is uncommon except during hemolytic crisis, and 38% of HbH patients have silent gallstones (4, 6). Since both pregnancy and thalassemia are associated with thrombosis due to a hypercoagulable state, pregnancy women with HbH disease will theoretically be at higher risk for thromboembolism (2). Patients with the non-deleional type of the H disease had more symptoms at a younger age, more severe hemolytic anemia and were more likely to require transfusions than patients with deletional type (6, 7).

Laboratory tests for the diagnosis of HbH disease include CBC, hemoglobin DNA analysis. Patients have low red cell parameters such as HCV, MHC and very wide RDW. Hemoglobin types are A+H (HbH 5%-25%) with small amounts of Hb Bart's (7). The aim of present study was to identify whether HbH disease is

necessarily a benign disorder in pregnancy and does strict control of hemoglobin levels results in better outcome (that need to frequent transfusion).

Case Report

A 25-year-old Iranian pregnant woman was referred to the teaching Mostafa-Khomaynie Hospital, Tehran, Iran for artificial blood transfusion on admission, she looked pale but she had not headache, heart palpitation and vertigo her gestational age was 24 weeks (calculated from last menstruation period). Her fetal heart rate was regular and the fundal height was compatible with gestational age.

Her blood pressure and pulse rate were normal. Her blood smear showed moderate hypo chrome with moderate microcytic anemia.

Mild splenomegaly without hepatomegaly was reported in has sonography. Analysis of his hemoglobin showed HbH band that consisted with HbH disease (Fig. 1).

Informed consent was taken from the patient and all ethical issues were observed.

She was first diagnosed as HbH disease at 6 years age according to moderate anemia (Hb level 8gr/dl) and typical hemoglobin electrophoresis that showed HbH band. Her parents were from northern Iran. Her father

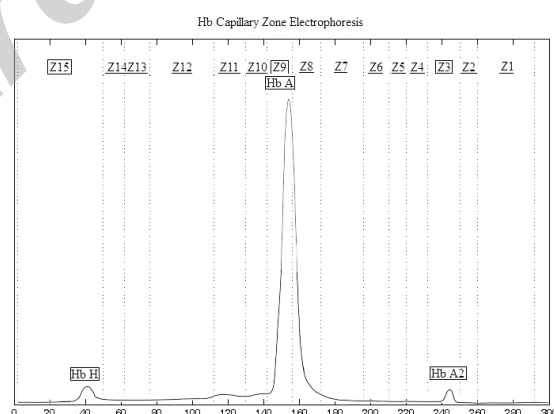


Fig. 1

HB Electrophoresis.

Hb H Fractions : 4.3%, Hb A Fractions : 93.9%, Hb A2 Fractions : 1.8%,

Inclusion test for Hb H is positive, HB A2 references range: 2.5-3.5%

and aunt had α -thalassemic trait but her mother and husband had not anemia and had normal electrophoresis profile. Bone marrow puncture was done once a child that was normal (to rule out aplastic anemia). We injected one unit pack cell according to her hemoglobin level. It was 6.8 gram/dl. Injection was repeated 3 times until the end of pregnancy.

Her pregnancy was uneventful and she had not any complications during pregnancy such as preeclampsia, gestational diabetes. She delivered at 37 weeks of pregnancy. After delivery, her hemoglobin level reached to 6 gram/dl, thus 2 units pack cells were injected to her.

Her fetus was male with a birth weight of 3100 gram and had normal red-cell parameters.

Discussion

HbH disease is not necessarily a benign disorder as has been generally thought and the association of this disease with pregnancy is uncommon (4, 8). The most common complication of HbH disease is anemia (9). The hemoglobin levels of women with HbH disease are typically between 8 and 9 gm/dl but physiologic changes in pregnancy such as expansion of blood volume can aggravate the severity of anemia.

Hb level may sometimes fall to 6 gram/dl or even less necessitating the need for blood transfusion. On the other hand both anemia and pregnancy can place patients at risk for cardiac decompensation (2, 4). In this study, the mean hemoglobin level of our patient was 7.8-8 gram/dl before pregnancy and she needed 5 times blood transfusions to maintain her hemoglobin level higher than 7 gram/dl during pregnancy. In Tongsong et al. study, common obstetric complications such as ante partum hemorrhage, pre-eclampsia and post partum hemorrhage were not significantly associated with HbH disease (2) but Tantiweevawong et al. found that HbH may adversely affect maternal health (10). These serious complications were not occurred

in our patient. In these researches adverse fetal outcome were major problems (3, 4, 6). Chronic maternal anemia can lead to a state of hypoxia itself leading to fetal growth restriction, low birth weight and preterm birth. Our patient delivered at term and her fetus was not small for gestational age. We attempted to keep her hemoglobin level above 7 gr/dl. However, in spite of an attempt to keep hemoglobin levels 7.0 gram/dl, pregnancies with HbH disease were significantly associated with increased risk low birth weight and preterm birth and perinatal mortality (11). In a few studies advised to use of recombinant human erythropoietin (rhEPO) that it is a safer, if less immediately effective, alternative path for the correction of anemia in pregnant patients with hemoglobinopathy (11,12).

This study indicates that in spite of an attempt to keep hemoglobin levels above 7 gr/dl, pregnancies with HbH disease were significantly associated with increased risks of IUGR, small for gestational age, perinatal mortality. On the other hand, in Tongsong et al. study concluded "the benefits of frequent transfusions (the prevention of growth restriction) should be weighed against their drawbacks (antibody development) keeping in mind that it is not known whether a strict control of hemoglobin levels results in better outcome" (2). Another important issue is related to testing the women's partner and genetic counseling (4).

Conclusion

This finding underscores the public health importance of these hereditary disorders and they call for better education, diagnosis, treatment, and research for these disease.

Acknowledgements

The authors declare that there is no conflict of interests.

References

1. Fauci As, Kasper DL, Braunwald E, Longo DL, Hameson JL, Havser SL, et al. Harrison's principles of internal medicine. 17th ed. New York: MC Graw Hill ;2008.
2. Tongsong T, Srisupudit K, Luewan S. Outcome's pregnancies affected by hemoglobin H disease. *Int J Gynecol Obst* 2009; 104(3): 206-9.
3. Chunjaing Z, Wenfang Y, Jiansheng Ling Ch, Hui D, Xuan Sh, Xiangmin X. Hemoglobin H disease due to a denovo mutation at the $\alpha 2$ -globin gene and an inherited common α -thalassemia deletion found in a Chinese boy. *Blood cells Mol Dis* 2010; 45(3): 223-26.
4. Chui DHK, Fuehareon S, Chan V. Hemoglobin H disease: not necessarily a benign disorder. *Blood* 2003; 101(3): 791-800.
5. Chui DH. Alpha-thalassemia: HbH disease and Hb barts hydrops fetalis. *Ann NY Acad Sci* 2005; 1054: 25-32.
6. Chen FE, Ooil C, Hasy S, Cheung BM, Todd D, Liang R, Chan TK, Chan V. Genetic and clinical features of hemoglobin H disease in Chinese patients. *N Engl J Med* 2000;343(8):544-50.
7. Fuchareon S, Virakasit V. HbH disease: clinical course and disease modifiers. *ASH Hematology Education Program* 2009 ; 1(0) :26-34
8. Ong HC, White JC, Sinnathuray TA. Hemoglobin H disease and pregnancy in a Malaysian woman. *Acta Haematol* 1997; 58(4): 229-3
9. A Macciò A, Madeddu C, Chessa P, Mantovani G, Galanello R. Use of erythropoiesis stimulating agents for the treatment of anemia and related fatigue in a pregnant woman with HbH disease. *Br J Haematol* 2009; 146(3): 335–7.
10. Tantiweerawong N, Jaocisidha A, Israngura Na AN. Outcome of pregnancy hemoglobin H disease. *Int J Gynecol obstet* 2005; 90(3): 236-7
11. Trairisilp K, Luewan S, Tongsong T. Pregnancy outcomes in women complicated by thalassemia syndrome at Maharaj Nakorn Chiang Mai Hospital. *Arch Gynecol Obstet* 2009; 279(5):685-9.
12. Krafft A, Breymann C. Haemoglobinopathy in Pregnancy: Diagnosis and Treatment. *Current Med Chem* 2004; 11 (21):2903-09.

How to cite this article:

Rabiee M, Shams J, Zafargandie N. The Adverse Effects of Pregnancies Complicated by Hemoglobin H (HBH) Disease. *Iran J Pathol.* 2015; 10(4): 318 - 321