

<http://www.ijp.iranpath.org/>

Recurrent Ancient Intraosseous Neurilemmoma of Maxilla: A Rare Case Report

Tamgadge Avinash, Tamgadge Sandhya, Shashibhushan Dodal, Mayura Chande, Treville Pereira

Dept. of Oral & Maxillofacial Pathology and Microbiology Dr D Y Patil Dental College & Hospital, Sector 7, Nerul, Navi Mumbai, Maharashtra, India

KEY WORDS

Recurrent
Ancient neurilemmoma
Schwannoma
Neural tumor
Maxilla
Cystic
Intraosseous

ABSTRACT

Neurilemmomas are benign tumors of peripheral nerve sheath Schwann cells. One of the variants of neurilemmoma is the ancient type of neurilemmoma characterized by degenerative features such as cystic degeneration, calcification, hemorrhage and hyalinization which could be easily misdiagnosed. Their occurrence in oral cavity is extremely rare and intraosseous type occurring in maxilla is exceedingly rare with very few cases being published in literature. A 38 year old male patient reported with a chief complaint of swelling over the left cheek and left upper back region since 10 months. The case is of recurrent intraosseous ancient neurilemmoma in the maxilla in the patient which is distinctive for the lesion. This unique case presented with distinct histologic architectural pattern of ancient neurilemmoma showing degenerative changes such as cystic degeneration and recurred within a short duration of time.

ARTICLE INFO

Received 12 Dec 2014;
Accepted 20 Feb 2015;

©Iran J Pathol. All rights reserved.

Corresponding Information: Dr.sandhya tamgadge GRACE –C 802 ,L.B.S MARG ,VASANT OSCAR ,MULUND WEST ,MUMBAI ,MAHARASHTRA 400080 Email: Sandhya.tamgadge@gmail.com Tel: + 919222199770

COPYRIGHT © 2016, IRANIAN JOURNAL OF PATHOLOGY. This is an open-access article distributed under the terms of the Creative Commons Attribution-noncommercial 4.0 International License which permits copy and redistribute the material just in noncommercial usages, provided the original work is properly cited.

Introduction

Neurilemmomas (Schwannomas or Neurinoma) are rare benign nerve tissue tumors arising from the neural sheath Schwann cells of the peripheral, cranial or autonomic nerves (1). The origin of these tumors is generally linked to nerve trunk and usually affects the entire course of the nerve. The type of nerve affected decides the clinical symptoms (2). Their etiology is unknown but schwann cell proliferation within the perineurium leads to displacement and compression of the surrounding normal nerve tissue (3).

Neurilemmomas have a predilection for head and neck region and account for approximately 40% of all neurilemmomas. However, only 1% affects oral cavity, tongue being the most common site (4) but intraosseous neurilemmomas of the jaws are rare (5). Amongst all intraoral neurilemmomas, ancient variant is exceedingly rare and till today only limited cases have been reported. This article reports an additional case of intraosseous ancient neurilemmomas in the maxilla along with review of literature.

Case report

A 38 year old male patient reported with a

chief complaint of swelling over the left cheek and left upper back region since 10 months. On clinical examination, the swelling was seen over the left maxillary area below the infraorbital region extending from the ala of the nose to malar process antero-posteriorly and from infra orbital margin to 1 cm above the corner of mouth superior-inferiorly. It was soft, fluctuant and 3x2.5x0.5 cm in dimension (Fig 1A, B).

On intraoral examination the swelling was seen over the alveolar mucosa measuring 1x1 cm. Buccal cortical expansion was also seen which extended from left maxillary canine to third molar region and the overlying mucosa

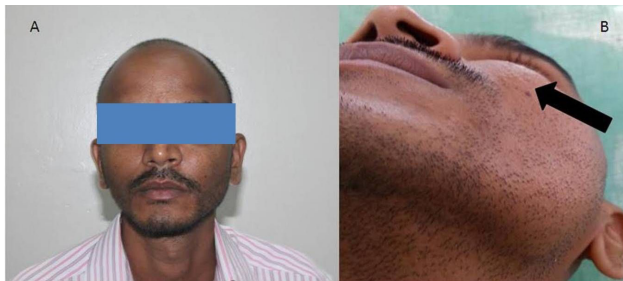

Fig. 1
Patient showing extraoral swelling over the left maxillary area below the infraorbital region

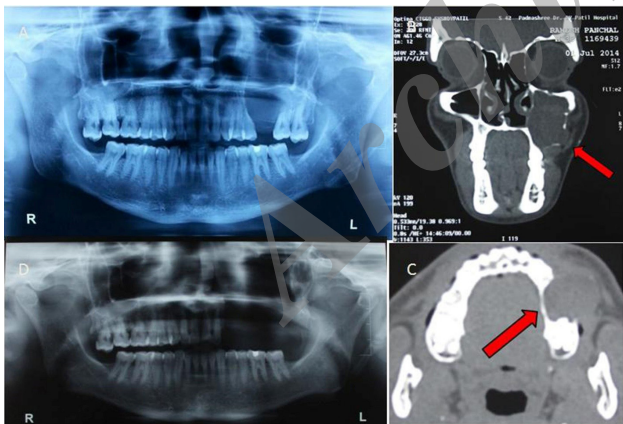


Fig. 3
A: Orthopantomograph revealed osteolytic area with partly well-defined corticated margin extending from premolar to molar area and the floor of maxillary sinus appeared discontinuous. B, C: Superior axial section of computed tomography showed large isodense expansile lesion extending from the canine to the third molar area. Perforation of buccal cortical plate and medial wall of maxillary sinus was seen. D: Post-operative Orthopantomograph showing the satisfactory healing

was normal (Fig 2A, B). The swelling was not associated with pain, discharge or paresthesia. Informed consent was taken from the patient.

The Patient gave history of extraction of carious maxillary left first molar associated with

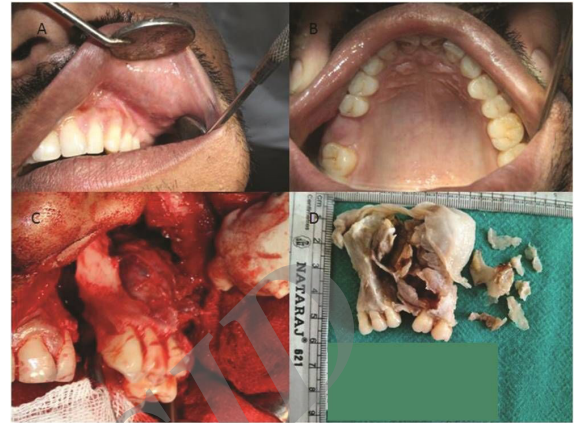

Fig. 2
A,B: Intraoral examination showing swelling over the alveolar mucosa. Buccal cortical expansion was seen extending from left maxillary canine to third molar region. C: Surgical excision of the lesion. D: Excisional biopsy specimen

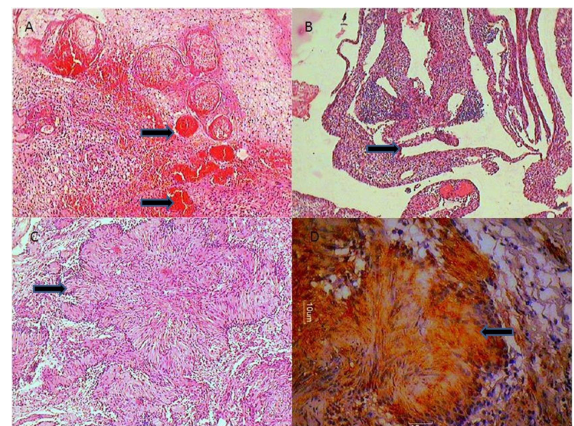


Fig. 4
A: Hematoxylin & Eosin stained image of first excisional biopsy showed numerous engorged blood vessels (arrows) in oedematous cellular stroma devoid of distinct neural tissue. (x 10) B: Hematoxylin & Eosin stained image showing cystic spaces in some areas could be appreciated indicating cystic degeneration (x4). C: Hematoxylin & Eosin stained image showing a palisaded arrangement of cells encircling eosinophilic structures (suggestive of Verocay bodies) the Antoni A type (arrow); and the other pattern was an irregularly arranged configuration of spindle cells, sometimes in a loosely organized myxoid background resembling Antoni B type (x10). D: Immunohistochemical staining showing positivity for S-100 (x 40)

intra oral and extra oral swelling one year back. However, the swelling gradually increased post extraction. An excisional biopsy was performed and a diagnosis of chronic nonspecific infection was established as it showed numerous blood vessels and oedematous cellular stroma along with inflammatory cells the medical and family history was non-contributory.

Orthopantomograph revealed osteolytic area with partly well-defined corticated margin extending from premolar to molar area and the floor of maxillary sinus appeared discontinuous (Fig 3A).

Superior axial section of computed tomography showed bony window at the level of maxillary sinus. Large isodense expansile lesion could be appreciated extending from the canine to the third molar area. Anterolateral and medial wall expansion showed perforation with medial wall showing isodense mass extending into the nasal cavity. Axial inferior section showed soft tissue window at the level of maxilla. Perforation of buccal cortical plate and medial wall of maxillary sinus was seen (Fig 3B, C).

With the above clinical and radiographic features, a differential diagnosis of benign neoplastic lesions of maxilla such as keratocystic odontogenic tumor (due to recurrence), ameloblastoma or central giant cell granuloma was established.

The recurrent lesion was totally excised under general anaesthesia (Fig 2C). Post-operative healing was satisfactory (Fig 3D).

Grossly, the excised specimen was cystic in nature resembling a cystic lining (Fig 2D). Different areas from the tissue were selected for tissue processing. On histopathological examination only one bit showed classic features of neurilemmoma composed of spindle shaped cells with oval or blunt elongated nuclei resembling Schwann cells. These cells were arranged in two patterns. One pattern was a palisaded arrangement of cells encircling eosinophilic structures (suggestive of Verocay

bodies) i.e. the Antoni A type; and the other was an irregularly arranged configuration of spindle cells, sometimes in a loosely organized myxoid background resembling Antoni B type (Fig 4 C). Cystic spaces in some areas could be appreciated indicating cystic degeneration usually found in ancient variant of neurilemmoma (Fig 4 B). Immunohistochemistry was done using S-100 marker that showed diffuse positivity for tumor cells which further potentiated the diagnosis of neurilemmoma (Fig 4 D). Thus with the above findings a histopathological diagnosis of ancient neurilemmoma was made.

Discussion

Neurilemmoma was first described by Jose JaunVerocay, a Uruguayan physician, in 1910 and called it Neurinoma. However, in 1935, A.P. Stout coined the term Neurilemmoma (6, 7). It is a benign tumor of schwann cells characterised by solitary, slow growing, encapsulated nodular lesion seen anywhere in the body. Approximately 25%-45% of all schwannomas are seen in head and neck region with intraoral neurilemmoma being rare (approximately 1%). Intraorally, it occurs with greater to lesser frequency in the mobile portion of tongue, floor of the mouth, palate, gingival, vestibule, lips, salivary glands and mental nerve region (1, 2, 4). It is seen in all age groups, 3rd and 4th decade being the most common. In the present case, the patient is in 3rd decade of life which coincides with the literature.

Clinically, intraoral and intraosseous neurilemmomas show nonspecific symptoms and are difficult to distinguish from other odontogenic lesions such odontogenic keratocyst, ameloblastomas and other benign tumours especially when it shows cystic degeneration clearly appreciated in grossing as well as on histopathological examination (1, 8). Arriving at a preoperative diagnosis is often difficult and imaging studies such as computed tomography and magnetic resonance imaging aid in the

differential diagnosis of the lesions.

The present case was earlier diagnosed as chronic nonspecific infection because the biopsy specimen did not show any cystic feature on macroscopic examination. Additionally, on microscopic examination, the tissue showed numerous engorged blood vessels in oedematous cellular stroma devoid of distinct neural tissue (Fig 4A). Hence the diagnosis of neurilemmoma was missed out. For the second excisional biopsy, a differential diagnosis of keratocystic odontogenic tumor was made considering the recurrent nature of the lesion and cystic nature.

Histopathologically only one bit of lesional tissue showed distinct features of neurilemmoma potentiating the fact that all the lesional tissue must be scanned before arriving at any diagnosis.

Neurilemmomas are tumors grossly presenting as a gelatinous or cystic mass which may be encapsulated or unencapsulated with occasional secondary degenerative changes such as cystic degeneration, hyalinized vessels and necrosis (9). Histopathologically neurilemmomas are quite distinct. Microscopically, neurilemmoma shows a typical biphasic pattern of cellular Antoni A and paucicellular Antoni B areas; Antoni A pattern consists of fascicles of palisaded bipolar Schwann cells streaming around acellular eosinophilic areas. The nuclei of these cells are usually oval or blunt and elongated. The acellular zones assuming organoid shape are called Verocay bodies. The Antoni B pattern is less cellular, with loosely organized cells in a myxoid stroma. Vascularity is seen in most of the schwannomas (1, 9). All these features could be appreciated in the present case.

Schwannomas are classified into five types: common type, plexiform, cellular, epithelioid and ancient (9). Our case is of ancient type.

Ackerman and Taylor were the first to describe the ancient variant of neurilemmoma (10). The oral ancient schwannoma was first reported by Eversoll and Howell in 1971 (11).

Only 16 cases have been reported till today

(12-14). Of these, only four cases of intraosseous ancient neurilemmoma have been reported in literature, three in mandible and one in maxilla. This case may be the fifth case of intraosseous ancient neurilemmoma occurring in jaws and second case occurring in maxilla. Cases reported in literature are by Salehinezhad J et al., in a 23 yr old female in mandible, GholamrezaJahanshahi et al., in 11 yr old female occurring in mandible, Kim et al., in 35 yr old female in mandible, and Gainza et al., in hard palate of maxilla in 35 yr old female (12-14).

The ancient variant presents with clear areas of hypocellular tissues and the changes seen are attributed to the long standing degenerative changes. These characteristic degenerative changes are cystic degeneration, calcification, hemorrhage, hyalinization and macrophages and hemosiderin deposition. Nuclear atypia may be a prominent feature but there is absence of mitotic activity (15). The present case also showed numerous cystic spaces indicating cystic degeneration also previously reported (12). The first biopsy also showed numerous hemorrhagic spaces observed earlier (12, 13).

Neurilemmomas show strong positivity with S-100 (97%), Leu-7 (57%) and myelin basic protein (MBP) (44%) thus confirming their neural origin. However, it shows negativity to neurofilament (NF) because of absence of neurites, thus facilitating the distinction from neurofibroma where nerve fibers are a part of the tumor (11). CD 56 and calretinin are usually positive in neurilemmomas, while CD 34 and Factor XIIIa are positive in neurofibromas. These markers can be used for doubtful cases. Immunohistochemistry with S-100 protein showed strong diffuse positivity for the present case. S-100 positivity has been mentioned earlier (1, 9, 10).

Conclusion

Intraosseous Ancient Schwannomas of the

jaws are exceedingly rare and pose diagnostic difficulties, often mistaken for malignancy. In cystic variant of ancient schwannoma the characteristic features of neurilemmoma could be observed in some areas of the tissue. Therefore thorough scanning of the entire specimen is mandatory to arrive at the correct diagnosis and in some cases immunohistochemical analysis is needed for confirmation. The therapeutical conduct is complete surgical excision and the prognosis is excellent. Malignant transformation of intraoral ancient neurilemmoma is rare.

Acknowledgements

There is no Financial Disclosure.

Conflict of interest

None of the authors have any conflict of interest to disclose.

References

- Martins MD, Anunciato de Jesus L, Fernandes KP, Bussadori SK, Taghloubi SA, Martins MA. Intra oral schwannoma: case report and literature review. *Indian J Dent Res* 2009;20(1):121-5.
- Yang SW, Lin CY. Schwannoma of the upper lip: case report and literature review. *Am J Otolaryngol* 2003;24(5):351-4.
- Hatziotis JC, Asprides H. Neurilemmoma (schwannoma) of the oral cavity. *Oral Surg* 1967;24(4):510-26.
- Grabowski L. A rare case of schwannoma of the tongue. *Otolaryngol Pol* 2008;62(2):191-4.
- Marx RE, Stern D. Oral and maxillofacial pathology: A Rationale For Treatment. 1st ed. Carol Stream: Quintessence Publishing; 2008.
- Baranović M, Macan D, Begović EA, Luksic I, Brajdić D, Manojlović S. Schwannoma with Secondary erosion of mandible: Case report with review of literature. *Dentomaxillofac Radiol* 2006;35(6):456-60.
- Chrysomali E, Papanicolaou SI, Dekker NP, Regezi JA. Benign Neural tumors of the oral cavity. *Oral Surg Oral Med Oral Path Oral Radiol Endod* 1997;84(4):381-90.
- Gallego L, Junquera L, Rodríguez-Recio C, Fresno MF. Intraosseous mandibular schwannoma mimicking an odontogenic keratocyst, with a postsurgical pathological fracture. *J Laryngol Otol* 2009;123(5):560-2.
- Weiss SW, Goldblum JR. Enzinger and Weiss's Soft Tissue Tumors. 5th ed. Philadelphia: Mosby; 2008.
- Ackermann LV, Taylor FH. Neurogenous tumors within the thorax. A clinicopathological evaluation of 48 cases. *Cancer* 1951; 4(4): 669-91.
- Chen CY, Wang WC, Chen CH, Chen YK, Lin LM. Ancient schwannoma of the floor of the mouth – A case report and review. *Oral Oncol Extra* 2006;42(8):281-5.
- Muruganandhan J, Srinivasa Prasad T, Selvakumar T, Nalin Kumar S. Ancient neurilemmoma: A rare oral tumor. *J Oral Maxillofac Pathol* 2013;17(3):447-50.
- Kim NR, Chung DH, Park DS, Kim DW et al. Ancient schwannoma of oral cavity: a report of two cases. *J Korean Assoc Oral Maxillofac Surg* 2011;37(6):530-4.
- Gainza Cirauqui ML, Eguia Del Valle A, Martinez Conde R, Coca Meneses JC, Aguirre Urizar JM. Ancient schwannoma of the hard palate. An uncommon case report and review. *J Clin Exp Dent* 2013;5(1):62-5.
- Chi AC, Carey J, Muller S. Intraosseous schwannoma of the mandible: a case report and review of the literature. *Oral Surg Oral Med Oral Pathol Oral Radiol Endod* 2003; 96(1): 54-65.

How to cite this article:

Avinash T, Sandhya T, Dodal S, Chande M, Pereira T. Recurrent Ancient Intraosseous Neurilemmoma of Maxilla: A Rare Case Report. *Iran J Pathol*. 2016;11(2):176-80.