

The Prevalence of Tongue Abnormalities Among the School Children in Borazjan, Iran

F. Khozeimeh DDS, MSc*, G. Rasti DDS**

ABSTRACT

Introduction: Tongue is one of the most important organs in the oral cavity which has significant roles in different functions such as speaking, mastication, swallowing, breathing, etc. The tongue may be influenced by internal diseases sooner than other organs and also may be involved in some abnormalities that some are developmental and some of them are genetical and environmental. This study has been performed to measure the relative frequency of tongue anomalies in students in Borazjan city and to determine the relations of age and gender with these anomalies.

Methods and Materials: With randomized stratified clustered sampling, 1540 students were selected from primary, guidance and high school. Then these students were examined. Examination was performed with the natural light in the quiet and relax condition. Lips and cheeks were retracted with abslang and disposable mirror. The results were analysed with chi-square statistic test in SPSS.

Results: The prevalence of all tongue anomalies was 34.3% (geographic tongue 4.8%, fissured tongue 11.8%, ankyloglossia 5%, median rhomboid glossitis 1.75%, and hairy tongue 0.8%).

Discussion: The prevalence of tongue anomalies in this study is near to the results of some past studies but is different with some others. This study showed that tongue anomalies are more prevalent in males than in females but the difference between them was not statistically significant. This study also showed that the rate of tongue anomalies was not related with age.

Key words: Geographic Tongue, Fissured Tongue, Ankyloglossia, Median Rhomboid Glossitis, Hairy tongue.

[Dental Research Journal (Vol. 3, No.1, Spring - Summer 2006)]

Introduction

Many conditions are included under the term "tongue anomalies"; some of them are of minor clinical significance that often occur enough to be considered as normal variants; some are major significant deformities of the tongue that, in many cases, help to define a number of inherited syndromes, and a group of miscellaneous conditions that show evidences of developmental etiology.^{1,2}

Local and systemic disorders affect the tongue and provide some understanding of the distress that usually accompanies limitation of

function of this organ. The purpose of the present study was to evaluate the prevalence of the more common morphologic and functional anomalies of the tongue (geographic tongue, fissured tongue, ankyloglossia, median rhomboid glossitis and hairy tongue) in students in Borazjan city, in October 2003.

Geographic tongue (benign migratory glossitis)

Refers to irregularly shaped, reddish areas of depapillation and thinning of the dorsal tongue epithelium that are usually surrounded by a narrow zone of regenerating papillae that is

*Assistant Professor, Department of Oral Medicine; School of Dentistry, Isfahan University of Medical sciences, Isfahan, Iran.

** Dentist.

whiter than the surrounding tongue surface. Spontaneous development and regeneration of

affected areas account for the terms "wandering

rash", "benign migratory glossitis", and "geographic tongue"¹.

Fissured, Plicated, or Scrotal Tongue^{3, 4, 5}

Fissured tongue occurs as a normal variant affecting less than 10% of the population twin studies suggest that it is probably genetically determined⁶; although the frequency of individuals with well-marked fissuring increases with age⁷, as does the number, width, and depth of the fissures in affected individuals. The frequency of fissured tongue is four to five times greater in institutionalized, mentally retarded children; a fact that at least can be partly explained by the frequency of fissured tongue in trisomy 21 (mongolism)⁸.

Ankyloglossia (tongue tie)

Partial ankyloglossia refers to congenital shortness of the lingual frenum or a frenal attachment that extends nearly to the tip of the tongue, binding the tongue to the floor of the mouth and restricting its extension⁹.

Severe degrees of ankyloglossia often cause a midline mandibular diastema, lingual mandibular periodontal defects, and speech impairment^{9, 10}.

Median Rhomboid Glossitis (central papillary atrophy)

It is a rounded or roughly lozenge – shaped, raised area that occurs in the midline of the tongue dorsum just anterior to the vallate papillae. The affected area is devoid of filiform or other papillae. In recent years, considerable debate has been centered around the role of chronic candidiasis in median rhomboid glossitis^{11, 12, 13}.

Hairy Tongue

The heavily keratinized surface layers of the filiform papillae are continuously desquamated through friction of the tongue with food, the palate, and the upper anterior teeth and are replaced by new epithelial cells from below. When tongue movements are limited by illness or painful oral condition, the filiform papillae lengthen and become heavily coated with bacteria and

fungi. The longer papillae give the tongue a coated or hairy appearance and retain debris and

pigments from substances such as food, tobacco smoke, and candy. These changes primarily affect the middorsum of the tongue which often becomes discolored in a startling way¹.

Methods and Materials

1540 students in the age range of 7-17 years old were selected by randomized stratified clustered sampling from primary, guidance and high schools. The study population were divided into 11 age groups and in each group 140 students (70 girls and 70 boys) were examined. Examination was performed with the natural light in the quiet and relax condition. Lips and cheeks were retracted with abslang and disposable mirror. The results were analysed with chi-square statistic test in SPSS.

Results

The total prevalence of tongue anomalies in 1540 subjects (770 boys and 770 girls) was 24.3%. In our study population, tongue anomalies were more prevalent among boys (24.7%) than girls (23.9%), though the difference was not significant ($P=0.72$) (table 1).

Among tongue lesions, geographic tongue was observed in 4.8% of our subjects and was more prevalent in girls but there wasn't a significant difference.

Fissured tongue was observed in 11/8 % of our subjects and was equally prevalent in boys and girls.

Partial ankyloglossia was observed in 5% of our population and was more prevalent in boys than girls but there wasn't a significant difference ($P>0.05$).

Median rhomboid glossitis was found only in 1.75% of the subjects.

Hairy tongue was observed in 0.8% of our subjects and was equally prevalent in boys and girls.

The prevalence of tongue anomalies was 23.45% in primary school (7-11 years old) (figure 1), 22.1 in guidance school (12-14 years old) (figure 2), and 29% in high school (15-17 years old) (figure 3).

There wasn't a significant difference between tongue anomalies and age group ($P>0.05$).

Table 1. Prevalence of tongue anomalies according to gender.

Anomalies \ Gender	Boy N (%)	Girl N (%)
geographic tongue	33 (7.9)	43 (5.5)
fissured tongue	91 (11.8)	91 (11.8)
partial ankyloglossia	45 (5.8)	34 (4.4)
median rhomboid glossitis	16 (2.1)	11 (1.4)
Hairy tongue	6 (0.8)	6 (0.8)
Total	191 (24.7)	185 (23.9)

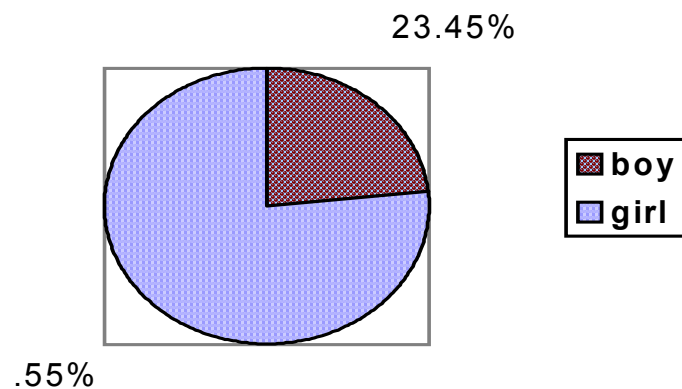


Figure 1. Average frequency of tongue anomalies in 7-11 years old children.

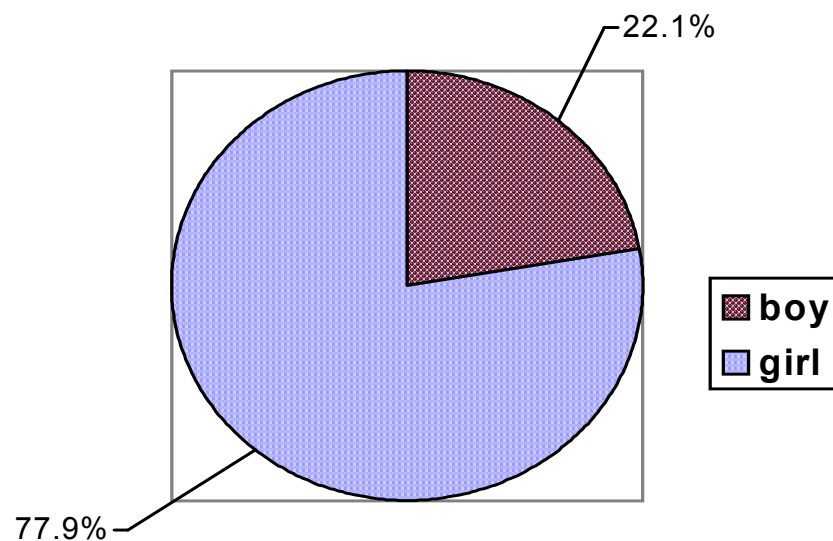


Figure 2. Average frequency of tongue anomalies in 12-14 years old children.

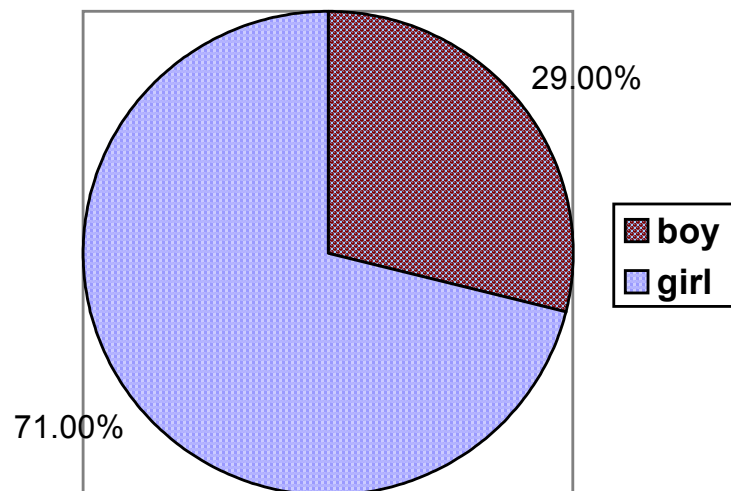


Figure 3. Average frequency of tongue anomalies in 15-17 years old children.

Discussion

The prevalence of geographic tongue in our population was 4.8% which had an increase with age rise which is near to the finding of Voros et al study (5.7%), among 1-14 years old Hungarian children in 2003¹⁴.

There are significant differences between our results and the findings of salem et al study (0.2%) among 6-12 years old Saudi Arabian school children in 1932¹⁵, and Rabii study (11%) among 7-11 years old school children in lahijan, Iran in 2002¹⁶. The etiology of geographic tongue remains obscure and the existence of similar lesions in association with other dermatoses only confuses the issue. An immunologic reaction has been proposed, based on the associated inflammatory infiltrate^{17, 18}. The same infiltrate is said to justify an allergic etiology^{19, 20}. No particular inheritance pattern has been established²¹.

Fissured tongue was observed in 11.8% of our subjects which is near to the findings of Rabii study (13.4%), but it is significantly less than what was found among the Mexican children aged 5-14.5 years old (15.7%) in Sedano study in 1989²², and among Slovenian population (21.1%) in Kavac kovacic study in 1999²³, and among Hungarian children (29.2%) in Voros et al study¹⁴. The increase in prevalence and degree of tongue fissuring with age rise may be

due to some factors such as salivary hypofunction, possibly vitamin B deficiency, candidiasis, and chronic (plaque like) lichenoid lesions^{7, 24, 25}.

Partial ankyloglossia was observed in 5% of our population which is near to the findings of Rabii study in lahijan (6.7%), but is significantly more than the findings of Voros et al study among Hungarian children (0.88%), and Salem et al study among Saudi Arabian school children (0.1%)¹⁵. A chromosomal locus has been indentified for some familially expressed examples of ankyloglossia but it is unlikely that the same locus is involved in all cases²⁶.

The prevalence of median rhomboid glossitis in our population was 1.75% which is near to what was found among American population, published in Barket's oral medicine in 2003 (2-3%)¹⁹, but it is significantly higher than what was found by Rabii (0.4%)¹⁶.

Hairy tongue was observed in 0.8% of our subjects and this prevalence is near to the prevalence of hairy tongue, published in Barket's oral medicine in 2003 (0.5%)⁽¹⁹⁾.

While prevalence rates of these more common morphologic abnormalities have been documented by many investigators, the published data vary considerably, Probably due as much to the use of different diagnostic criteria for a given abnormality as to natural variation whitin different racial groups and ages.

References

- 1- Lynch MA, Bright man VJ, Greenberg MS. *Burket's Oral Medicine*. 9th ed .Philadelphia: Lippincott-Raven; 1994. p.241-60.
- 2- Brouillette RT, Thach BT. Control of genioglossus muscle inspiratory activity. *J Appl Physiol* 1980;49(5):801.
- 3- Redman RS. Prevalence of geographic tongue, fissured tongue, median rhomboid glossitis, and hairy tongue among 3,611 Minnesota schoolchildren *Oral Surg Oral Med Oral Pathol* 1970;30(3):390-5.
- 4- Chosak A, Zadik D, Eidelman E. The prevalence of scrotal tongue and geographic tongue in 70,359 israeli school children. *Community Dent Oral Epidemiol* 1974;2(5):253-7
- 5- WITKOP CJ Jr, BARROS L. Oral and genetic studies of Chileans, 1960. I. Oral anomalies. *Am J Phys Anthropol* 1963;21:15-24
- 6- Tobias N. scrotal tongue and its inheritance. *Arch Dermatol syph*. 1945;52:266.
- 7- Glenert U, Pindborg JJ , Andreasen Jo. Tongue surface conditions of 478 residents of a large Danish rest Home. *Gerodontics* 1986;2(3): 82-6.
- 8- Cohen MM Sr, Cohen MM Jr, the oral manifestations of trisomy G-1 (Down syndrome). *Birth Defects Orig Artic Ser* 1971;7(7):241-51.
- 9- Young EC, Sacks GK. Examining for tongue tie. *Clin Pediatr (Phila)*. 1979;18(5):298.
- 10- Ewart NP. A lingual mucogingival problem associated with Ankyloglossia: a case report. *N Z Dent J* 1990;86(383):16-7.
- 11- Holmstrup P, Axell T. Classification and clinical manifestations of oral yeast infections. *Acta Odontol scand* 1990;48(1):57-9.
- 12- Walker DM, Arendorf T. Candidal leukoplakia, chronic multifocal candidiasis and median rhomboid glossitis. Samaranyake LP, Macfarlane TW (eds): in *Oral candidiasis*. Bristol: Wright; 1990. p.184-99.
- 13- van der Wal N, van der Waal I. Candida albicans in median rhomboid glossitis. A post mortem study . *Int J Oral Maxillofac Surg*. 1986;15(3):322-5.
- 14- Voros-Balog T, Vincze N, Banoczy J. Prevalence of tongue lesions in Hungarian children. *Oral Dis*. 2003;9(2):84-7.
- 15- Salem G, Holm SA, Fattah R, Basset S, Nasser C. Developmental oral anomalies among schoolchildren in Gizan region, Saudi Arabia. *Community Dent Oral Epidemiol*. 1987;15(3):150-1.
- 16- Rabii. M , MoHtasham. Z , Masoudi Rad . H , Niazy . M, the prevalence of tongue abnormalities among primary school children in Lahijan . *Dent . J of Gilan university of Medical sciences* 2003 Apr 45-49. [Farsi]
- 17- Dawson TA. Microscopic appearance of geographic tongue. *Br J Dermatol*. 1969;81(11):827-8.
- 18- Banoczy J, Szabol , Csiba A. Migratory glossitis; A Clinical-histologic review of seventy cases. *Oral Surg Oral Med Oral Pathol*. 1975;39(1):113-21.
- 19- Marks R, Simons MJ. Geographic tongue--a manifestation of atopy. *Br J Dermatol* 1979;101(2):159-62.
- 20- Jarvinen J, Kullaa-Mikkonen A, Kotilainen R. Some local and systemic factors related to tongue inflammation. *Proc Finn Dent Soc* 1989;85(3):199-209.
- 21- Redman RS, Shapiro BL, Gorlin RJ. Hereditary component in the etiology of benign migratory glossitis. *Am J Hum Genet* 1972;24(2):124-33.
- 22- Sedano HO, Carreon Freyre I, Garza de la Garza ML, Gomar Franco CM, Grimaldo Hernandez C, Hernandez Montoya ME, et al. Clinical orodental abnormalities in Mexican children. *Oral surg Oral med oral pathol* 1989;68(3):300-11.
- 23- Kovac-Kovacic M, Skaleric U. The prevalence of oral mucosal lesions in a population in slovenia. *J oral pathol med*. 2000;29(7):331-5.
- 24- Bertran U. Xerostomia: studies on salivary secretion. *Acta Odontol Scand*. 1967;25:13.
- 25- Kullaa-Mikkonen A, Jarvinen J. Effects of age, sex and salivary secretion on the human tongue surface. *Gerodontics*. 1988;4(3):150-3
- 26- Bjornsson A, Arnason A, Tippet P. X-Linked cleft palate and ankyloglossia in an Icelandic family. *Cleft Palate J* 1989;26(1):3-8
- 27- *Burket's Oral Medicine. Diagnosis and Treatment*, 10th ed. Martin S Greenberg, Michael Glick (eds), Philadelphia: BC Decker Inc; 2003. p.116,117,135.

