

Original Article

Relative Frequency of Sinusitis Features in Waters' Radiographs of Under 12 Years Old Children Referring to Isfahan City Clinics

M. Sheikhi DDS, MSc*, M. Dehghani DDS**, J. Faghihinia MD MSc***

ABSTRACT

Introduction: The maxillary sinuses are the first sinuses form in the embryonic period and begin to be pneumatized from 4 th year of life. Sinusitis is a common disease in children and its on-time diagnosis and treatment is very important to prevent relevant side effects. Unfortunately, in some medical centers Waters' radiography is routinely prescribed for the diagnosis of sinusitis, regardless of the trend of sinuses evolution in children. The aim of this study was to evaluate the efficacy of Waters' radiography in diagnosis of children's sinusitis.

Methods and Materials: This study was an observational, cross-sectional, and retrospective study. The samples included 180 of 0-12 years old children with sinusitis who had referred to Isfahan city clinics and the physicians had prescribed Waters' radiography for them. Required information was gathered via examination and enquiry into the patients' records. The radiographs were blindly surveyed by two radiologists (an oral and a general radiologist) and the data were statistically analyzed using the Chi-square and Kruskal – Wallis statistical tests.

Results: The coefficient of agreement between clinical signs and Waters' radiographic features in the samples was 52%. The greatest frequency rate of non – pneumatized sinuses was reported in the group of 3-years-olds and under. 30% of the maxillary sinuses were found to be normal in radiography ($P=0.0005$). No difference was observed between sinusitis radiographic results, based on the time of involvement ($P=0.219$) and sex ($P=0.546$). Cough (%89.4) and nasal purulent excretions (%53.2) were the most common clinical symptoms of sinusitis. However, clinical signs in 2 groups of with positive radiographic results and with normal sinuses showed no statistically significant difference ($0.11 < P < 0.83$).

Discussion: Waters' radiography is recommended not to be routinely used for children for some reasons such as non - pneumatization of sinuses, especially in the group of 3- years-olds and under; non - observation of sinuses; and a high percent of normal radiographic findings in Waters' radiographs, in spite of the existence of sinusitis clinical signs, except for special cases.

Key words: Sinusitis, Waters' Radiography, Radiographic Features.

[Dental Research Journal (Vol. 3, No. 2, Autumn-Winter 2006)]

Introduction

Sinusitis is growing as an important and prevalent cause of mortality at all ages. Lots of improvements have been made in diagnosis of this disease. There are however many questions regarding the epidemiology,

pathogenesis, diagnosis and appropriate treatment of this disease. Children's acute sinusitis contains about 5-10% of viral higher respiratory infections and about 3-6% of children suffer from sinusitis within their first three years of life. Chronic sinusitis has

*Assistant professor, Department of Dental Radiology, Isfahan University of Medical Sciences, Isfahan, Iran.

**Dentist

***Assistant professor, Department of Pediatrics, Amin Hospital, Isfahan, Iran.

been known as the most prevalent chronic disease in the youth and the third prevalent disease in the adults in the United States. The prevalence of sinusitis in children under 10 years of old is 70%¹.

At birth, maxillary sinuses are so full of fluid that it's impossible to interpret their simple radiographs. The maxillary sinuses grow rapidly up to 3rd year of life, and will further continue to grow at a slower pace up to age 7. From 7 to 12 years of old, the sinuses grow along with the growth of permanent teeth and get pneumatized^{3,2}.

Both ethmoidal and maxillary sinuses exist at the time of birth. The ethmoidal sinuses get pneumatized earlier, but the maxillary sinuses do not get pneumatized until 4th, the sphenoidal sinus until 5th, and the frontal sinus until 7-8th year of life⁴.

Regarding the high prevalence of sinusitis in children and the need for the prescription of radiography as a diagnostic aid for proper diagnosis and , on the other hand , the non- evolution of sinuses in childhood, the above mentioned radiography seems to lack the efficacy required for the diagnosis of sinusitis. This research is thus conducted as an introduction to the assessment of routine radiography efficacy.

Methods and Materials

This is a descriptive, analytical, retrospective, directionless, and observational study.

We randomly referred to Isfahan city clinics and studied the children under 12 years old who were clinically diagnosed to have developed sinusitis and for whom Waters' radiography had been prescribed.

Patients, who had undergone Waters' radiography because of trauma and those, whose Waters' radiographs had not the quality required for interpretation, were excluded from the study. In the other ones, radiographic signs, clinical signs, age, sex, and involvement time were studied.

The results of Waters' radiography included:

1. the existence of fluid –air level,
2. mucosal thickening,

3. sinus opacity,
4. non- pneumatization of sinuses, and
5. sinuses normal state.

The patients' sinuses involvement time were classified in terms of the states of being acute, sub-acute, and chronic. After the pedologist had completed relevant form in the clinic, the radiographs were collected and blindly interpreted by the oral or general radiologist. The resultant data were collected and the relative frequencies of the individual variables and the relation between them were analyzed, using the SPSS 10 statistical soft ware and Chi- square and Kruskal – Wallis tests.

Results

In 52.2 % of the patients, radiographic signs were positive; 30% of them had normal sinuses; and in 17.8% maxillary sinuses had not gotten pneumatized (table 1).

Diagram 1 shows age and frequency of radiographic signs in patients. According to Kruskal–Wallis test, there was significant difference between different age groups (P=0.0005).

Table1. Distribution of patients according to radiographic features

Frequency Radiograph's features	Absolute frequency	Frequency percent
Air-fluid level	0	0
Mucosal thickening	44	24.4
Opacity	50	27.7
Non pneumatization	32	17.8
Normal	54	30.0
Total	180	100

Diagram 2 Shows patients' frequency based on the time of involvement. According to Chi-Square test, the differences observed in the acute, Sub-acute, and chronic sinusitis radiographic signs were not significant (P= 0.219).

Cough (%89.4) and nasal purulent excretions (%53.2) were the most common clinical symptoms of sinusitis.

However, clinical signs in 2 groups of with positive radiographic results and the normal sinuses showed no statistically

significant difference ($0.11 < P < 0.83$) (table 2).

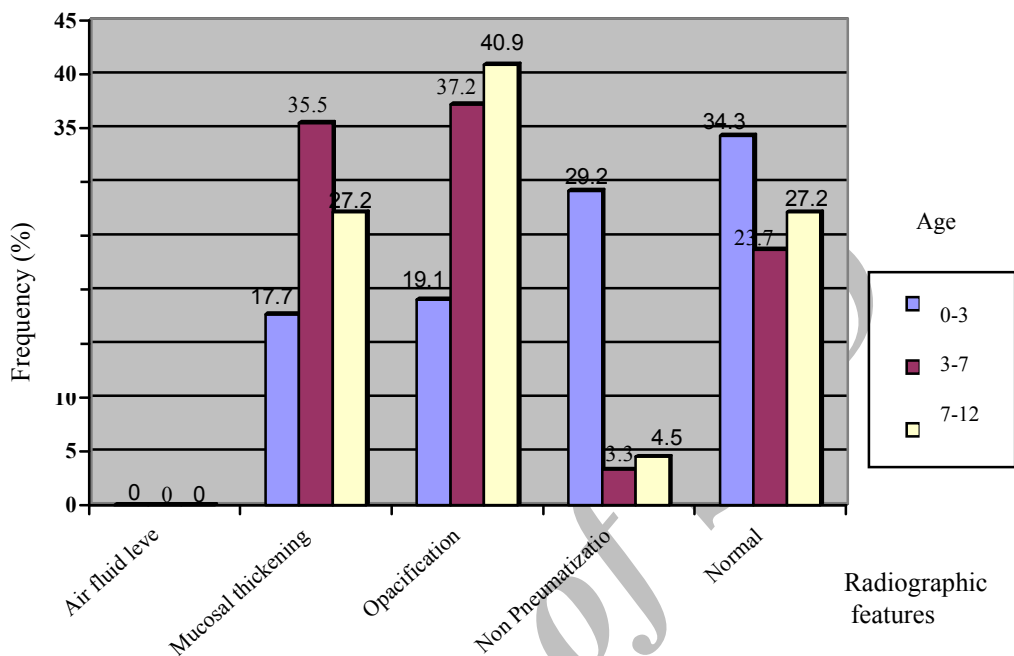


Figure 1: Distribution of patients, according to radiographic.

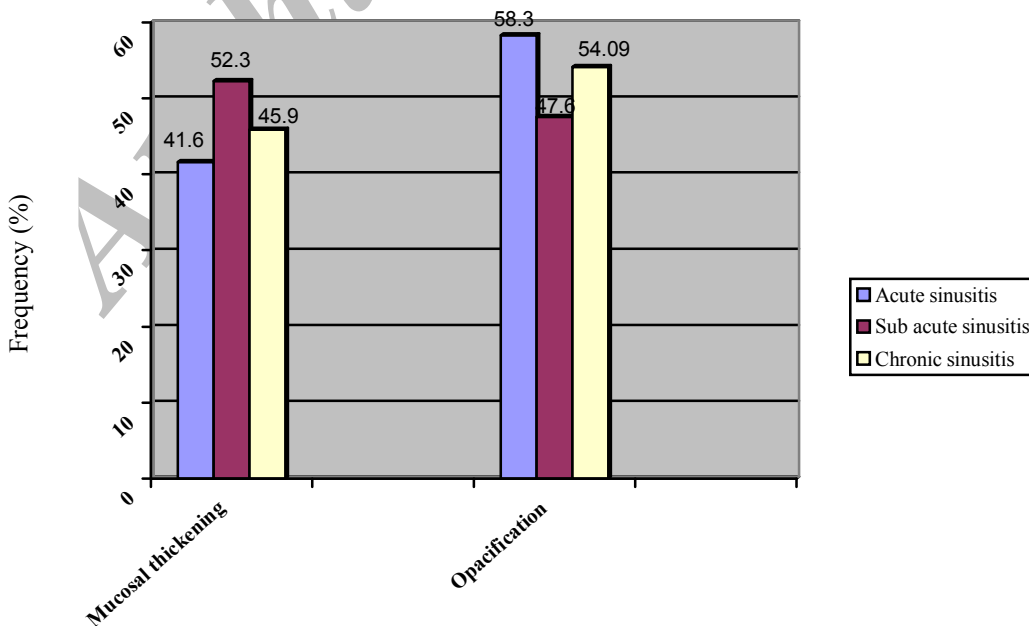


Figure 2: Distribution of patients, according to radiographic features and time of involvement.

Table2: Distribution of patients with positive radiographic results, according to clinical signs.

Clinical features	Frequency	Absolute frequency	Frequency percent
Cough		84	89.4
Instability& fatigue		30	31.9
Exudates drainage into the pharynx		7	7.4
Nasal purulent sexcretions		50	53.2
Mouth bad odor		41	43.7
Other signs		8	8.5

Discussion

The results of study on 180 Waters' radiographs of children with sinusitis will follow:

In 52.2% of the patients, radiographic signs were also confirmed with clinical signs. 30% of the radiographs were normal and in 17.8%, the sinuses had not gotten pneumatized and were not clear. In Revonta's study in 1989 on 85 children with acute sinusitis, the coefficient of agreement between Waters' radiographic signs and clinical features was expressed as 71% (5), and in a similar study in 2000 by Marashi on 200 adult patients with sinusitis, the coefficient was reported as 50%⁶.

The statistical difference between the studies in adults and children can be due to the more prevalence of the disease in children. By comparing the acquired data, in terms of differentiation between radiographic signs and age, we find out that although the greatest percentage of studied patients, regarding radiographic signs suggesting sinusitis, was relevant to the 3-years-olds group and under, but this group contained the least frequency of sinusitis, i.e. 36.39%. In contrast, the percentage of the individuals with non-pneumatized sinuses in this age group is more than the other groups. These results can be due to 2 points:

First, these results confirm the trend of the maxillary sinuses pneumatization after the age of 4 which have been stated in 2004

Nelson's book by Pappas et al⁴. Second, according to the surveys of Gransy et al, maxillary sinuses are full of fluid specially in the initial months after birth and are not interpretable in simple radiographs². The prescription of Waters' radiography in this age group is thus not recommended. In the other age groups too, in about 30% of cases, normal radiographic features were reported. Regarding the fact that the more the involvement duration, the more severe the radiographic features, it seems logical that in the 7-12 years-olds group, with increasing the involvement duration and frequencies of the signs manifestation, the sinuses opacity feature will be more observed (40.90%). The feature of mucosal thickening showed the highest frequency in the radiographs of the 3-7 years-olds group (35.59%). The increase of sinusitis radiographic features does not regularly change with the increase of age, and thus with the size of sinuses .It can be expressed that there is no correlation between the size of sinuses and the level of infection in radiographs. These results were also obtained in the study of Kronemer and McAlister in 1997⁷. In this study, the patients were also surveyed in terms of sex: 59% of them were male and 41% were female. In the studies conducted in adults, Tatli does not reckon a difference in terms of sex in the sinus diseases. Jense in 1997, however, reported a more prevalent sinusitis in women than in men^{8,9}.

In this study, the number of the male patients was higher. The radiographic features and trend of sinuses pneumatization were however the same in males and females, and the statistical difference can thus be due to the size of the studied samples. For the disease involvement duration and radiographic features, the results showed that in the acute and chronic states, the sinuses opacity feature was reported higher and in the sub-acute state, more increase of mucosal thickening was reported, and the fluid – air level was not seen at all.

In adults, when the fluid–air level, mucosal thickening, and sinuses opacity, show the trend of sinuses involvement.

These features are however different in children. In study of Wald for differentiation between acute and sub-acute sinusitis in children, it was expressed that radiographic features of mucosal thickening and sinuses opacity are commonly observed in the these two states¹⁰.

Therefore, in children, in contrast with adults, the fluid-air level is less commonly observed, due to more severity of the disease and high defense of the host, and instead sinuses opacity is seen even in the first weeks of the disease.

Furthermore, higher location of sinuses relative to the nasal cavity in children, causes the ease of the fluid drainage, and eventually, interprets the non observation of the fluid-air level. In the acute and sub-acute states, mucosal thickening increases. Sinuses opacity can be observed in terms of involvement duration and severity of the

disease. The analysis of the relation between clinical signs and radiographic features

shows that the most observed clinical symptoms are cough and nasal purulent excretions. There were more prevalent signs in children in both acute and sub-acute states. In similar studies on children (Garcia, 1994; Wald, 1989; Ros, 1995) Garcia stated that there was a clear relation between nasal purulent excretions and features severity in CT Scan^{10, 11, 12}. In addition, Tatli reckoned cough a prevalent problem in children with sinusitis⁹. In this study, clinical signs were surveyed in terms of 2 groups of with positive and normal radiographic results, and no statistically significant difference was observed. Tatli did not either obtain a significant relation between clinical and radiographic signs. Garcia however reported clinical signs in the patients group to be different from the normal group^{9, 11}.

According to this study, one clinical sign can not prognoses a disease. The existence of some clinical signs can however simultaneously indicate it.

Waters' radiography is thus recommended not to be prescribed for children, except for complicated diagnostic cases for the following reasons:

1. Non-pneumatized Sinuses especially in the 3 years-olds group and under, is not seen in radiography.
2. The high percentages of normal radiographic features in spite of the existence of clinical signs of sinusitis.

References

1. Rachelefsky GS, Goldberg M, Katz RM, Boris G, Gyepes MT, Shapiro MJ, et al. Sinus disease in children with respiratory allergy. *J Allergy clin immunol*. 1978 May; 61(5):310-314.
2. Grancy DO, Rice DH. Anatomy. In: Cummings CW, Fredrickson JM, Harker LA, editors. *Otolaryngology head and neck surgery*. 2nd ed. St. Louis: Mosby; 1993. p. 901-906.
3. Van Alyea OE. *Nasal sinuses: An anatomic and clinical consideration*. 2nd ed. Baltimore: Williams & Wilkins; 1951. p. 601-605.
4. Pappas DE, Hendley JO. Sinusitis. In: Behrman RE, Kleegman RM, Jenson HB, editors. *Nelson Text Book of Pediatrics*. 17th ed. London: Saunders; 2004. p. 1391-93.
5. Revonta M, Kuuliala I. The diagnosis and follow-up of pediatric sinusitis: Water's view radiography versus ultrasonography. *Laryngoscope*. 1989 Mar; 99 (3):321-24.

6. Marashi R, Abedini M.R. *The value of radiography for assessing sinusitis in patients with clinical symptoms. Medical Faculty, Isfahan University of Medical Sciences; 2000.*
7. Kronemer KA, McAlister WH. *Sinusitis and its imaging in the pediatric population. Pediatr Radiol. 1997 Nov; 27(11):837-46.*
8. Layd L, Sutton D. *Text book of Radiology and imaging. 3rd ed. New York: Churchill Livingstone; 1998. p. 1255-67.*
9. Tatli MM, San I, Karaoglaneglu M. *Paranasal sinus computed tomographic finding of children with chronic cough. Int J Pediatr Otorhinaryngol. 2001 Sep 28; 60 (3):213-17.*
10. Wald ER, Byers C, Guerra N, Casselbrant M, Beste D. *Subacute sinusitis in children. Jpediatr. 1989 Jul; 115 (1):28-32.*
11. Garcia DP, Corbett ML, Eberly SM, Joyce MR, Le HT, Karibo JM, et al. *Radiography imaging studies in pediatric chronic sinusitis. J Allergy clin immunol. 1994 Sep; 94 (3 Pt1): 523-30.*
12. Ros SP, Herman BE, Azar -Kia B. *Acute sinusitis in children : is the Waters' view sufficient? Pediatr Radiol. 1995; 25(4):*

Archive of SID

Archive of SID