

Case Report

Human Infection with *Uncinaria* in North of Iran

E Ghadirian

Pathobiology Laboratory Center, No: 3, Abshar St, Valiasr Ave, Tehran, Iran

(Received 16 Apr 2007; accepted 20 May 2007)

Introduction

Uncinaria species are worms belonging to the hookworms group, and infect many animal species in various parts of the world. Human infection with the worm is found in a few areas of the world. The *Uncinaria stenocephala* is reported among 22% of prisoner in Madrid, Spain (1), and among 2.6% of 38 inhabitants of periurban of a city near Buenos Aires, Argentina (2).

The human infection with hookworms, including *Ancylostoma duodenale* and *Necator americanus* found in north of Iran along the Caspian Sea (3).

In one study among population of the village of Karger Mahaleh carried out in 1972, hookworms

collected after treatment of 128 patients revealed the presence of 358 male and female *Ancylostoma* and 3783 male and female *Necator* (3). In addition, 14 (8 females and 6 males) hookworms were found that after necessary studies were identified as *Uncinaria* species. Some specimens of this species sent to the London Museum (Natural History) confirmed that species were *U. stenocephala*.

Another hookworm species found from the same region was a new *Necator* species which is not named yet (4).

This finding is important because human infection with this parasite has never been reported from Iran and neighboring countries. Therefore, it merits to be reported after a long time.

Acknowledgements

The author is highly indebted to Prof. F Arfaa for his help and to Dr I Mobedi for providing the photos.

References

1. Alonso-Sanz M, Chaves F, Dronda F, Catalan S, Gonzalez-Lopez A. [Intestinal parasitoses in the prison population in the Madrid area (1991-1993)]. *Enferm Infecc Microbiol Clin*. 1995; 13(2):90-5.
2. Pezzani BC, Minvielle MC, De Luca MM, Radman N, Iacoy P, Basualdo Farjat JA. [Intestinal parasite infections in a periurban community from the Province of Buenos Aires, Argentina]. *Bol Chil Parasitol*. 1996 Jan-Jun; 51(1-2):42-5.
3. Ghadirian E, Sanati A. Preliminary studies on the treatment of hookworm with pyrantel pamoate in Iran. *J Trop Med Hyg*. 1972; 75 (10):199-201.
4. Ghadirian E, E Biocca Su un. Particular *Necator* parassita dell'uomo rinvenuto in Iran. *Parassitologia*, XIV No.1 Giugno 1972.

Some essential difference between species *Uncinaria stenocephala* and *Necator americanus*

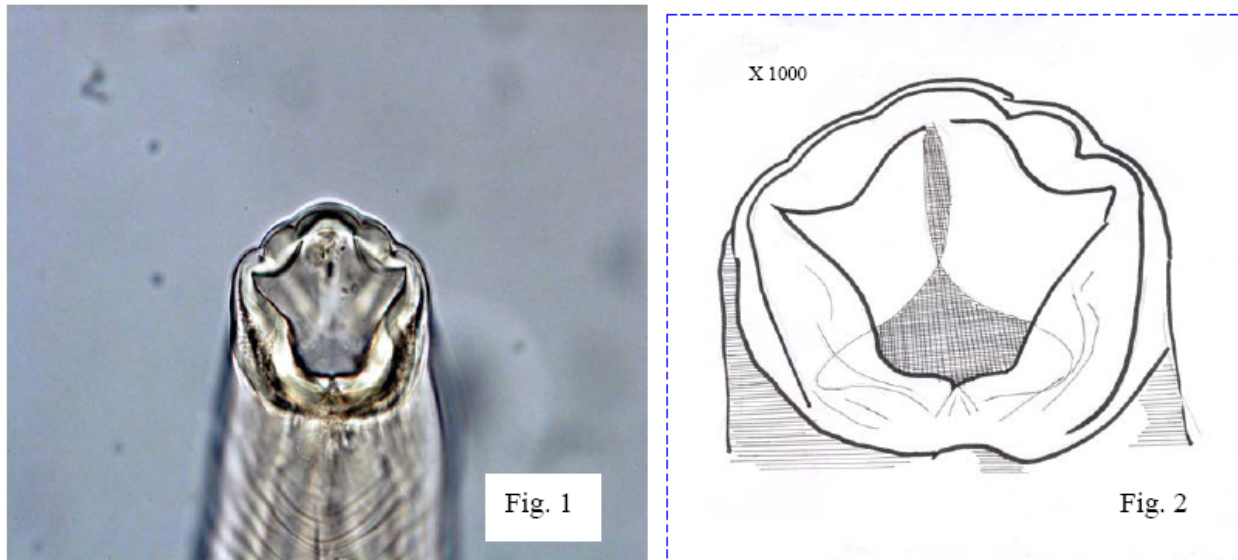


Fig. 1 and 2: Buccal capsule (B.cavity) of *Uncinaria*

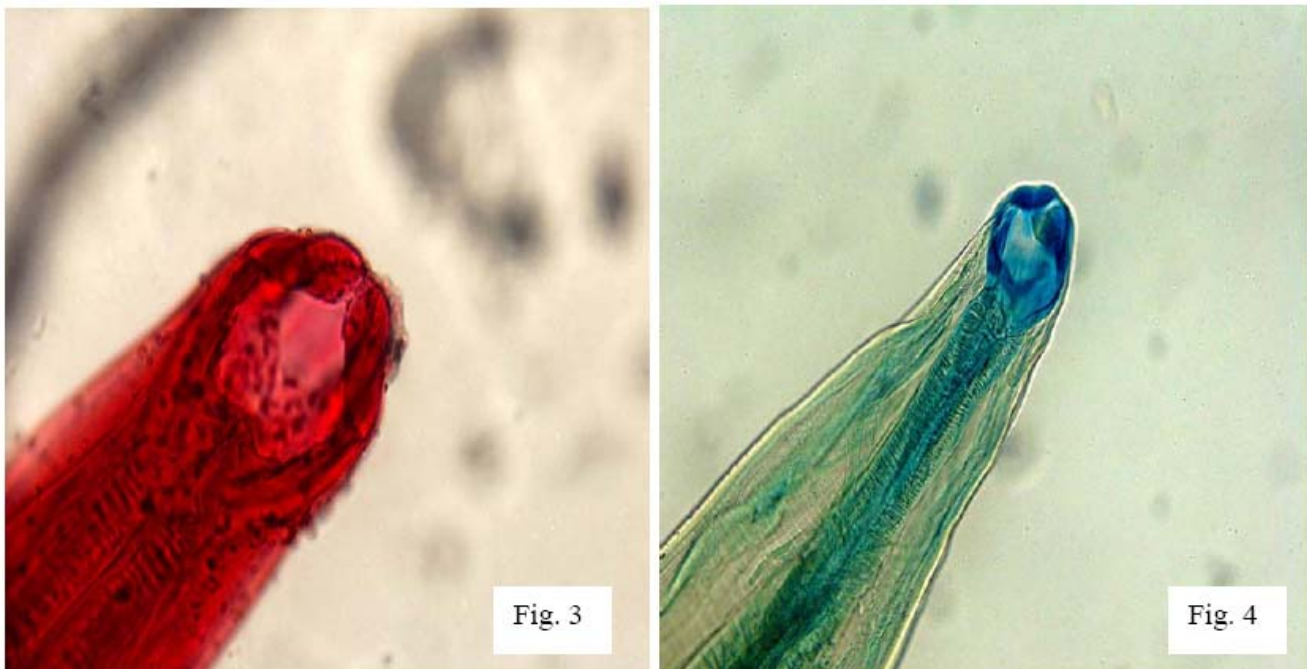

Fig. 3 and 4: Buccal capsule of *Necator*

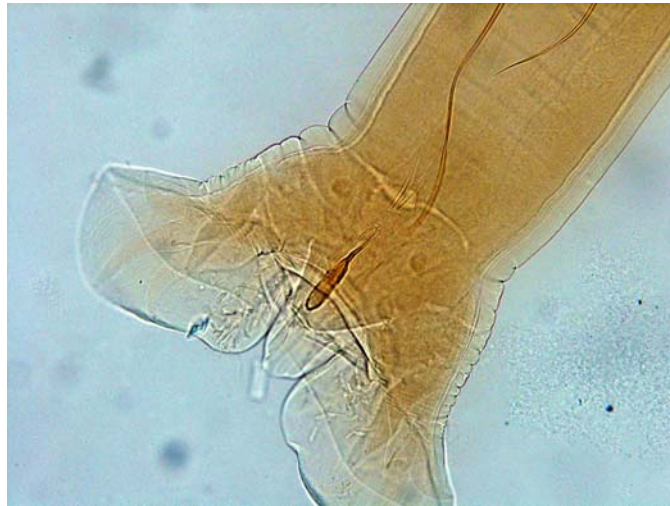

Fig. 5: Male *Uncinaria* : capulatory Bursa and posterior end of 2 spicules and one gubernaculum (Spicules without hooks)

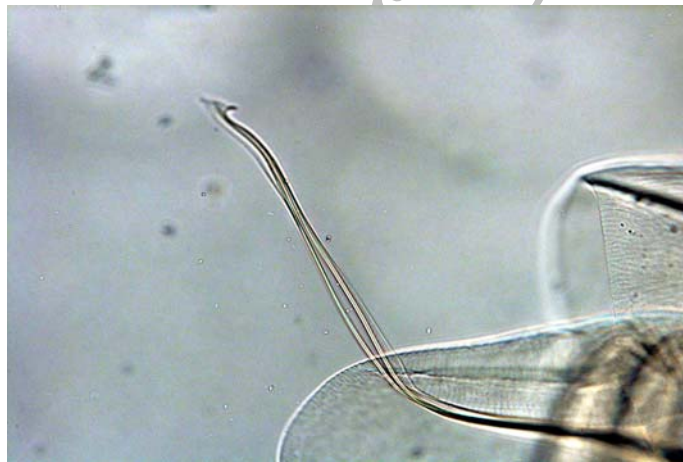


Fig. 6: Male of *Necator*: one part of capulatory Bursa and 2 Spicules (with hooks and without gubernaculum)

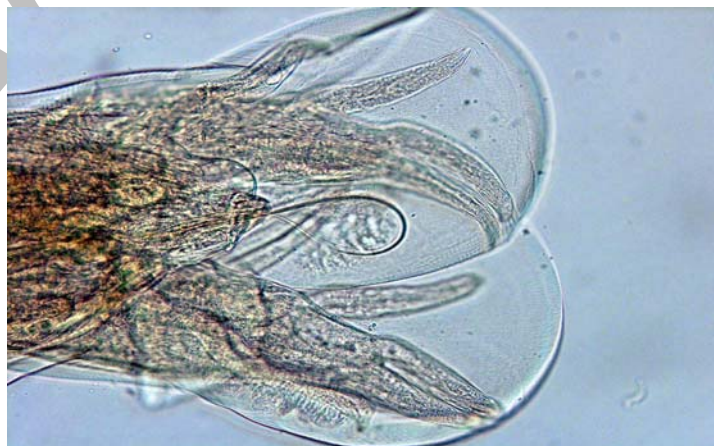

Fig.7: Male *Necator* , with complete capulatory Bursa

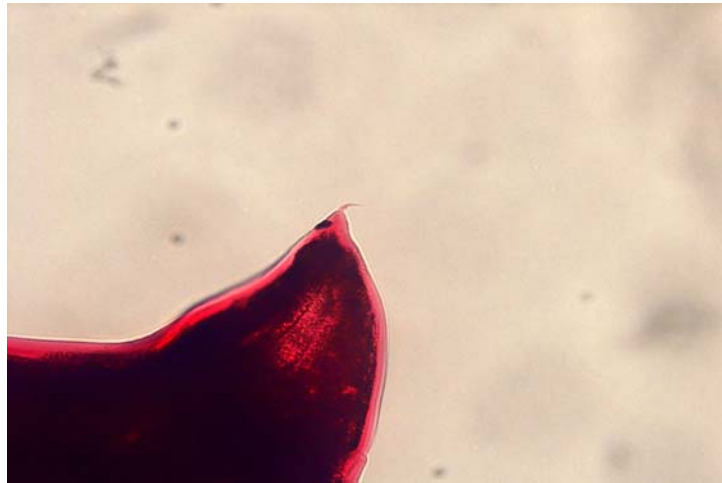


Fig. 8: Posterior end of female *Uncinaria* with spine

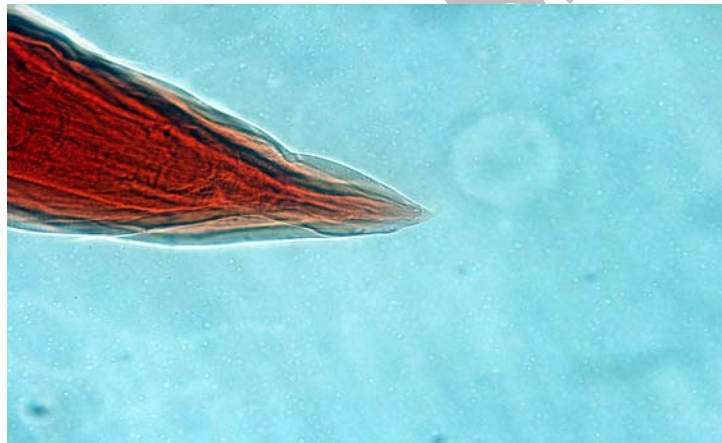

Fig. 9: Posterior end of female *Necator* without spine

Note. More information: capulatory Bursa and Spicules of male *Uncinaria* are similar to *Ancylostoma*. posterior end of female *Uncinaria* is similar to *Ancylostoma* (*Uncinaria* and *Ancylostoma* both have Spines)