

Original Article

Histopathological Features of *Ornithodoros lahorensis* Bite on Rat

*E Tavassoli¹, S Zare¹, F Ghaderi Pakdel², AA Tehrani³, M Tavassoli³

¹Dept. of Biology, Faculty of Science, Urmia University, Urmia, Iran

²Dept. of Physiology, Faculty of Medicine, Urmia Medical Science University, Urmia, Iran

³Dept. of Pathobiology, Faculty of Veterinary Medicine, Urmia University, Urmia, Iran

(Received 14 Aug 2007; accepted 11 Nov 2007)

Abstracts

Background: Besides of transmitting several diseases to animals, and tick paralysis, *Ornithodoros lahorensis* induce skin lesions. This experiment was done to determine histopathological features of adult *O. lahorensis* bite on rat.

Methods: In this investigation adult male rats were infested with *O. lahorensis* ticks. Animals were divided into two groups and euthanized two days and two weeks after infestation. The skin samples were fixed in 10% buffer formal saline and processed and sections were stained with hematoxylin & eosin.

Results: The lesions reflected the clinical and gross findings, with hyperemia, edema and vacuolation in the early stages, cellular infiltrations, principally lymphocyte accompanied vascular changes. Newly formed fibrous tissue with large number of hyperemic capillaries and active inflammatory process in which lymphocytes and eosinophils were the predominant cells, were seen after two weeks. Foci of necrosis in the epithelium with remnant of infiltration of polymorphonuclear cells with sever hemorrhages were also evident. Vascular changes included prevascular infiltration of lymphocyte and fibrinoid necrosis on the vessel walls.

Conclusion: This study well documented the different pathological changes of skin of rats with *O. lahorensis*.

Keywords: *Ornithodoros lahorensis*, Histopathological features, soft Tick, Tick bite, Rat

Introduction

Ticks are obligate blood feeders that parasitize a wide variety of terrestrial and flying vertebrates (1). Ticks of medical and veterinary importance are divided into two families: Argasidae (soft ticks) and Ixodidae (hard ticks) (2). Both are important vectors of disease causing agents in human and animals throughout the world. Ticks transmit the widest variety of pathogens of any blood sucking arthropod, including bacteria, rickettsia, protozoa, and viruses (3-5). More than 800 tick species have been described in the world (4, 6). There are about 170 species of argasid ticks. They have a soft, 'leathery' body and feed for a relatively

short period of time, usually 5–25 min (varying from several minutes to days), depending on such factors as life stage, host type, and species of tick (7). There are approximately 650 species of ixodid ticks which are characterized by a hard body plate and a prolonged period of feeding, sometimes as long as 11 days (8).

There are three visible components on tick mouth part: the two outside jointed parts are the highly mobile palps; between these are paired chelicerae, which protect the center rod-shaped structure, the hypostome. After a site for feeding has been chosen, the tick begins to lacerate the epidermal layers using the horizontal action of its cheliceral digits. These are paired appendages for cutting, ripping and tearing skin.

The rough hypostome has many beak-like projections on it. This is the structure which plunges into the host's skin while feeding. The palps move laterally while the tick is feeding and do not enter the skin of the host. Once the tick is firmly attached, as blood flows into the wound site, the tick begins feeding and the buccal canal becomes a common duct for the intake of host tissue fluids and the output of tick saliva (9).

O. lahorensis, originally an ectoparasite of wild sheep resting in the lee of cliffsides, is an important pest of stabled livestock in lowlands and mountains of Tibet, Kashmir, and southern former USSR to Saudi Arabia and Turkey, Iran, Greece, Bulgaria, and Yugoslavia (10). Six species of *Ornithodoros* are listed between 55 ticks species were reported from Iran. *O. lahorensis* is a major soft tick species in Iran (11-13). *O. lahorensis* vector of *Theileria ovis* and *Anaplasma ovis* and cause of tick paralysis of sheep in central Asia (14). Despite of transmit several disease to animals, and tick paralysis (15) in addition *O. lahorensis* induce skin lesions. This experiment was done to determine histopathological features of adult *O. lahorensis* bite on rat.

Materials and Methods

Twelve adult male rats (250 gram weight) obtained from The University of Urmia Central Animal Breeding House was used in this experiment. Wild-caught adult *O. lahorensis* ticks were collected from infested sheep farms from Tekab City, West Azerbaijan of Iran and kept them in laboratory condition. Adult male Wister rats (n=6 in two groups) were anaesthetized by intraperitoneal injection of Ketamine hydrochloride (200 mg/kg). Four ticks were applied to a clipped area over the shoulders of each rat and contained within gauze-covered

light plastic rings (2.5 cm diameter) glued to skin. Rats were caged individually and were monitored until ticks engorged. Animals were divided into two groups and euthanized two days and two weeks after infestation.

The skin samples from the infested rats were collected in 10% buffer formal saline and processed for histopathology. Paraffin blocks were made; 4-5 micron sections were cut and stained with hematoxylin and eosin. They were examined under light microscope and observations were recorded.

All animal right issues were confirmed by Ethic Committee in the university.

Results

Soft ticks that used in this experiment were attached at least 1-2 days to rat's skin. Host tissue reaction to salivary component following tick probing and blood feeding on rat skin varied grossly from small papule in group 1 to large pruritic swelling in group 2. The histopathological findings in group 1 included the inflammatory phase marked with edema and hyperemia of capillaries (Fig.1). Cellular infiltration principally lymphocyte accompanied vascular changes. Vascular damages were endothelial swelling with fibrinoid necrosis. Perivascularitis was present in some vessels with infiltration of lymphocytes (Fig. 2) and eosinophils. Foci of necrosis in the epithelium with remnant of infiltration of polymorphonuclear cells with severe hemorrhages were also evident (Fig. 3). In group two, histopathology revealed that lesion involving broad area of the epidermis often with moderate to severe cellular infiltration, loosely arranged newly formed fibrous tissue and active inflammatory process in which lymphocytes and macrophage were predominant (Fig. 4). The predominant inflammatory cells were lymphocytes and macrophages.

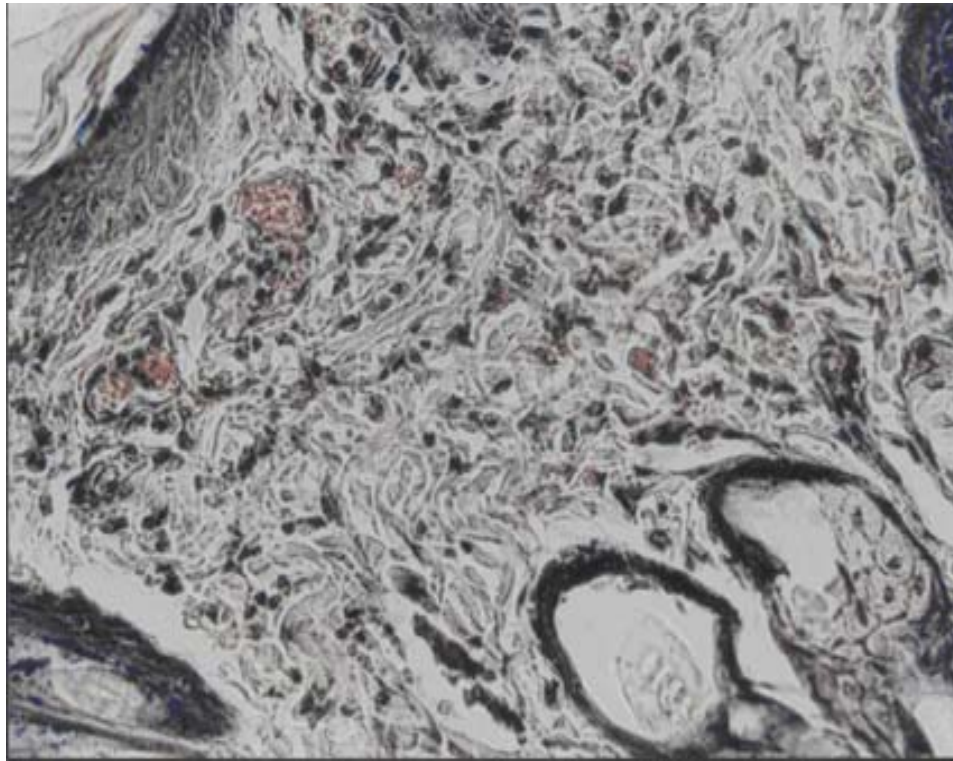


Fig. 1: Infiltration of the inflammatory cells mainly lymphocytes in the derm of the skin of a rat in group 1(H &E x 400).



Fig. 2: Mild perivascular cellular infiltrate mainly composed of lymphocytes with congestion and edema in group 1 (H &E x 400).

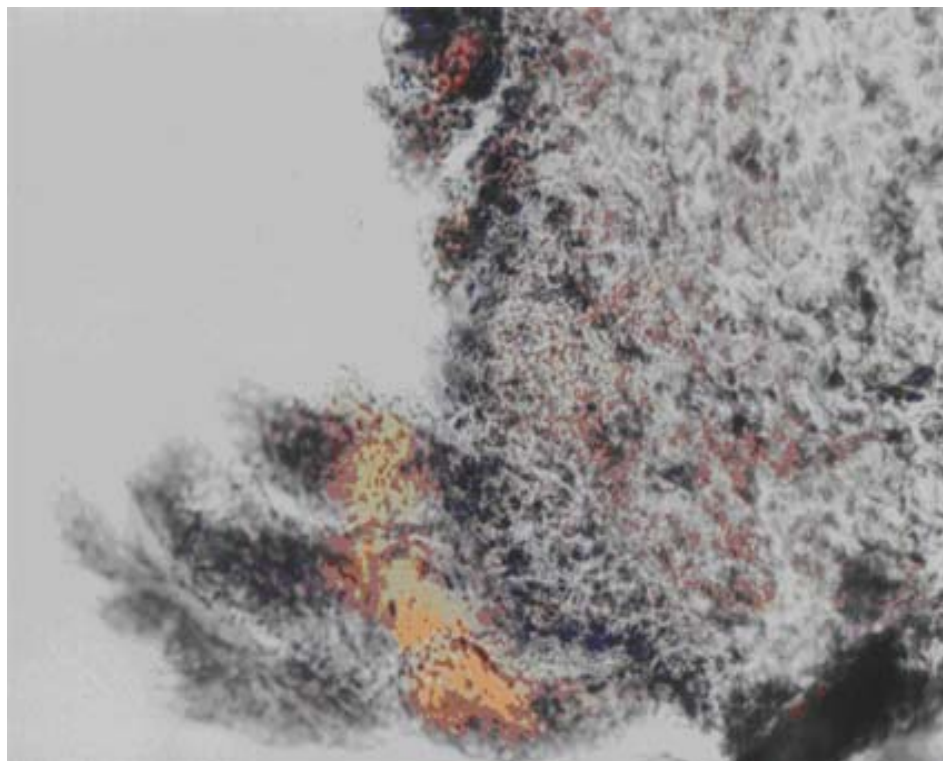


Fig. 3: Epithelial necrosis and hemorrhage in the skin of a rat in group 1(H &E x 400).

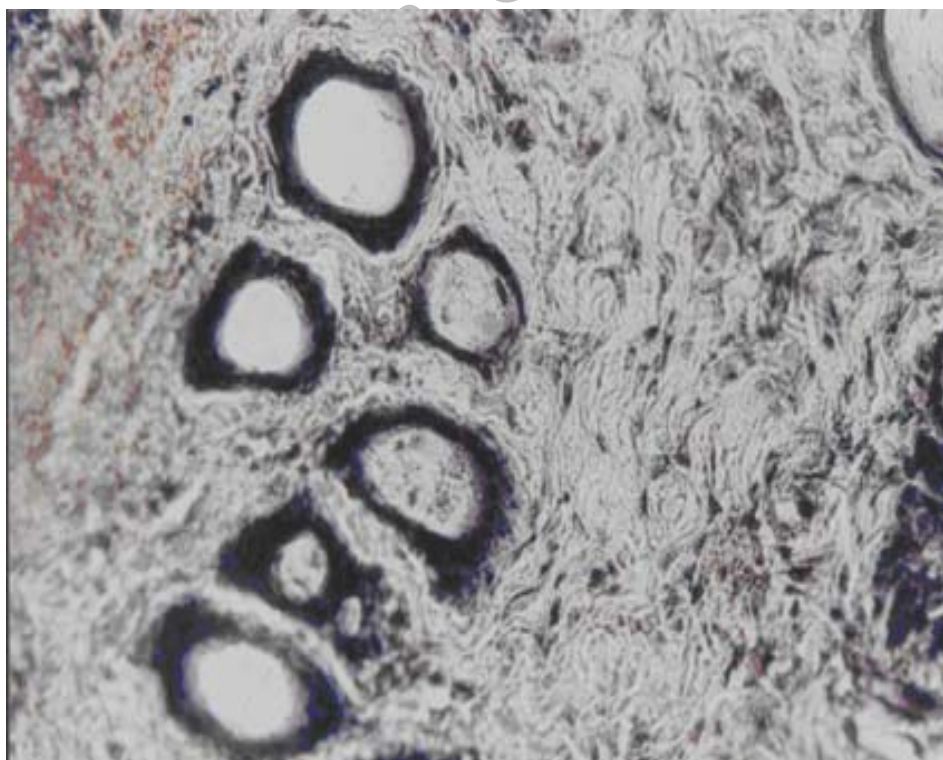


Fig. 4: Loose arrangement of the newly formed thin collagen fibers, in the skin of a rat in group 2 (H &E x 400).

Discussion

Several attempts have been directed to study the pathological features of hard ticks bites such as *Amblyomma americanum* in the human (16), *Rhipicephalus sanguinus* in dog (17), *Ixodes* spp. in mammals and birds (18-20), *A. variegatum* and *R. appendiculatus* in cattle and rabbit (21,22) and *Hyalomma anatolicum anatolicum* in rabbit (23). To the best of our knowledge, no report has yet been released on the histopathology of *O. lahorensis* bite lesions, thus this study was aimed to determining the histopathologic changes of rat skin in feeding places of soft tick *O. lahorensis*.

The severity of the skin reaction to tick feeding may depend on several variables, including duration of feeding, size of the mouthparts, type of tick secretions (e.g., saliva or cement), changes in secretion during feeding, previous exposure of the host to the tick or related species, and allergic reactions of the host (24).

In our study with respect to the pathology of inflammation in both groups it was shown cutaneous lesion associated with vasculitis, cutaneous necrosis and inflammatory reaction mainly lymphocytic.

Lima et al., 2004 described Microscopic features of tick-bite lesions in anteaters and armadillos, tick feeding sites displayed the cement cone, and occasionally, a feeding cavity underneath the tick attachment site. The main dermal changes included tissue infiltration with a varying number of inflammatory cells, edema, hemorrhage and vascular dilatation. Cellular infiltration of the dermis was predominantly composed of mononuclear cells, neutrophils and eosinophils (25).

The ultrastructural characteristics of the histopathological changes at the site of attachment to the host body of larvae of the ixodid tick *Ixodes ricinus* showed the intensive neutrophil migration. At the same time the erythrocytes and active fibroblasts were found in the feeding site (20). Attachment sites *A. variegatum* and *R. appendiculatus* showed acute inflammatory lesions,

delayed hypersensitive reactions with intra-epidermal pustulation and significant increases in the numbers of granulocytes. The predominant cells infiltrating attachment sites on high resistance cattle were eosinophils with *A. variegatum* and neutrophils with *R. appendiculatus* (21, 22).

We found the similar tissue reaction with *O. lahorensis* infestation except the lymphocytes the most predominant cells changes in the early stage and lymphocytes and eosinophils two weeks after infestation and we did not find any cement cone (external cement) on the surface of host epidermis. Lymphocyte infiltration and vascular changes indicate an allergic reaction. Immunologic reactivity, such as delayed, type IV Gell and Coombs reaction, will lead to induration and nodular formation (26). Immediate, type I Gell and Coombs reactions have also been suggested as possible contributors to cutaneous reactions to tick bites. It is further postulated that this immediate hypersensitivity is an important protective response against blood-feeding arthropods (26-28). Mast cells accumulate in the tick attachment site in the skin of natural host and degranulate in response to the tick salivary antigens releasing the histamine. Mediators involve cutaneous hypersensitivity reactions (19). Symptoms associated with reactions to tick bite peaked in severity at 35-40 hours and thus the response was most likely delayed type IV hypersensitivity (29) Histological examinations of a pruriginous lesion revealed lymphocytic dermal and perivascular infiltration (30).

Tick bites most often occur in spring and summer and are painless. The vast majority are uncomplicated and do not transmit disease; they often cause a red papule at the bite site and may induce hypersensitivity or granulomatous foreign body reactions. A granuloma can develop if a tick is removed improperly (31). Most bites heal within 3 weeks; however, a persistent nodule (tick granuloma) might last for months (25). The bites of *Ornithodoros coriaceus* ticks cause local vesiculation, pustulation with rupture, ul-

ceration, and eschar, with varying degrees of local swelling and pain. Similar reactions have occurred from bites of other ticks (10).

Once on the host, the tick must attach itself, neutralize the host defense and local haemostatic systems and prepare itself for sucked blood from the host (32). When the tick is firmly attached, as blood flows into the wound site, the tick begins feeding and the buccal canal becomes a common duct for the intake of host tissue fluids and the output of tick saliva (9). The three components of the host defense system which have to be overcome are homeostasis, the inflammatory response and cell mediated immunity. Anticoagulants and anti-inflammatory agents secreted in the ticks saliva counter the first two problems but cell mediated immunity is more difficult to deal with and many ticks succumb or depart without feeding when attempting to attach to previously exposed hosts (9).

Inoculation eschar occurred at the tick bites and consists of epithelial necrosis with hemorrhage. They represent the portal of entry of the infectious agent into the host and the first site of challenge with the host. Epithelial necrosis was found at the limit between the dermal and epithelium suggesting mouthparts pierced skin to the depth where capillaries and vessels are in the upper dermis (7).

We showed that cutaneous damage is dominated by hyperemia, edema and vacuolation, cellular infiltrations, principally lymphocyte accompanied vascular changes in the early stage and newly formed fibrous tissue with large number of hyperemic capillaries and active inflammatory process in which lymphocytes and eosinophiles were the predominant cells were seen after two weeks. In the similar survey histological analysis of adult *H. anatolicum anatolicum* feeding sites on rabbits showed that the cellular reactions at tick feeding sites change in character and magnitude with time after attachment, and differ considerably (23). This study well documented the different pathological changes of skin of rats with *O. lahorensis*.

Acknowledgements

Authors would like to thank Mr E. Agapour and Mr A. Morvaridi for their technical assistance. Urmia University supported this research financially. The authors declare that they have no Conflict of Interests.

References

1. Hoogstraal H. Argasid and Nuttalliellid ticks as parasites and vectors. *Adv Parasitol.* 1985;24:135-238.
2. Sonenshine DE. *Biology of ticks*, Vol. 1. New York: Oxford University Press. 1991a.
3. Parola P, Raoult D. Ticks and tickborne bacterial diseases in humans: An emerging infectious threat. *Clin Infect.* 2001;32: 897-928.
4. Keirans JE. Systematic of the Ixodida (Argasidae, Ixodidae, Nuttalliellidae): an overview and some problems. In: B Fivaz, T Petney, I Horak (Eds), *Tick Vector Biology. Medical and Veterinary Aspects*, Springer-Verlag, Berlin;1965. p. 1-21.
5. Oliver Jr JH. Biology and systematics of ticks (Acari: Ixodida). *Annu Rev Ecol Syst.* 1989;20:397-430.
6. Camicas JL, Hervy JP, Adam F, Morel PC. *Les Tiques du Monde. Nomenclature, Stades Décrits, Hôtes, Répartition (Acarida, Ixodida)*, Orstom, Paris; 1998.
7. Grattan-Smith PJ, Morris JG, Johnston HM, Yiannikas C, Malik R, Russell R, Ouvrier A. Clinical and neurophysiological features of tick paralysis. *Brain.* 1997;120: 1975-1987.
8. Bowman AS, Dillwith JW, Sauer JR. Tick salivary prostaglandins: presence, origin and significance. *Parasitol Today.* 1992;12: 388-96.
9. Kemp DH, Stone BF, Binnington KC. Tick attachment and feeding: role of the mouthparts, feeding apparatus, salivary

- gland secretions and the host response. In: Obenchain FD, Galun R, editors. Physiology of ticks. Oxford: Pergamon Press; 1982.
10. Fraser CM. The Merck Veterinary Manual. 6th ed. Merck & Co., Rahway, N.J., USA; 1986.
 11. Abbassian-Lintzen RA. Preliminary list of ticks (Acarina: Ixodidae) occurring in Iran, and their distributional data. *Acarol.* 1960;2(1):43-61.
 12. Rahbari S. Studies on some ecological aspects of tick fauna of West Azarbayejan, Iran. *J Appl Anim Res.* 1995;7(2):189-194.
 13. Mazlum Z. Different ticks occurring in Iran (geographical distribution, seasonal activities, hosts). *Bull Fac Vet Med.* 1960;27(1):1-32.
 14. Soulsby E.J.L. Helminths, arthropoda and protozoa of domesticated animals. 7th ed. Bailliere Tindall, London, England; 1986.
 15. Mamedkulov K. Tick paralysis in sheep in Turkmenistan farms. *Veterinarya-Moskva.* 1993;1:40-41.
 16. Fisher EJ, Jun Mo MD, Anne MD, Lucky W. Multiple Pruritic Papules From Lone Star Tick Larvae Bites. *Arch Dermatol.* 2006;142:491-494.
 17. Heijden K, Szabó M, Egami M, Pereira M, Matushima E. Histopathology of Tick-Bite Lesions in Naturally Infested Capybaras (*Hydrochoerus hydrochaeris*) in Brazil. *Exp A Acarol.* 2005;37(3-4): 245-255.
 18. Grigor'eva LA. Histopathologic changes of bird skin in feeding places of ticks of the genus *Ixodes* (Acari: Ixodidae). *Parazitologia.* 2001;35(6):490-5.
 19. Grigor'eva LA. Histopathological changes in the skin of small mammals in the area of feeding of *Ixodes trianguliceps*, *I. persulcatus*, *I. ricinus* (Ixodidae) ticks. *Parazitologia.* 2001;35(3):177-83.
 20. Amosova LI. The ultrastructural characteristics of the histopathological changes at the site of attachment to the host body of larvae of the ixodid tick *Ixodes ricinus* [Parazitologia. 1994;28(5):356-63.
 21. Latif AA, Maina JN, Dhadialla TS, Nokoe S. Histological reactions to bites of *Amblyomma variagatum* and *Rhipicephalus appendiculatus* (Acari: Ixodidae) fed simultaneously on naive or sensitized rabbits. *J Med Entomol.* 1990;27(3):316-23.
 22. Latif AA, Punyuna DK, Capstick PB, Nokoe S, Walker AR, Fletcher JD. Histopathology of attachment sites of *Amblyomma variegatum* and *Rhipicephalus appendiculatus* on zebu cattle of varying resistance to ticks. *Vet Parasitol.* 1991;38(2-3):205-13.
 23. Gill HS, Walker AR. Differential cellular responses at *Hyalomma anatolicum anatolicum* feeding sites on susceptible and tick-resistant rabbits. *Parasitol.* 1985;91(3): 591-607.
 24. Krinsky WL. Dermatoses associated with the bites of mites and ticks (Arthropoda: Acari). *Int J Dermatol.* 1983;22:75-91.
 25. Lima e Silva MF, Szabo MP, Bechara GH. Microscopic features of tick-bite lesions in anteaters and armadillos: Emas National Park and the Pantanal region of Brazil. *Ann N Y Acad Sci.* 2004;1026: 235-41.
 26. Wikel SK: Immune responses to arthropod and their products. *Ann Rev Entomology.* 1982;27:21-48.
 27. Metry DW. Insect and arachnid stings, bites infestations, and repellents. *Pediatr Ann.* 2000;29:39.
 28. Jacobs RF. Tick exposure and related infections. *Pediatr Infect Dis J.* 1988;7: 612-614.
 29. Humphery-Smith IYH, Thony D, Moorhouse C, Creevey MG, Stone B. Reactions to argasid tick bites by island residents on the Great Barrier Reef. *Med J Aust.* 1991;5;155(3):181-6.
 30. Beaudouin E, Kanny G, Guerin B, Plenat F, Moneret-vautrin DA. Unusual manifestations of hypersensitivity after a tick bite:

- report of two cases. *AnnAllergyAsthmaImmunol.* 1997;79(1):43-6.
31. Middleton DB. Tick-borne Infections. *Postgrad Med.* 1994;95:131-139.
32. Sonenshine DE. The mouthparts & foregut: capitulum, pharynx and oesophagus. In: Sonenshine DE. *Biology of ticks*, Vol. 1. New York: Oxford Uni Press;1991b.

Archive of SID