



Tehran University of Medical
Sciences Publication
<http://tums.ac.ir>

Iranian J Parasitol

Open access Journal at
<http://ijpa.tums.ac.ir>



Iranian Society of Parasitology
<http://isp.tums.ac.ir>

Original Article

Mineral Status of Myocardial Sarcocystosis

*GA Kojouri¹, E Aghajani², S Jahanabadi³, A Kojouri⁴

¹Department of Clinical Sciences, School of Veterinary Medicine, Shahrekord University, Shahrekord, Iran

²School of Veterinary Medicine, Shahrekord Azad University, Shahrekord, Iran

³Pharmacology Department, Tehran University of Medical Science, Iran

⁴Faculty of Medicine, Yazd International Medical University, Yazd, Iran

(Received 12 Jan 2011; accepted 14 Apr 2011)

ABSTRACT

Background: The role of minerals on parasite persistency and the interaction between minerals and animal responses to the parasite infestation is not clear. For these reasons, the present research was aimed to compare copper, zinc and iron status in sheep with parasitic myocarditis and healthy ones in 2009.

Methods: Blood and heart tissue samples were collected from 145 slaughtered sheep and histopathological findings were confirmed as myocardial sarcocystosis in 27 cases. Serum and tissue mineral level were determined by atomic absorption spectroscopy. Data were analyzed by Sigmasat program, using One Way Analysis of Variance (ANOVA) at the level of $P < 0.05$.

Results: Myocardial sarcocystosis significantly increase myocardial concentration of Cu, Zn and Fe ($P < 0.05$).

Conclusion: These findings may explain the role of copper, zinc and iron in parasite persistency and may discuss the pathogenesis of sarcocystosis, which relates to evocate mentioned micronutrient to cardiac muscle.

Keywords: Sarcocystosis, Myocardium, Mineral, Sheep

* Corresponding author: Tel/Fax: 00983814424427. E-mail: kojouri@vet.sku.ac.ir

Introduction

S*arcocystis* species are intracellular protozoan parasites with a requisite two-host life cycle based on a prey-predator (intermediate-definitive) host relationship (1). Sheep may be infected by four species of *Sarcocystis*: *Sarcocystis tenella* and *S. arieticanis* are pathogenic, *S. gigantea* and *S. medusiformis* are non-pathogenic. The two pathogenic species may cause abortion or acute disease during the early phase of infection and chronic disease during the late phase of infection (2). Heart, diaphragm and skeletal muscle are preferred organs for *Sarcocystis* spp. (3). Cysts of *S. tenella* may also be formed in cells of the central nervous system or in Purkinje fibers of the heart (2). Lesions in the vessels, tongue, oesophagus, and heart are extensive and may have caused clinical dysfunction, including poor apprehension of food and swallowing, or myocardial function (4, 5). Diagnosis of disease or abortion caused by *S. tenella* and *S. arieticanis* in sheep has been complicated by the fact that used immunological tests are only genus-specific and, therefore, cannot differentiate infections with pathogenic *Sarcocystis* species from infections with non-pathogenic species. In addition, most serological tests can only detect antibodies during the late phase of infection. Thus far, diagnosis of infections with pathogenic *Sarcocystis* species has been based mainly on histological detection of meronts at post mortems (2, 6).

Yarim et al. (2004) indicate that sarcocyst contains immuno-suppressant substances like corticosteroids (7). It is also noticed that immunosuppression may be associated with infectious agents such as bacteria, viruses, protozoa, and helminthes but the pathogenesis of these has not been well-explained (8). Infectious agents may have some politics to survive well, protect themselves from

phagocytosis and prepare benefit conditions (like immunosuppression) to spread. It is also showed that immunosuppression may result from trace minerals deficiency (8). Nutritional deficiencies can depress structural and metabolic functions of the cellular and humoral immunity (9) and have a major effect on normal development of the immune system (10). To this reason, addition of certain trace elements such as copper, iron, zinc and selenium in animal feeds is necessary for an adequate immunity (8). Iron is necessary for immune cell proliferation and copper is essential for oxidative phosphorylation (cytochrome-*c* oxidase), cellular antioxidant activity (superoxide dismutase), connective tissue formation (lysyl oxidase), neurological functions (dopamine β -hydroxylase) and iron metabolism (ceruloplasmin), either. Zinc can alter immune response to infections and its deficiency results in lymphoid atrophy and decreased capacity of T cells to respond to T dependent antigens (11, 12).

It seems very important to know the minerals role on parasite persistency and the interaction between minerals and animal responses to parasite infection, two major hypotheses that may explain the pathogenesis of sarcocystosis. For these reasons, the present study was designed to evaluate and compare serum and myocardial tissue copper, zinc and iron concentration in healthy and sheep with myocardial sarcocystosis.

Materials and Methods

This study was conducted in Shahrekord slaughterhouse situated in Chahar Mahal va Bakhtiary Province (Iran) to determine the presence of sheep myocardial sarcocystosis from April to August 2009. During ante mortem examination, age and geographical

origin of animals were recorded and sheep was given an identification number. Through several visits, information was gathered and 145 sheep, aged between 2 to 3 years were sampled. Ten ml of blood, 5 grams and one-cm³ myocardial samples were taken for micronutrient analysis and histopathological examination, respectively.

For microscopic examination, labelled samples fixed in buffered neutral formalin 10% and paraffin sections were cut at 5 μ m then stained with haematoxylin and eosin (H&E). Light microscopic examination was confirmed the presence of myocardial sarcocystosis in 27 cases. Due to histopathology findings, samples were divided in unaffected (27 cases) and sarcocystosis (27 cases) groups and the concentration of copper, zinc and iron in serum and myocardium were determined by atomic absorption spectroscopy (10, 12). According to the geo-graphical origin of sampled sheep, the amounts of Cu, Zn and Fe (Mean \pm SE) in the ration, on dry matter basis, were determined as 20.54 \pm 3.25, 16.16 \pm 2.05, and 181.33 \pm 72.68 (mg/kg), respectively. Finally, serum and tissue values were reported by mean \pm SEM and data were analyzed by Sigmastat program, using

One Way Analysis of Variance (ANOVA) at the level of $P < 0.05$.

Results

Some samples revealed macroscopic sarcocysts in the gross examination, whereas in the microscopic examination, sarcocysts in variable sizes and numbers were encountered from 27 out of the 145 sheep (Fig. 1). These samples were taken from older animals, since the presence of the parasite increased with age (13, 14). Sarcocysts of all samples had similar morphologies and were of thin-walled type. Most of the affected samples were free from degenerative or inflammatory changes but in some samples, the cysts were found in foci of tissue necrosis and appeared to be degenerated.

In some instances, lymphocytes, plasma cells, macrophages, eosinophils, fibroblasts, and fibrous connective tissue was diffusely infiltrated between cardiac muscle.

As shown in Table 1 the myocardial concentration of Fe, Zn and Cu in sheep with sarcocystosis was significantly higher than unaffected ones ($P < 0.05$). In contrast, serum concentration of mentioned minerals was lower than unaffected sheep except for copper.

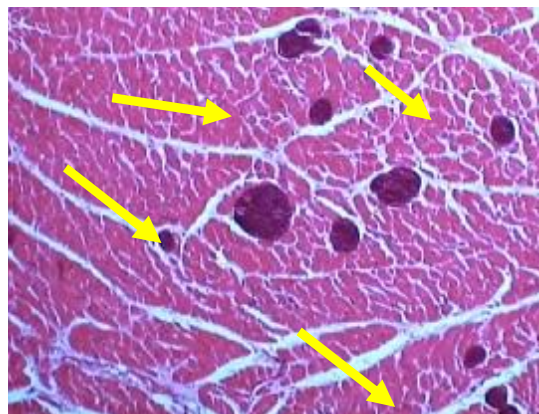


Fig. 1: Cross section of numerous sarcocysts (arrows) in cardiac muscle of sheep (Haematoxylin and Eosin stain. Magnification, $\times 40$)

Table 1: The comparison between serum and myocardium iron, copper and zinc concentration in unaffected and sheep with myocardial sarcocystosis

		Fe	Cu	Zn
Serum ($\mu\text{g}/\text{dl}$)	Unaffected group	214 \pm 11.9	95.3 \pm 2.75	144.83 \pm 3.12
	Sheep with sarcocystosis	188.4 \pm 5.7	114 \pm 7.3	139.5 \pm 24.4
Myocardium (mg/kg)	Unaffected group	4.56 \pm 0.2	2.61 \pm 0.09	2.86 \pm 0.1
	Sheep with sarcocystosis	5.77* \pm 0.41	4.18* \pm 0.13	3.4* \pm 0.27

* Significant to unaffected group ($P < 0.05$)

Discussion

Sarcocystis has been described as a possible cause of myocarditis when a cyst disintegrates and elicits a localized inflammatory reaction (15). In such hosts, these parasites are localized in the endothelia of blood vessels as schizonts and in striated muscles as cysts (7), which later was confirmed by the present study. Relatively little has been known about the immunity induced by infection with sarcocystis species; however, some studies referred to the protective immunity and cell-mediated mechanisms (16). The adaptation of a parasite to its host is under hormonal control (17). Some helminth species seem to regulate the host immune response through certain products which they secrete to their surroundings (18). Thus, the significance of steroid hormones originating from *Sarcocystis* spp. on the immune regulation of the host is another subject to be investigated. 3 β -Hydroxysteroid-dehydrogenase (3 β -HSD) was immuno-localised in sarcocysts, indicating that *Sarcocystis* spp. may produce steroids. As mentioned for some other parasite species, self-originating steroid hormones may have effects on the development of *Sarcocystis* spp., as well as on the immune interaction between these species and their hosts (7).

As regards to microscopic diagnosis, examined sheep showed high infection rate (18.62%) of myocardial *Sarcocystis*. Imai et al. stated that sarcocyst was detected in heart, tongue, esophagus and diaphragm of sheep with the incidence of 42.2, 26.9, 17.1 and 25 percent, respectively (19). Park et al. reported that the infection rate of cattle heart muscle to *Sarcocystis* were 43.6% (13). Sayed et al. described that the highest *Sarcocystis* infection rate in cattle was detected in ocular muscles (89%) followed by oesophageal muscles (84%), cardiac muscles (51%) and lastly diaphragmatic muscles (30%) (20).

Based on our study, the concentration of Fe, Cu and Zn in myocardial sarcocystosis were higher than unaffected sheep. Ozen et al. reported a decrease in Se and Zn and a rise in Cu in sera of patients with hydatid disease (21). The concentration of copper, zinc, cobalt and iron in sheep sera that affected by fertile hydatid cyst is higher than that sheep with infertile cyst and copper and zinc in liver of sheep with hydatidosis were lower and higher than the healthy sheep, respectively (22).

To this view, myocardial sarcocystosis may alter micro mineral status and raise their concentration in myocardium. As discussed

previously, micronutrients have an important role in immune functions, especially in cell-mediated immunity, which has a major role in killing virus, bacteria, protozoan infected cells and tumour cells. Trace elements such as Zn and Cu involved in antioxidant enzyme activity (zinc and/or copper superoxide dismutase) and protect membranes from potent oxidants such as free radicals (OH[·]), superoxide radicals (O₂⁻) and hydrogen peroxide (H₂O₂) (9). Sarcocystosis may evoke mentioned minerals to the myocardium for diminishing host immune response at first and for using them to protect itself against phagocytosis in the second. In addition, sarcocysts steroid production may introduce immunosuppression and alter the host defence more and more. It seems that the microelements such as Fe, Cu and Zn are needed for survival and persistency of sarcocyst.

Acknowledgements

Authors want to thank the School of Veterinary Medicine of Shahrekord University for financial support of this work. The authors declare that there is no conflict of interests.

References

1. Fayer R. *Sarcocystis* spp. in human infections. Clin Microbiol Rev. 2004; 17(4):894-902.
2. Heckerth AR, Tenter AM. Comparison of immunological and molecular methods for the diagnosis of infections with pathogenic *Sarcocystis* species in sheep. Tokai J Exp Clin Med. 1999; 23 (6): 293-302.
3. Daryani A, Alaei R, Dehghan MH, Arab R, Sharifi M, Ziaei H. Survey of sarcocystis infection in slaughtered sheep and bufaloes in Ardabil, Iran. J Anim Vet Adv. 2006; 5(1):60-62.
4. Landsverk T. An outbreak of sarcocystosis in a cattle herd [myocarditis, myositis, vascular lesions, Dalmeny disease. Acta Vet Scand. 1979; 20(2): 238-244.
5. Foreyt WJ, Baldwin TJ, Lagerquist JE. Experimental infections of *Sarcocystis* spp. in Rocky mountain elk (*Cervus Elaphus*) calves. J Wildlife Dis. 1995; 31(4): 462-466.
6. Fitzgerald SD, Janovitz EB, Kazacos KR, Dubey JP, Murphy DA. Sarcocystosis with involvement of the central nervous system in lambs. J Vet Diagn Invest. 1993; 5: 291-296.
7. Yarim M, Yildiz K, Kabakci N, Karahan S. Immunohistochemical localisation of 3b-hydroxysteroid dehydrogenase in *Sarcocystis* spp. Parasitol Res. 2004; 93: 457-460.
8. Radostits OM, Gay CC, Hinchcliff KW, Constable PD. Veterinary medicine, A text book of the diseases of cattle, sheep, pig, goat, and horse. 10th ed. Spain: Saunders, Elsevier; 2007.
9. Howard JL, Smith RA. Current veterinary therapy, food animal practice. 4th ed. Philadelphia: WB Saunders; 1999.
10. Kojouri GA, Shirazi A. Serum concentrations of Cu, Zn, Fe, Mo and Co in newborn lambs following systemic administration of vitamin E and selenium to the pregnant ewes. Small Ruminant Res. 2007; 70: 136-139.
11. Chandra RK, Dayton DH. Trace element regulation of immunity and infection. Nutr Res. 1982; 2 (6):721-733.
12. Kojouri GA, Ebrahimi A, Zaheri M. Zinc and selenium status in cows with dermatophytosis. Comp Clin Pathol. 2009; 18: 283-286.
13. Park YJ, Kim JS, Chung DS, Park YS, Sin MK, Kim KS. A survey of *Sarcocystis* infections in the slaughtered cattle and identification of *Sarcocystis cruzi*. Korea J Vet Serv. 1992; 15(2):109-120.

14. Huong T, Lam T. Prevalence of *Sarcocystis* spp. in water buffaloes in Vietnam. *J Vet Parasitol.* 1999; 86(1): 33-39.
15. Guamer J, Bhatnagar J, Shieh W, Nolte KB, Klein D, Gookin M, Pen˜aranda S, Oberste MS, Jones T, Smith C, Pallansch MA, Zaki SR. Histopathologic, immunohistochemical, and polymerase chain reaction assays in the study of cases with fatal sporadic myocarditis. *Hum Pathol.* 2007; 38: 1412– 1419.
16. Abdel-Baki AA, Allam G, Sakran T, El-Malah E. Lambs infected with UV-attenuated sporocysts of *Sarcocystis ovis* produced abnormal sarcocysts and induced protective immunity against a challenge infection. *Korea J Parasitol.* 2009; 7(2):131-138.
17. Spindler KD. Parasites and hormones. In: Mehlhorn H, editor. *Parasitology in focus.* Berlin Heidelberg New York: Springer; 1988. p. 465–473.
18. Spolski RJ, Corson J, Thomas PG, Kuhn RE. Parasite-secreted products regulate the host response to larval *Taenia crassiceps*. *Parasite Immunol.* 2000; 22: 297–305.
19. Imai Y, Inoue I, Yamada MN. *Sarcocystis tenella* from the sheep in Japan (Protozoa, Apicomplexa). *Jpn J Vet Res.* 1989; 51(4): 815-817.
20. Sayed FG, Shaheen MSI, Arafa MI, Koraa HM. Sarcocystis infection in cattle at Assiut abattoir: microscopical and serological studies. *Ass Univ Bull Environ Res.* 2008; 11(1): 47-58.
21. Ozen N, Celik C, Ozkan K, Malazgirt Z, Isimer A, Sayal A. Trace elements in hydatid disease. *J Trace Elem Elect H.* 1992; 6(2): 67-70.
22. Kojouri GA, Moshtaghi HA. Comparative study on copper, zinc, cobalt and iron concentration in hydatid cyst (fertile and infertile) fluid, liver and sheep serum. *Res J Parasitol.* 2008; 3(2): 67-70.