



Tehran University of Medical  
Sciences Publication  
<http://tums.ac.ir>

## Iran J Parasitol

Open access Journal at  
<http://ijpa.tums.ac.ir>



Iranian Society of Parasitology  
<http://isp.tums.ac.ir>

### Case Report

## Brain Hydatid Cyst with Atypical Symptoms in an Adult: A Case Report

Shahnam BABOLI <sup>1</sup>, Simin BABOLI <sup>2</sup>, \*Saeed SOLEIMAN MEIGOONI <sup>3</sup>

1. Neurosurgery Ward, Khanevadeh Military Academic Hospital, AJA University of Medical Sciences, Tehran, Iran
2. School of Medical Education Sciences, Shahid Beheshti University of Medical Sciences, Tehran, Iran
3. Infectious Diseases Research Center, AJA University of Medical Sciences, Tehran, Iran

Received 14 Dec 2015

Accepted 15 May 2016

#### **Keywords:**

Brain hydatid cyst,  
Surgical excision,  
Iran

#### **\*Correspondence Email:**

[dr.saeed.meigooni@gmail.com](mailto:dr.saeed.meigooni@gmail.com)

#### **Abstract**

Brain hydatid cyst constitutes one of the leading causes of cranial mass in the endemic region, especially among the children. Symptoms of the disease are associated with rising of intracranial pressure and focal neurological deficit. Surgical excision of the cyst is essential to treatment. Here we present a 19 yr-old male living in Ardabil, northwest of Iran, referred to Neurosurgery Clinic in Khanevadeh University Hospital, Tehran, Iran with a large brain hydatid cyst and atypical symptoms. He was treated by surgical excision of the cyst without any complication. There were not any clinical or radiological signs of recurrence after one-year follow-up.

### Introduction

Hydatidosis is an infectious parasitic disease due to *Echinococcus* species. Seroprevalence of hydatidosis is between 1.2 and 13.8% in the different region of Iran (1). Brain involvement occurs in 1-2% of patients with hydatidosis and comprises 2% of all brain masses in the endemic region, especially among the children (2). Symptoms of the brain hydatid cyst vary by location and size of the cyst. In a retrospective study of 117 children in Tunis, common symptoms were a headache, vomiting, hemiparesis, seizure,

mood alteration, and skull deformity (3). More than 50% of patients with the brain hydatid cyst have multiple cysts in the brain, and about 18% have visceral involvement, which has 9% mortality rate (4). Surgical treatment and excision of the cyst are the principal part of treatment. Ruptures of the cyst and anaphylactic reaction are the most frequent complication of the surgery with the prevalence of 10%.

Here we present an adult male with a large brain hydatidosis and atypical symptoms, who was treated successfully by surgery.

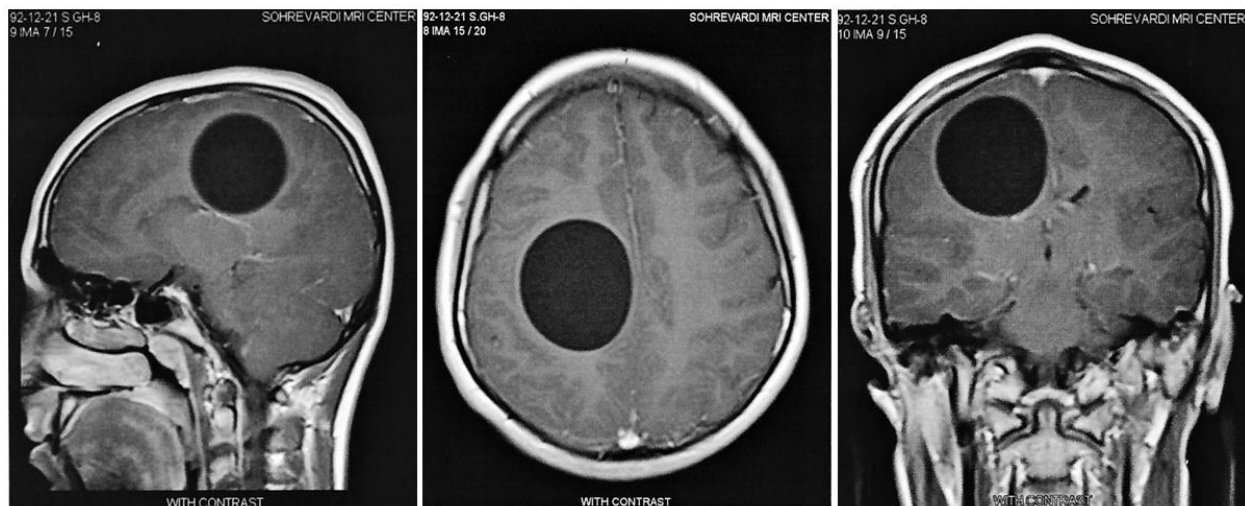
## Case report

A 19 yr-old male living in Ardabil, north-west of Iran, was referred to Neurosurgery Clinic in Khanevadeh University Hospital, Tehran, Iran for a headache and progressive left hemiparesis since a week ago. He was treated for depression and incuriosity for two months by a psychologist. During two weeks, he developed headache, vomiting, and in the last week, left-side paraparesis occurred. The patient reported no animal contact.

On admission, vital signs were normal. He was alert, with some retardation in answering.

Neurological examination revealed bilateral papilledema and end-point right-gaze nystagmus. Other cranial nerves were intact. Peripheral neurological examination showed left hemiparesis with the force of three to fifth in all muscle groups and normal deep tendon reflexes.

Brain contrast-enhancing magnetic resonance imaging (MRI) showed a large round mass about eight centimeters in the right frontoparietal lobe and mildly shifting the cerebral hemisphere to the left, without any ring-enhancement or surrounding edema (Fig. 1).



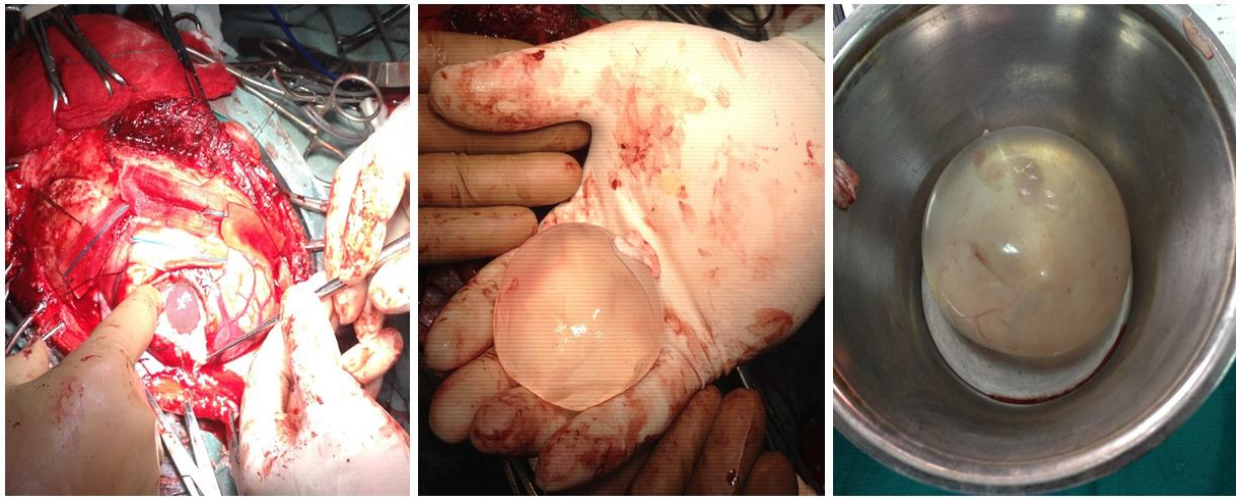**Fig.1:** Contrast-enhanced T1-weighted brain MRI shows a large brain hydatid cyst in the right frontoparietal lobe with mildly shifting of the cerebral hemisphere

Laboratory results showed mild anemia (Hemoglobin=13.1 milligrams per deciliter). Further laboratory and imaging findings were normal, except for antibody titer against *Echinococcus*, which raised fourfold above-normal range in IgG. Oral treatment with albendazole at a dose of 400 mg twice daily was initiated, and the patient underwent surgical excision of the cyst.

Right craniotomy through parietal bone with left side, head turning position was done under general anesthesia. A largely fluctuated

mass with adhesion to surrounding tissue appeared after dural opening, and 3% warm saline infused around the mass during 30 min, which led to slowing delivery of the mass in the next 40 min (Fig. 2).

Finally, free layers were sutured anatomically consequence, and the bone fixed by bone-adhesive glue. Oral treatment continued about three months. After one-yr follow-up, left hemiparesis improved, and the left side limbs forces raised to four-fifths. At this time brain MRI was normal.



**Fig. 2:** Surgical excision of the brain hydatid cyst via right craniotomy through parietal bone

## Discussion

Cystic hydatid disease (CHD) is an infectious parasitic disease, often caused by *E. granulosus*. This parasite distributes worldwide, and the main routes of transmission are ingestion of foods or water, which is contaminated by scolex or egg. Predominant age group is childhood, and the liver is the principally affected organ. 1-2% of the patients have cerebral involvement, especially in the parietal lobe (2). Brain hydatid cysts may grow up 1-10 cm a year and symptoms are often related to elevated intracranial pressure (ICP) and focal neurological deficit (5). In our patient, symptoms of rising ICP appeared in the advanced course of the disease and the main complaints, which resulted in seeking medication, were depressive mood alteration, personality instability, and apathy. Operative removal of the cyst is the principal part of treatment. Dowling technique is often used for surgical excision, which consists of craniotomy through a big opening hole, cortical dissection and hydrostatically delivery of the cyst using an injection of hypertonic saline (3), such as our patient.

Ruptures of the cyst and anaphylactic reactions are the most common complication of the surgery, but other complications such as

subdural effusion, hematoma, pneumocephalus or herniation must be considered (6). Emergent brain surgery was performed in a 13 yr-old male for cerebral herniation because of a massive brain hydatid cyst (5). Despite the significant size of the cyst and adhesion to surrounding tissue in our patient, he did not experience any complication. It seems that other related factors such as adhesion to surrounding tissue, the severity of intracranial pressure, access to the operative field, and expertise of the surgeon may influence the outcome.

We believe that the best surgical technique for excision of the cyst is adequate craniotomy, gentle decortication and enough time spending during the surgery.

## Acknowledgements

Financial support received from Infectious Diseases Research Center, AJA University Of Medical Sciences, Tehran, Iran. The authors declare that there is no conflict of interest.

## References

1. Rokni MB. Echinococcosis/hydatidosis in Iran. *Iran J Parasitol.* 2009; 4(2):1-6.

2. Umerani MS, Abbas A, Sharif S. Intracranial hydatid cyst: A case report of total cyst extirpation and review of surgical technique. *J Neurosci Rural Pract.* 2013;4(Suppl 1):S125.
3. Khaldi M, Mohamed S, Kallel J, Khouja N. Brain hydatidosis: report on 117 cases. *Childs Nerv Syst.* 2000;16(10-11):765-9.
4. Turgut M. Intracranial hydatidosis in Turkey: its clinical presentation, diagnostic studies, surgical management, and outcome. A review of 276 cases. *Neurosurg Rev.* 2001;24(4):200-8.
5. Duransoy YK, Mete M, Barutcuoglu M, Unsal UU, Selcuki M. Intracranial hydatid cyst is a rare cause of midbrain herniation: A case report and literature review. *J Pediatr Neurosci.* 2013;8(3):224-7.
6. Tuzun Y, Solmaz I, Sengul G, Izci Y. The complications of cerebral hydatid cyst surgery in children. *Childs Nerv Syst.* 2010;26(1):47-51.