



Original Study

Normal Color and Pulsed-Waved Doppler Ultrasonography of Femoral and Axillary Arteries in Dogs

Majid Masoudifard¹, DVSc

Assistant Professor of Veterinary Radiology

Alireza Vajhi¹, DVSc,

Assistant Professor of Veterinary Radiology

Ali Kavari², DVM

Mohammad Hadi Borhani Haghghi², DVM

¹Department of Clinical Sciences, Faculty of Veterinary Medicine, University of Tehran, Tehran-Iran.

²Private Veterinary Practitioner

Abstract

Objective- Obtaining the normal images of color doppler and estimation of blood flow velocity parameters of femoral and axillary arteries in dog.

Design- Descriptive study

Animals- 7 healthy adult mixed-breed dogs, weighing 14.3 ± 2.8 kg (mean \pm SD).

Proceudure- Left and right femoral and axillary arteries of hind and forelimbs were evaluated. Color and spectral doppler images of the each artery were obtained. Values of peak systolic velocity, end diastolic velocity, mean velocity, resistive index and pulsatility index were measured.

Statistical analysis- Calculation of mean and standard deviation of measured parameters using Microsoft Excel 2003.

Corresponding author:

Majid Masoudifard,

Department of Clinical Sciences, Faculty of Veterinary Medicine, University of Tehran, P.O.Box: 14155-6453, Tehran-Iran.

Telephone#: 0098 9122729351,

Fax#: 0098 21 66933222

E-mail: mmfard@ut.ac.ir

Results- Color Doppler of both arteries showed a laminar flow with higher velocity in the center of flow. High-resistance flow pattern with triphasic flow velocity and plug velocity profile were observed in spectral waveform analysis of pulsed Doppler.

Conclusion and Clinical Relevance- Results of this study can be useful for hemodynamic evaluation of femoral and axillary arteries diseases such as thromboembolism and arterial stenosis in dogs.

Key words- ultrasonography, color doppler, pulse doppler, femoral artery, axillary artery, dog.

Introduction

Ultrasonography has emerged in the last decade as a frequently used and important diagnostic tool in veterinary medicine.¹ Two characteristics of ultrasound that have made it popular are its safety, and lack of pain or discomfort for the patient. Ultrasonography is relatively inexpensive, noninvasive, and allows definition of structural anatomy and with the advent of Doppler imaging (color and pulse Doppler imaging), permits measurement of blood velocity parameters of the various vessels. Doppler ultrasound has become an accepted and routine method for the investigation of blood hemodynamic in both humans and animals since it can provide information in many vascular diseases.² One of the most common uses of Doppler ultrasound in humans is the estimation of blood velocity through the analysis of blood flow waveform. This sophisticated technique based on the Doppler principle, permits the estimation of blood velocity by detecting changes in the frequency of sound waves reflected back from flowing red blood cells. The greater the Doppler shift, the greater the velocity of the red blood cells in the blood vessel. The shift is less when the ultrasound beam is not parallel to the direction of blood flow within the blood vessel.³ It is essential to establish the normal velocity of arterial flow by Doppler ultrasonography to recognize the abnormal state in animals. Although a few studies have focused on measurement of blood velocity in dogs,^{4,5,6,7} but information on the normal Doppler flow velocity parameters of most of vessels in dogs is limited. This study was performed to assess Doppler imaging of the normal canine femoral and axillary vasculature. The location, spectral waveform morphology, and specific Doppler imaging blood velocity parameters of femoral and axillary arteries were determined.

Materials and Methods

Left and right femoral and axillary arteries of seven healthy dogs (Mean weight \pm SD: 14.3 \pm 2.8 kg) including 5 females and 2 males were evaluated using a Voluson 730 Pro ultrasound machine and multi-frequency (6-12 MHz) transducer. The dogs were housed in indoor cages with balanced diet and water *ad libitum*. All dogs were considered healthy following physical and clinical examination. The animals were placed in lateral recumbency. The medial skin surface of arm and thigh were clipped and prepared for sonographic examination. Default adjustments of the machine for the small parts and the resolution frequency were used for all cases. B-mode and color flow imaging were performed initially to identify vessels of interest (Fig. 1) for subsequent spectral Doppler analysis in transverse and sagittal views. Following description of the blood flow pattern in color Doppler, pulsed-wave Doppler scan was achieved in sagittal views. In pulse Doppler, the cursor was introduced toward the artery and sample volume size was selected 1 mm for both femoral and axillary arteries. The Doppler angle was below 60° in all scans. Doppler waveforms were recorded at a pulse repetition frequency (PRF) that was sufficient to prevent aliasing artifact. The spectral waveforms of each artery and mean blood flow parameters of 4-7 waveforms were measured using auto-trace and manual methods (Fig. 2). Efforts were made to obtain all values in an identical fashion. The following Doppler parameters were measured in proximal, mid and distal parts of left and right arteries and averaged: Peak-systolic Velocity (PSV), end-diastolic velocity (EDV), Mean Velocity (MnV), resistive index (RI), pulsatility index (PI) and spectral waveform morphology. The RI was determined by: $RI = (PSV-EDV)/PSV$. The PI was determined by $PI = (PSV-EDV)/MnV$.

Results

Mean and standard deviation of PSV, EDV, MnV, RI and PI as well as velocity profile and flow pattern of the femoral and axillary arteries are summarized in Table 1. The arteries could be imaged easily in the medial side of limb close to femoral and axillary veins. The color Doppler and waveform pattern of both femoral and axillary arteries were similar in many aspects. Color Doppler showed a laminar flow with higher velocity in the center of flow (Fig. 1). High-resistance flow pattern with triphasic flow velocity and plug velocity profile were observed in spectral waveform analysis of pulsed Doppler. A systolic peak was followed by a retrograde flow wave representing early diastolic velocity, then by a forward flow wave at a high-resistance flow pattern. The spectral waveform morphology of femoral and axillary arteries is demonstrated in Fig. 3A and B.

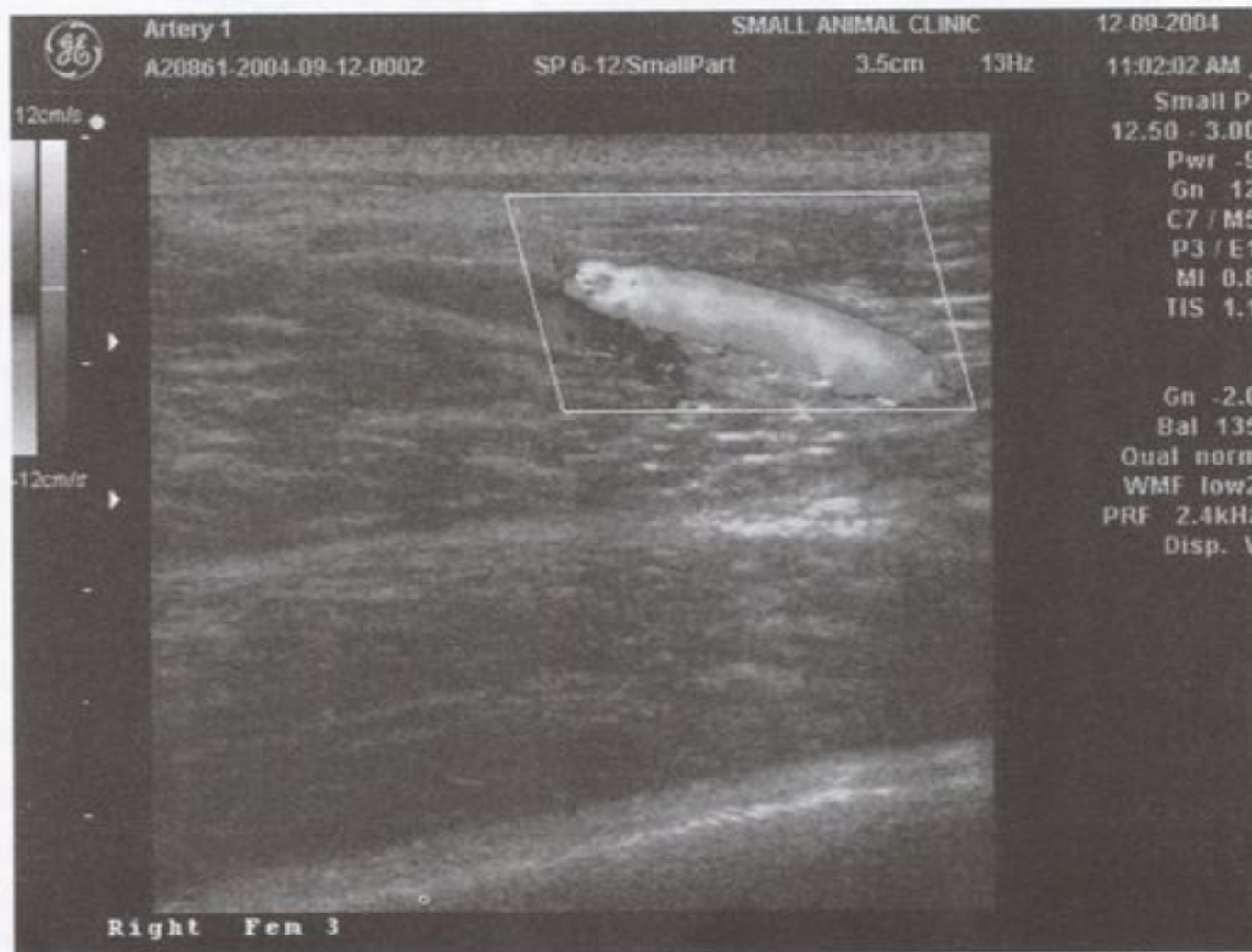

Figure 1. Color Doppler, B-mode image of femoral artery (sagittal view) demonstrates the artery with a red color while the center of the vessel shows brighter red to yellow color indicating of higher velocity due to laminar blood flow. The adjacent blue color indicates a reverse flow (a part of femoral vein). This sonogram was obtained transcutaneously at a displayed depth of 3.5 cm. The left side of the sonogram is proximal of the limb and the right side is distal.

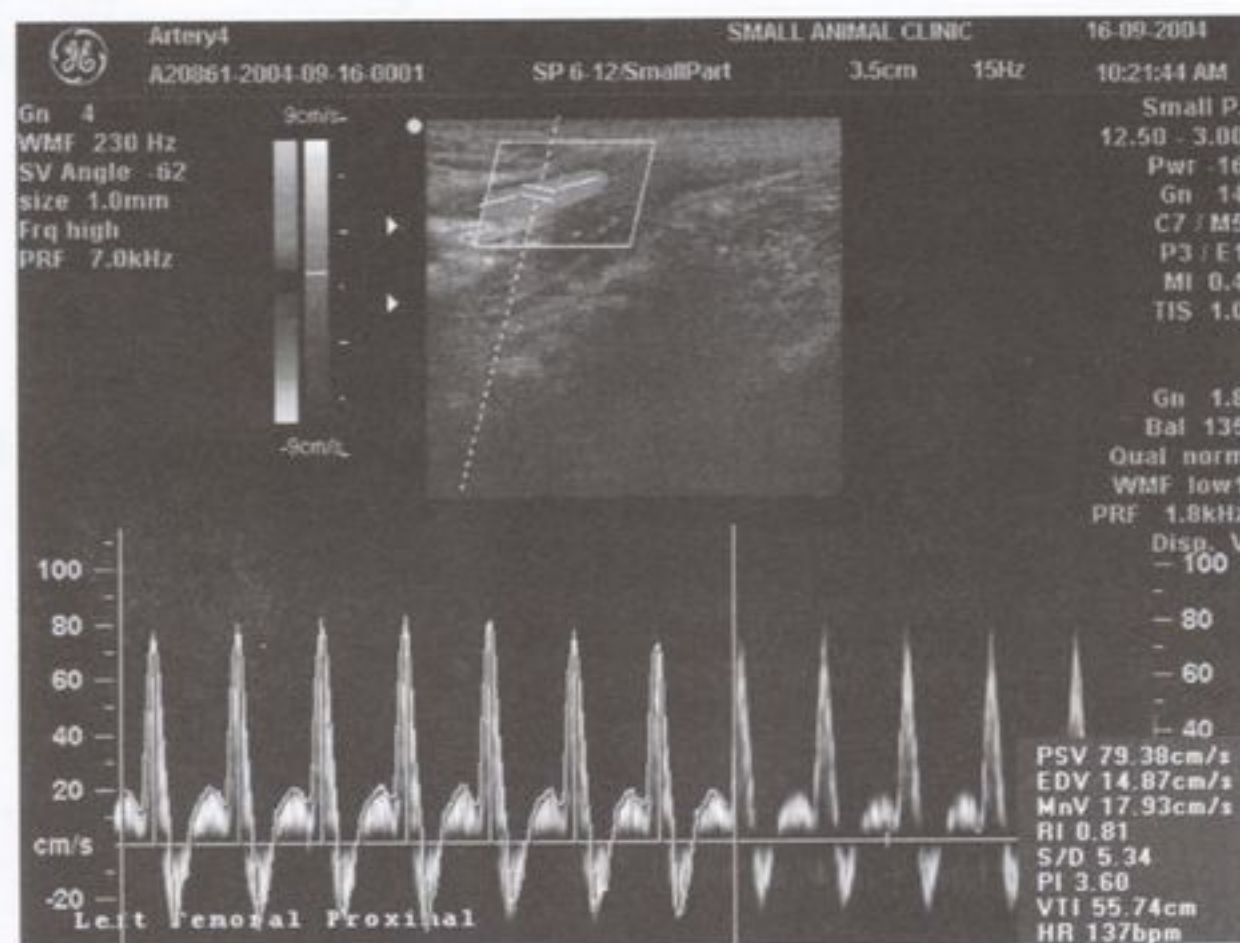


Figure 2. Triplex Doppler sonogram of the femoral artery (sagittal view) showing B-mode, color Doppler (above) and simultaneous spectral waveform of pulsed Doppler (bottom). The femoral and axillary arteries had a plug velocity profile and high-resistance flow pattern. Auto-trace of 7-waveform and calculation of the velocity parameters are seen in this sonogram.

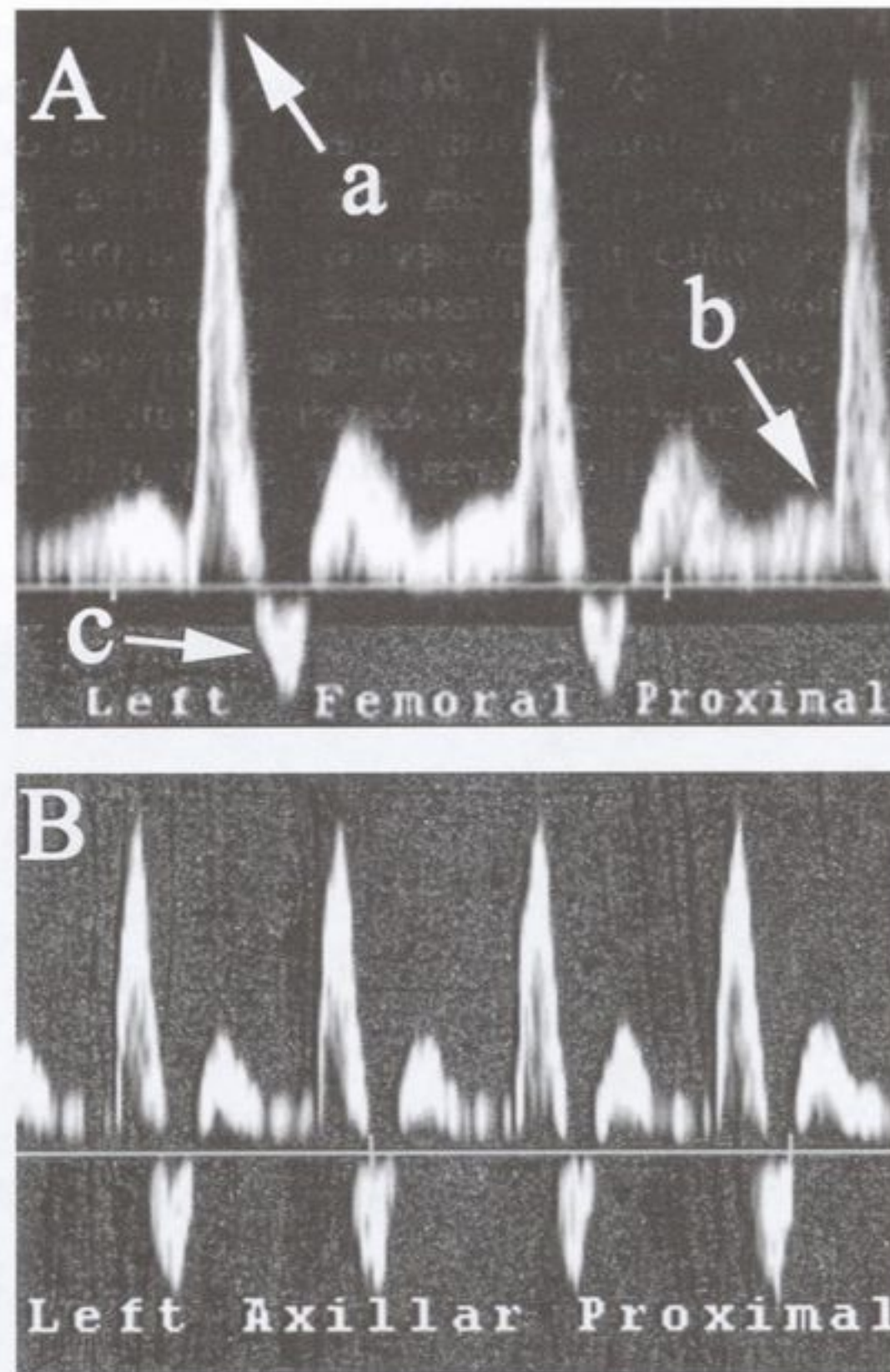


Figure 3. Pulse waveforms of the femoral artery (A) and axillary artery (B) in normal dogs of this study. Pulsatile triphasic waveforms are shown. (a) Peak systolic velocity, (b) End diastolic velocity, (c) Retrograde flow wave representing early diastolic velocity.

Table 1. Doppler imaging results of the femoral and axillary arteries in normal dogs

Artery	Mean	SD	Velocity profile	Resistance flow pattern
Femoral artery			Plug- triphasic	High
PSV	71.8441	28.4404		
EDV	8.7529	5.5209		
MnV	18.3436	3.8830		
RI	0.8455	0.0497		
PI	3.4191	1.0586		
Axillary artery			Plug- triphasic	High
PSV	78.3920	31.8751		
EDV	9.1687	3.1908		
MnV	20.7864	8.6656		
RI	0.8671	0.0515		
PI	3.4128	0.9597		

PSV = Peak-systolic Velocity (cm/s)
 EDV = End (or minimum) diastolic velocity (cm/s)
 MnV = Mean Velocity (cm/s)
 RI = Resistive index
 PI= Pulsatility inde

Discussion

Many peripheral vascular diseases identified in humans also occur in dogs and cats, although their clinical identification is frequently overlooked.⁸ Color and pulsed-wave Doppler ultrasonography has been adapted as one of the most important tools for evaluating the cardiovascular system of both animals and humans because of its noninvasiveness. Blood flow velocity is estimated with Doppler ultrasonography using the Doppler equation. The closest estimations of velocity can only be calculated when the Doppler angle is less than 60°. Although maintaining the Doppler angle below 60°, which is the accepted limitation for desirable measurement, was difficult in the femoral artery in this study, this problem was surmounted through the use of steer capability of the advanced machine which sends the waves in an angle not perpendicular to the skin surface and underlying parallel superficial vessels.

The velocity waveform derived from the Doppler frequency shift of an artery has a high PSV followed by a rapid drop in velocity to the low EDV. The RI is calculated to interpret the shape of the waveform. The RI varies from 0 to 100%, with 0 representing no resistance and 100 representing high resistance.¹⁰ High RI correlates to increased distal vascular resistance and decreased perfusion.¹¹ PSV, EDV, PI and RI values are the most frequently reported Doppler ultrasonography parameters for detecting arterial disease in humans and dogs. PSV, in particular, is the most reliable Doppler measurement parameter for estimating stenosis in humans. Internal carotid PSV was reported to be the single best Doppler parameter for distinguishing severe (greater than 80%) from less severe carotid stenosis in humans.¹² Meanwhile, the EDV more than 80 cm/s in the carotid artery determined by Doppler ultrasonography is an indication that severe stenosis should be considered.¹³

Changes in the waveform may have pathologic significance. Most of the arterial blood flow is laminar, with blood moving in thin concentric layers. Laminar flow velocity profiles comprise plug (narrow range of frequencies/velocities in larger arteries such as the aorta), parabolic (wide range of frequencies/velocities in smaller arteries such as renal artery), and blunted parabolic (intermediate range in middle sized arteries such as the celiac trunk).¹ In this study, femoral and axillary arteries had a plug velocity profile.

This report provides a database of Doppler imaging blood velocity parameters of the femoral and axillary arteries in healthy dogs.

Acknowledgement

The authors acknowledge the contributions and helps of Dr. Dariush Shirani, Dr. Reza Zare, Dr. Reza Sadeghi and Davod Faskhoodi for their kind assistances.

References

1. Nyland TG, Matton JS. *Small animal diagnostic ultrasound*. 2nd ed. Philadelphia: W.B. Saunders Co, 2002;1-18.
2. Spaulding KA. A review of sonographic identification of abdominal blood vessels and juxtavascular organs. *Vet Radiol Ultrasound* 1997; 38:4-23.
3. Greenfield DS, Heggerick PA, Hedges TR. Color Doppler imaging of normal orbital vasculature. *Ophthalmol* 1995; 102: 1598-1605.
4. Brown DJ, Knight DH, King RR. Use of pulsed-wave Doppler echocardiography to determine aortic and pulmonary velocity and flow variables in clinically normal dogs. *Am J Vet Res* 1991;52(4):S43-550
5. Finn-Bodner S, Hudson JA, Abdominal vascular sonography. In: Penninck DG, ed: *The Veterinary Clinics of North America. Small Animal Practice. Ultrasonography*. Philadelphia: WB Saunders Co, 1988, 28; 887-942.
6. Fukushima U, Sasaki S, Okano S, et al. The comparison between the cerebral blood flow directly measures and cerebral blood flow velocity in the middle and basilar cerebral arteries measured by transcranial Doppler ultrasonography. *J Vet Med Sci* 1999;61(12):1293-1297.
7. Szatmari V, Sotonyi P, Voros K. Normal duplex Doppler waveforms of major abdominal blood vessels in dogs: a review. *Vet Radiol Ultrasound* 2001;42(2): 93-107.
8. Fox PR, Petrie JP, Suter PF. Peripheral vascular disease. In: Ettinger SJ, Feldman EC, eds. *Textbook of Veterinary Internal Medicine*. 5th ed. Philadelphia, Pennsylvania: W.B. Saunders Co, 2000; 964-981.
9. Nelson TR, Pretorius DH.: The doppler signal: where does it come from and what does it mean? *Am J Roentgenol* 1988; 51:439-447.
10. Williamson TH, Harris A. Color Doppler ultrasound imaging of the eye and orbit. *Surv Ophthalmol* 1996; 40(4): 255-267.
11. Rankin SJA, Drance SM, Buckley AR, et al. Visual field correlations with color Doppler studies in open angle glaucoma. *J Glaucoma* 1996; 5: 15-21.
12. Schwartz SW, Chambless LE, Baker WH, et al. Consistency of Doppler parameters in predicting arteriographically confirmed carotid stenosis. Asymptomatic carotid atherosclerosis study investigators. *Stroke* 1997;28:343-347.
13. Beebe HG, Salles-Cunha SX, Scissons RP, et al. Carotid arterial ultrasound scan imaging: a direct approach to stenosis measurement. *J Vasc Surg* 1999;29(5) 838-844.

PSV	72.042	2.0000
EDV	87324	3.4200
MaxV	15.3415	3.2000
PI	0.8205	0.0000
RI	1.4912	1.0000
PSV	78.7020	3.1700
EDV	91007	3.1900
MaxV	20.7803	3.0000
PI	0.8277	0.0000
RI	3.4123	0.0000

PSV = Pulsed-wave Velocity (cm/s)
 EDV = End Diastolic Velocity (cm/s)
 MaxV = Max Velocity (cm/s)
 PI = Resistive Index
 RI = Pulsatility Index

اولتراسونوگرافی داپلر رنگی و پالسی سرخرگهای

رانی و آکسیلاری در سگهای سالم

دکتر مجید مسعودی فرد

استادیار بخش رادیولوژی، گروه علوم درمانگاهی دانشکده دامپزشکی دانشگاه تهران- ایران

دکتر علیرضا وجهی

استادیار بخش رادیولوژی، گروه علوم درمانگاهی دانشکده دامپزشکی دانشگاه تهران- ایران

دکتر علی کواری

دامپزشک بخش خصوصی

محمد هادی برهانی حقیقی

دامپزشک بخش خصوصی

هدف: ارزیابی تصاویر طبیعی داپلر رنگی و محاسبه پارامترهای مرتبط با داپلر پالسی در سرخرگ رانی و آکسیلاری سگهای سالم.

طرح: بررسی توصیفی

حیوانات: ۷ رأس سگ سالم نژاد مخلوط با میانگین وزنی و انحراف معیار ۲/۸ ۱۴/۳ کیلوگرم

روش: اولتراسونوگرافی داپلر رنگی و پالسی از سرخرگ رانی و آکسیلاری در قسمت میانی اندام حرکتی خلفی و قدامی راست و چپ انجام شد. پس از ارزیابی تصاویر داپلر رنگی، مقادیر حداکثر سرعت جریان خون در سیستول، سرعت جریان خون در انتهای دیاستول، متوسط سرعت جریان خون، اندیکس مقاومت عروقی و اندیکس قدرت پالسی سرخرگ با استفاده از منحنی طیفی داپلر پالسی اندازه گیری شدند.

تجزیه و تحلیل آماری:

محاسبه میانگین و انحراف معیار پارامترهای اندازه گیری شده با استفاده از نرم افزار Microsoft Excel 2003

نتایج: داپلر رنگی سرخرگهای رانی و آکسیلاری، جریان خون ضربان دار و لایه‌ای را به دلیل تفاوت رنگ قسمتهای کناری و وسطی رگ نشان میدادند به نحوی که در مرکز هر دو سرخرگ، رنگهای روشن‌تر که نشانه سرعت بیشتر جریان خون می‌باشد، جلب توجه مینمود. در داپلر پالسی هر دو سرخرگ، الگوی جریان طیفی با مقاومت بالا و جریان خون سه مرحله‌ای دیده میشد (جریان پلاگ).

نتیجه گیری: از نتایج این تحقیق میتوان به عنوان مقادیر استاندارد در ارزیابی وضعیت همودینامیک سرخرگهای رانی و آکسیلاری در عوارضی نظیر ترومبوآمبولی و استنوز سرخرگها در سگ استفاده نمود.

کلید واژه ها: اولتراسونوگرافی، داپلر رنگی، داپلر پالسی، سرخرگ رانی، سرخرگ آکسیلاری، سگ.