

Effect of Heparin in Prevention of Experimental Abdominal Adhesions in Rat

**Siavash Sharifi^{*1} DVSc
Amin Derakhshanfar² Ph.D
Mehrdad Pourjafar¹ DVSc
Ahmadreza Mohamadnia¹ DVSc
Khodakaram Charlang¹ DVM**

¹*Department of Clinical Sciences, Faculty of Veterinary Medicine,
University of Shahrekord, Shahrekord, Iran.*

²*Department of Pathobiology, Faculty of Veterinary Medicine,
Shahid Bahonar University of Kerman, Kerman, Iran.*

Abstract

Objective- Study on the effect of heparin in prevention of abdominal adhesions following abdominal surgery in rat.

Design- Experimental design.

Animals- Twenty male rats with average weight of 248 ± 5 gr.

Procedures- Animals were randomly divided into two equal groups of 10 rats (A and B). After induction of anesthesia, a midline abdominal incision was made and intestines were manipulated with a standard method, using a mini Johns Hopkins bulldog clamp. In group A (treatment) 100U/kg of heparin was administered into the peritoneal cavity and in group B (control) the same volume of saline was administered intraperitoneally. The abdominal incision was closed routinely. In group A 40 U/kg heparin and in group B the same volume of normal saline was injected subcutaneously BID. Seven days after surgery, all rats were sacrificed for necropsy. The number and the location of adhesions were evaluated and tissue samples were taken for histopathological examination.

Results- Macroscopic inspection revealed much more adhesions in group B compared with group A. In histopathological sections, the granulation tissue in treatment group was mainly "early" and the number of neutrophils and fibrin formation was less than the control group.

Conclusion and Clinical Relevance- Heparin treated rats showed less fibrinous adhesion in macroscopic studies and microscopic slides. Regarding to the results of current study, use of heparin can reduce peritoneal adhesion in peritonitis and can be used after major surgeries in rat.

Keywords: Abdominal adhesion, Heparin, Rat.

***Corresponding Author:**

Siavash Sharifi

Department of Clinical Sciences, Faculty of Veterinary Medicine, University of Shahrekord, Shahrekord, Iran.

E-mail: siavash.sharifi@yahoo.com

Introduction

Abdominal surgeries can result in intra-abdominal adhesions and death¹. Intraperitoneal adhesions between organs or organs and peritoneal wall occur in more than 90% of cases involving major abdominal operations. These adhesions cause narrowing of digestive tract, ileus, and female infertility, and constitute one of the major causes of postoperative morbidity^{2,3}. Inflammations caused by mechanical stimuli are the principal causes of intraperitoneal adhesions⁴. The mechanism of adhesion formation represents a variation in the physiological healing process. Adhesions seem to be a result of an inflammatory mechanism⁵. These adhesions are results of unwanted adhesions between fibrin bands that is obvious 24-48 hours after inflammation. Various experiments have been performed to prevent adhesions^{2,3}. New candidates for preventive therapeutics include polysaccharides and an inhibitor of collagen synthesis⁴.

Different methods have been suggested to prevent abdominal adhesions as lavage of abdominal cavity⁷, antibiotics⁸, lytic agents^{9, 10}, macrophage promoting factors¹¹, use of non-steroidal anti-inflammatory drugs and heparin as coagulation pathways blockers¹².

The aim of current study is the evaluation of simultaneous intra-peritoneal and subcutaneous heparin administration in prevention of adhesion formation following abdominal cavity manipulation in rat.

Materials and Methods

Twenty rats with average weight of 248 ± 5 grams were randomly divided into two equal groups and had similar access to water, food and was kept in the same housing condition. All mice anesthetized by intramuscular injection of ketamineⁱⁱⁱ (100 mg/kg) and xylazine^{iv} (4 mg/kg)¹⁴. After anesthesia and surgical preparation a midline abdominal incision was made and a 2cm segment of jejunum was exposed. A mini Johns Hopkins bulldog clamp was applied on the antimesenteric border of the exposed jejunum and maintained in place for 3 min. The same procedure was repeated in four more consecutive places, 5mm apart. In group A (Experiment), 100 units of heparin, and in group B (control) the same volume of normal saline was administered intraperitoneally. The abdominal incision was closed in two layers. In group A, 40 U/kg heparin and in group B the same volume of normal saline was injected subcutaneously twice daily. Seven days after surgery, all rats were sacrificed for necropsy. The number of adhesions in each animal was recorded and samples from abdominal wall and crushed sections of jejunum were sent for histopathological study in 10% buffered formalin.

Results

Macroscopic inspection revealed much more adhesion in group B in compare to group A (Fig 1 and 2). Histopathological findings include, voluminous fibrous exudates with heavy infiltration of neutrophils in group B. In addition, late granulation tissue characterized by thick collagen fibers, and mature fibrocytes was obvious, in this group. In group A, thin and separated bands of fibrin with a few neutrophils along with early granulation tissue composed of collagen fibers, fibroblasts and newly formed capillaries were seen (table 1 and fig. 3 to 6).

Table1: Histopathological parameters, evaluated in treatment and control groups.

Histopathological parameters	Granulation tissue*	Neutrophil	Fibrin formation
Treatment (group A)	Early	+	+
Control (group B)	Late	+++	+++

* Early granulation tissues composed of abundant fibroblasts, thin collagen fiber and newly formed capillaries while, late granulation tissue is composed of fibrocytes, thick collagen fibers and scattered capillaries.




Fig. 1: Mild abdominal adhesion in group A. Note to lesser amount of granulation tissue in comparison to fig 2.




Fig. 2: Severe abdominal adhesion in group B. Note to voluminous granulation tissue.

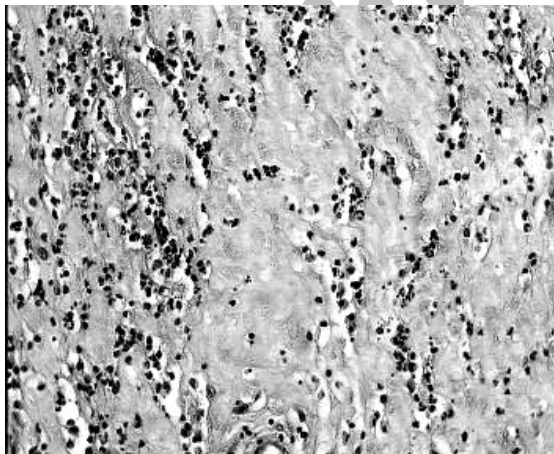


Fig. 3: Massive fibrinous exudates mixed with population of neutrophils. Group B. 400× – H&E

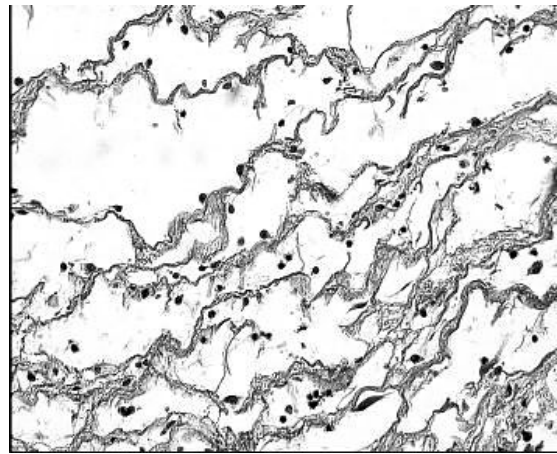


Fig. 4: Thin and separated bands of fibrin with scattered neutrophils. Group A. 400× – H&E

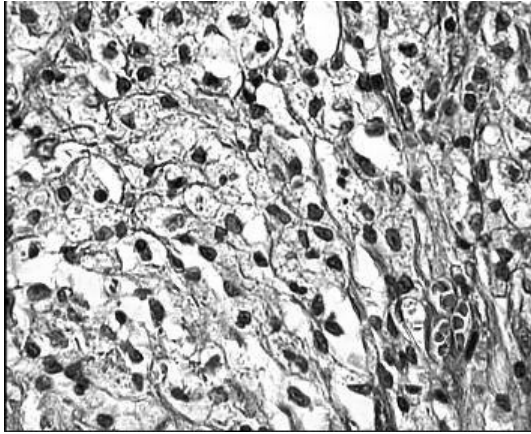


Fig. 5: Early granulation tissue characterized by thin collagen fibers, fibroblasts and newly formed capillaries. Group A 1000× , H&E

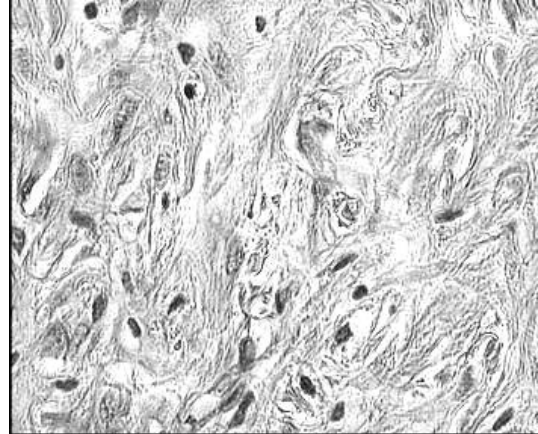


Fig. 6: Late granulation tissue characterized by thick collagen fibers, and fibrocystic. Group B. 1000×, H&E

Discussion

Intraperitoneal adhesion formation after major abdominal and gynecological surgery may result in long-term sequel, such as bowel obstruction, infertility and pain. To address this problem, investigators have attempted to reduce intraperitoneal adhesion formation using different approaches^{16,17,18}. 48 to 72 hours after start of healing and concurrent to termination of inflammation, regardless of fibrinolytic activities, these adhesions continue in different ways. With arriving of fibroblasts in fibrin network, irreversible adhesions will be formed⁶. If fibrinolytic activities could not remove fibrin from visceral or parietal peritoneum in 3 to 4 days then fibrin will be filled with collagen producing fibroblasts and fibrotic adhesions will begin. The most important reasons of adhesion formation are: tissue ischemia and prevention of fibrinolysis of the peritoneum as a result of over manipulation during surgery. Stimulation of angiogenesis in order to provide enough blood and oxygen and as a result, supplying enough fibrinogen which change to fibrin in ischemic area, dryness of peritoneum during surgery and separation of mesothelial cells that result in exposure of basement membrane and more fibrin leakage⁵. Recently, membranes, which are left in the peritoneal cavity and become absorbed, have been introduced as effective means to prevent intraperitoneal adhesions. However, only adhesions of organs separated by membranes can be prevented and other effective means to prevent intraperitoneal adhesions are urgently needed.

Although many multifactor processes are involved in the adhesion formation, one of these has been shown to be the inflammatory process. Surgical injury of the intact peritoneum produces serosanguineous exudates within 3hours Following an immediate inflammatory reaction, vascular permeability is increased and fibrin-rich exudates are released². If the fibrin is not completely lysed through the plasminogen–plasmin cascade, adhesions may form through collagen deposition on a framework of proteoglycan and fibronectin. Also higher percentage of abdominal adhesions in group B as a result of various degrees of fibrin precipitation after surgical manipulations on intestines and peritoneum is a normal result of peritoneal healing². This exudate includes various inflammatory cells such as neutrophils, and mononuclear cells. However, under normal conditions the peritoneal cavity contains mainly macrophages and

lymphocytes in a small amount of fluid. During the early period of injury (up to 3 days), the most pronounced elements in the healing of peritoneal lesions are PMN (Polymorphonuclear) and fibrin. The PMN cells, recruited in large numbers into the peritoneal cavity after the injury, play a role in the formation of peritoneal adhesions^{16,17,18}.

Intra-abdominal or systemic heparin aids in enhancing peritoneal fibrinolysis. Prokinetic therapy promotes early postoperative return of intestinal motility, minimizing the propensity for adhesion formation between apposing adynamic segments of intestine¹³.

Heparin is a mucopolysaccharide of d-glucosamin phosphate and d-glucuronic acid units with molecular weigh of 6000-20000. Heparin is mostly formed in liver and lung and in lesser contents in other tissues of the body. Heparin absorbs from IV and SC routes and joins to the serum proteins with half-life of 1-6 hours¹¹. Heparin prevents organizing of the fibrin during adhesion formation^{14,15}.

In current study effect of standard heparin in preventing of fibrin clotting in order to prevent abdominal adhesions after surgical abdominal manipulation of rats has been studied.

The heparin-bound patches caused significantly less inflammation than their nonheparinized counterparts. The heparinized porcine patches cross-linked with different compounds were found to have less fibrous formation than the nonheparinized patches and the synthetic patches. Heparinized substitutes may cause less adhesion and inflammatory reaction than nonheparinized material¹⁹.

Collagen principally forms the matrix of the developed adhesion. Neutrophils were claimed to have the potential to degrade the extracellular matrix⁶. Serine protease and metalloproteinases released from the neutrophils have been shown to play a role in neutrophil-mediated degradation of basement membrane collagen²⁰. In some studies, the release of free oxygen radicals and neutral protease from neutrophils has been claimed to cause collagen degradation²¹. Although collagen synthesis is known to reach significant amounts on the fifth day, controversial results have been reported²². Collagen solubilization by neutrophils was measured by hydroxyproline release^{23,24}. Native and synthetic collagen peptides were shown to stimulate free oxygen radical and elastase release as synthetic peptides containing hydroxyproline from neutrophils¹⁷. It can be stated that neutrophils cause adhesion formation but, at the same time, they start the degradation of collagen through the substances released by themselves. It has been reported that inhibition of neutrophil adherence and consequently neutrophil activation and migration into the peritoneum reduce neutrophil-dependent collagen degradation and result in increased adhesion formation¹⁷.

Decreases of inflammatory reactions and abdominal adhesions in group A in comparison to group B show the affectivity of heparin in decrease of adhesions after surgical manipulation. Role of heparin on decrease of abdominal adhesions were previously reported. Heparin accelerate depressing effects of anti-thrombin followed by inactivation of thrombin that finally result to suppressing changing of fibrinogen to fibrin^{14,25,26}. This process besides lesser fibrin formation lowers the amount of adhesions. Also heparin inhibits migration of inflammatory cells to injured tissue by blocking of contact loci of leucocyte-endothelium^{6,27,28}. These connections are the first stage of inflammatory cell migration to inflamed tissues and adhesion formation. It seems that 100 unit/ kg of heparin and its continuation via S/C prescription of 40 unit/kg is a reasonable doses in rat to prevent abdominal adhesions following surgery.

In other studies 100 unit/kg of heparin were reduced abdominal adhesions, intra-abdominal abscess and mortality significantly following induction of experimental peritonitis. Intra-peritoneal injection of heparin with lavage solutions of peritoneum were reported significant

in reduction of abdominal adhesions in rat¹⁶. Concurrent use of hyaluronic acid and heparin were reduced abdominal adhesions following experimental peritonitis of rats²⁹.

Deteriorative effects of the bacteria will increase by presence of peritoneal fluid, hemorrhage, fibrin, necrotic tissues and local anemia. Although fibrin formation can limit the bacterial action, however its excess could result in abscess formation and preventing phagocyte and antimicrobials to the source of infection and in this way the bacteria will physically protect against opsonins and antibiotics³⁰. Since the amount of produced fibrin correlated with infectious contamination that result in excessive inflammation, more fibrin result in more fibrotic adhesion and in contrast reduced inflammation 48-72 hours after start of inflammation will reduce risk of adhesion⁶. In this way antiinflammatory drugs can reduce adhesion by decreasing fibrin leakage and fibroblasts, that is the case in heparin as well with its ability in reduction of coagulation and decreasing entrance of inflammatory cells to the area⁶.

Regards to the results of current study, use of heparin can reduce peritoneal adhesions in peritonitis and can be used after major surgeries in rat.

References

1. Arikan S, Gokhan A, Barut G, et al. An evaluation of low molecular weight heparin and hyperbaric oxygen treatment in the prevention of intra-abdominal adhesions and wound healing. *Am J Surg* 2005;189:155-160.
2. Falk K, Holmdahl L, Halvarsson M, et al. Polymers that reduce intraperitoneal adhesion formation. *Br J Surg* 1998;85:1153-1156.
3. Rodgers KE, Girgis W, Amand K St, et al. Reduction of adhesion formation by intraperitoneal administration of various anti-inflammatory agents. *J Invest Surg* 1998;11:327-339.
4. Inoh K, Muramatsu H, Ochiai K, et al. Midkine, a heparin-binding cytokine, plays key roles in intraperitoneal adhesions. *Biochem Bioph Res Co* 2004;317:108-113
5. Drollette CM, Badaway SZ. Pathophysiology of pelvic adhesions. Modern trends in preventing fertility. *J Reprod Med* 1992;37:107-121.
6. Smith BP. *Large animal internal medicine*. 3rd ed. Philadelphia: Mosby 2000;860-861.
7. Wang XC, Gui CQ, Zheng QS. Combined therapy of allantoin, metronidazole, dexamethasone on the prevention of intra-abdominal adhesion in dogs and its quantitative analysis. *World J Gastroentero* 2003;15:568-571.
8. Hosseini SV. Use of colchicine in reduction or prevention of talk-induced intra abdominal adhesions bands. *IJMS* 2002;127:176-183.
9. Reijnen MMPJ, Bleichrodt RP, van Goor H. Pathophysiology of intra-abdominal adhesion and abscess formation, and the effect of hyaluronan. *Br J Surg* 2003;90:533-541.
10. Sousa AA, Petroianu A, Trapiello Neto V, et al. Effect of sodium carboxy methyl cellulose and methylprednisolone on the healing of jejunal anastomoses in rats. *Braz J Med Biol Res* 2001;34:519-523.
11. Rege NN, Nazareth HM, Isaac AA, et al. Immunotherapeutic modulation of intraperitoneal adhesions by *Asparagus racemosus*. *J Postgrad Med* 1989;35:199-203.
12. Gupta S, Jain PK. Low-dose heparin in experimental peritonitis. *Eur Surg Res* 1985;17:167-72.

13. Eggleston RB, Mueller PO. Prevention and treatment of gastrointestinal adhesions. *Vet Clin North Am Equine Pract* 2003;19:741-63.
14. Booth NH, Macdonald IE. *Veterinary pharmacology and therapeutics*. 6th ed. Ames: Iowa State Press, 1998;489-490.
15. Hull RD, Raskob GE, Hirsh J, et al. Continuous intravenous heparin compared with intermittent subcutaneous heparin in the initial treatment of proximal-vein thrombosis. *N Engl J Med* 1986;315:1109-1114.
16. Pados GA, Devroey P. Adhesions. *Curr Opin Obstet Gynecol* 1992;4:412-418.
17. Vural B, Cantürk NZ, Esen N, et al. The role of neutrophils in the formation of peritoneal adhesions. *Hum Reprod* 1999;14: 49-54
18. Raftery AT. Regeneration of parietal and visceral peritoneum in the immature animals: a light and electron microscopical study. *Br J Surg* 1973;60:969-975.
19. Chang Y, Sung HW, Chiu YT, et al. Heparinization on pericardial substitutes can reduce adhesion and pericardial inflammation in the dog. *J Thorac Cardiovasc Surg* 1998;115:1111-1120.
20. Vissers MC, Winterbourn CC. Gelatinase contributes to the degradation of glomerular basement membrane collagen by human neutrophils. *Collagen Rel Res* 1988;8:113-122
21. Hogstrom H, Haglund U. Neutropenia prevent decrease in strength of rat intestinal anastomosis: Partial effect of oxygen free radical scavengers and allopurinol. *Surgery* 1986;99:716-723.
22. Baykal A, Onat D, Rasa K, et al. Effects of polyglycolic acid and polypropylene meshes on postoperative adhesion formation in mice. *World J Surg* 1997;21:579-583.
23. Miligan DW, Raftery AT. Observations on the pathogenesis of peritoneal adhesions: a light and electron microscopical study. *Br J Surg* 1974;61:274-281
24. Palmgren MS, DeShazo RD, Carter RM. Mechanisms of neutrophil damage to human alveolar extracellular matrices: The role of serine and metalloproteases. *J Allergy Clin Immun* 1992;89:905-915.
25. Colman RW, Hirsh J, Marder VJ, et al. *Homeostasis and thrombosis: basic principles and clinical practice*. 3rd ed. Philadelphia: J.B. Lippincott, 1994;837-860.
26. Hirsh J, van Aken WG, Gallus AS, et al. Heparin kinetics in venous thrombosis and pulmonary embolism. *Circulation* 1976;53:691-695.
27. Nelson RM, Cecconi O, Roberts WG, et al. Heparin oligosaccharides bind L- and P-selection and inhibit acute inflammation. *Am Soc Hematol Educ Prog* 1993; 82:3253-3258.
28. Diamond MS, Alon R, Parkos CA, et al. Heparin is an adhesive ligand for the leukocyte integrin Mac-1 (CD11b/CD1). *J Cell Biol* 1995;130:1473-1482.
29. Babua M, Aygena E, Tayyara M, et al. Hyaluronic acid plus heparin for improved efficacy in prevention of adhesion formation in rat uterine horn model. *Eur J Obstet Gyn R B* 1998;78:109-112.
30. Schulman S, Hellgren-Wangdahl M. Pregnancy, heparin and osteoporosis. *Thromb Haemost* 2002;87:180-18.

مطالعه تجربی اثر هپارین در جلوگیری از چسبندگی شکمی در موش بزرگ

دکتر سیاوش شریفی^۱، دکتر امین درخشان فر^۲، دکتر مهرداد پورجعفر^۱،
دکتر احمد رضا محمد نیا^۱، دکتر خدا کرم چهار لنگ^۱

^۱گروه علوم درمانگاهی، دانشکده دامپزشکی دانشگاه شهرکرد، شهرکرد، ایران.
^۲گروه پاتوبیولوژی، دانشکده دامپزشکی، دانشگاه شهید با هنر کرمان، کرمان، ایران.

هدف: مطالعه بر روی اثرات هپارین استاندارد در پیش گیری از چسبندگی های شکمی بعد از جراحی محوطه شکمی در موش بزرگ
طرح: مطالعه توصیفی

حیوانات: ۲۰ سر موش نر بزرگ با وزن متوسط 248 ± 5 گرم

روش: حیوانات بطور اتفاقی به ۲ گروه مساوی A و B (۱۰ عدد موش در هر گروه) تقسیم شدند. در هر دو گروه بعد القاء بیهوشی، یک برش در خط میانی شکم، ایجاد شد و با استفاده از پنس بولداگ مینی جان هاپکینز در پنج نقطه از روده ها التهاب القاء گردید. در گروه A، 100 U/kg هپارین و در گروه B به همان حجم سرم فیزیولوژی، به داخل صفاق تجویز گردید و محل جراحی بخیه شد. سپس در هر ۱۲ ساعت به مدت سه روز هپارین با دوز 40 U/kg بصورت زیر پوست تزریق شد و گروه B نیز همان حجم سرم فیزیولوژی دریافت کرد. هفت روز پس از جراحی، موش ها به روش انسانی معدوم و تعداد نواحی چسبندگی مورد ارزیابی قرار گرفت و سپس نمونه های بافتی برای بررسی آزمایشات هیستوپاتولوژیک تهیه گردید.

نتایج: مطالعات ماکروسکوپی و میکروسکوپی دال بر کاهش میزان چسبندگی در گروه درمان بود.

نتیجه گیری: تجویز هپارین می تواند به عنوان درمان موثر در کاهش چسبندگی و واکنش های التهابی صفاق باشد.

کلید واژگان: چسبندگی های شکمی ، هپارین، موش بزرگ .